Appendix A. Search Strategies

Searches for Contextual Questions

PubMed

	Search Terms	Search Results
#1	hemangioma[mh] OR hemangioma, capillary infantile[nm] OR infantile hemangioma*[tiab] OR infantile haemangioma*[tiab] OR capillary hemangioma*[tiab] OR capillary haemangioma*[tiab] OR congenital hemangioma*[tiab] OR congenital haemangioma*[tiab] OR IH[tiab]	33,062
#2	infant[mh] OR infant[tiab] OR infants[tiab] OR infantile[tiab] OR child[mh] OR Children[tiab] OR youth[tiab] OR pediatric[tiab] OR neonat*[tiab]	2,235,431
#3	#1 AND #2	10,049
#4	#3 AND eng[la]	7,297
#5	#4 AND (review[pt] OR historical article[pt] OR practice guideline[pt] OR meta-analysis[pt])	897
#6	#5 AND Humans[mh]	892
#7	#6 AND (Therapeutics[mh] OR therapy[sh] OR Treatment Outcome[mh] OR therapy[tiab] OR therapies[tiab] OR therapeutic[tiab] OR therapeutics[tiab] OR outcome[tiab] OR outcomes[tiab] OR surgical[tiab] OR surgery[sh] OR surgery[tiab] OR Embolization, Therapeutic[mh] OR embolization[tiab] OR embolization[tiab] OR cryotherapy[mh] OR cryotherapy[tiab] OR Catheter Ablation[mh] OR radiofrequency ablation[tiab]OR Laser, dye [mh] OR Laser, Gas/therapeutic use[mh] OR Laser Therapy[mh] OR “carbon dioxide laser”[tiab] OR “carbon dioxide lasers”[tiab] OR CO2 laser[tiab] OR CO2 lasers[tiab] OR “fractionated laser”[tiab] OR “fractionated lasers”[tiab] OR argon[tiab] OR Lasers, Solid-State[mh] OR Neodymium YAG[tiab] OR YAG[tiab] OR Erbium[tiab] OR Propranolol[mh] OR propranolol[tiab] OR Timolol[mh] OR timolol[tiab] OR Imiquimod[NM] OR angiotensin OR Adrenergic beta-Antagonists[mh] OR Angiotensin-converting enzyme inhibitors[mh] OR Immunosuppressive agents[mh] OR Angiogenesis Inhibitors[mh] OR Bleomycin[mh] OR bleomycin[tiab] OR Antineoplastic agents[mh] OR Vincristine[mh] OR vincristine[tiab] OR corticosteroids[tiab] OR beta-blockers[tiab] OR beta blockers[tiab] OR beta blocker[tiab] OR beta-blockers[tiab] OR angiotensin[tiab] OR intralesional interferon[tiab])	630

Key: [mh] medical subject heading; [nm] supplementary concept; [tiab] keyword in title or abstract; [la] language; [pt] publication type; [sh] subheading

CINAHL search strategies (EBSCO Host interface)

	Search Terms	Search Results
#1	(MH “Hemangioma”) OR (MH “Hemangioma, Cavernous”) OR “infantile hemangioma” OR “infantile hemangiomas” OR “infantile haemangiomas” OR “infantile haemangiomas” OR “IH”	1,164
#2	(MH “ Infant, Newborn, Diseases”) OR (MH “Infant”) OR (MH “Infant, Newborn”) OR (MH “Child”) OR “infant” OR “infants” OR “infantile” OR “newborn” OR “child” OR “children” OR “pediatric” or “neonat*”	377,138
#3	S1 AND S2	452
#4	S3 AND limiters: English language	449
#5	S4 AND limiters: Exclude MEDLINE records	90

Key: MH CINAHL medical subject heading; MW CINAHL subheading

EMBASE search strategies (OvidSP interface)

	Search Terms	Search Results
#1	Capillary hemangioma / or infantile hemangioma.tw. or infantile hemangiomas.tw. or infantile haemangioma.tw. or infantile haemangiomas.tw. or haemangioma.tw. or hemangiomas.tw. or IH.tw.	15,518
#2	Infant/ or child/ or newborn/ or congenital disorder/ or infant*.tw. or infantile.tw. or child.tw. or children.tw. or newborn.tw. or newborns.tw.	2,257,155
#3	1 AND 2	4658
#4	Limit 3 to English	3782
#5	Limit 4 to human	3392
#6	5 not (editorial.pt. or letter.pt. or note.pt. or short survey.pt. or conference paper.pt.)	3155
#7	Limit 6 to exclude MEDLINE journals	236

Key: / Emtree heading; .tw. abstract, title and drug trade name; /cn congenital; .fs. subheading; si.fs. side effects subheading; th.fs. therapy subheading; su.fs. surgery subheading; co.fs. complications subheading; pt. publication type

Searches for Comparative Effectiveness Questions

PubMed

	Search Terms	Search Results
#1	hemangioma[mh] OR hemangioma, capillary infantile[nm] OR infantile hemangioma*[tiab] OR infantile haemangioma*[tiab] OR capillary hemangioma*[tiab] OR capillary haemangioma*[tiab] OR congenital hemangioma*[tiab] OR congenital haemangioma*[tiab] OR IH[tiab]	33,062
#2	infant[mh] OR infant[tiab] OR infants[tiab] OR infantile[tiab] OR pediatric[tiab] OR neonat*[tiab] OR child[mh] OR children[tiab] OR youth[tiab]	2,335,431
#3	Therapeutics[mh] OR therapy[sh] OR Treatment Outcome[mh] OR therapy[tiab] OR therapies[tiab] OR therapeutic[tiab] OR therapeutics[tiab] OR outcome[tiab] OR outcomes[tiab] OR surgical[tiab] OR surgery[sh] OR surgery[tiab] OR Embolization, Therapeutic[mh] OR embolization[tiab] OR embolization[tiab] OR cryotherapy[mh] OR cryotherapy[tiab] OR Catheter Ablation[mh] OR radiofrequency ablation[tiab]OR Laser, dye [mh] OR Laser, Gas/therapeutic use[mh] OR Laser Therapy[mh] OR “carbon dioxide laser”[tiab] OR “carbon dioxide lasers”[tiab] OR CO2 laser[tiab] OR CO2 lasers[tiab] OR “fractionated laser”[tiab] OR “fractionated lasers”[tiab] OR argon[tiab] OR Lasers, Solid-State[mh] OR Neodymium YAG[tiab] OR YAG[tiab] OR Erbium[tiab] OR Propranolol[mh] OR propranolol[tiab] OR Timolol[mh] OR timolol[tiab] OR Imiquimod[NM] OR Adrenergic beta-Antagonists[mh] OR Angiotensin-converting enzyme inhibitors[mh] OR Immunosuppressive agents[mh] OR Angiogenesis Inhibitors[mh] OR Bleomycin[mh] OR bleomycin[tiab] OR Antineoplastic agents[mh] OR Vincristine[mh] OR vincristine[tiab] OR corticosteroids[tiab] OR beta-blockers[tiab] OR beta blockers[tiab] OR beta blocker[tiab] OR beta-blockers[tiab] OR angiotensin[tiab] OR intralesional interferon[tiab] OR “adverse effects"[Subheading] OR unsafe[tiab] OR safety[tiab] OR harm[tiab] OR harms[tiab] OR harmful[tiab] OR complication[tiab] OR complications[tiab] OR side-effect[tiab] OR "side-effects"[tiab] OR Undesirable effect[tiab] OR undesirable effects[tiab] OR undesirable reaction[tiab] OR undesirable reactions[tiab] OR undesirable event[tiab] OR undesirable events[tiab] OR undesirable outcome[tiab] OR undesirable outcomes[tiab] OR adverse effect[tiab] OR adverse effects[tiab] OR adverse reaction[tiab] OR adverse reactions[tiab] OR adverse event[tiab] OR adverse events[tiab] OR adverse outcome[tiab] OR adverse outcomes[tiab] OR "Postoperative Complications"[Mesh] OR postoperative complication[tiab] OR postoperative complications[tiab] OR post operative complication[tiab] OR post operative complications[tiab] OR surgical complication[tiab] OR surgical complications[tiab] OR postsurgical complication[tiab] OR postsurgical complications[tiab] OR post surgical complication[tiab] OR post surgical complications[tiab] OR adverse effects[Subheading] OR complications[Subheading] OR contraindications[Subheading] OR bleeding[tiab] OR Hemorrhage[mh] OR scarring[tiab] OR scars[tiab] OR residual hemangiomas[tiab] OR residual hemangioma[tiab] OR residual haemangioma[tiab] OR residual haemangiomas[tiab] OR pain[mh] OR pain[tiab] OR “Skin atrophy”[tiab] OR venous prominence[tiab] OR facial injuries[mh] OR skin ulcer[mh] OR ulceration[tiab] OR “surgical wound infection”[mh] OR wound infection[mh] OR infection[tiab]	10,334,120
#4	#1 AND #2 AND #3	7392
#5	#4 AND eng[la]	5441
#6	#5 AND Humans[mh]	5203
#7	#6 AND ("1982/01/01"[Date - Publication] : "3000"[Date - Publication])	4358
#8	#7 NOT (editorial[pt] OR letter[pt] OR comment[pt] OR review[pt] OR news[pt] OR historical article[pt] OR practice guideline[pt] OR meta-analysis[pt])	3409

Key: [mh] medical subject heading; [nm] supplementary concept; [tiab] keyword in title or abstract; [la] language; [pt] publication type; [sh] subheading

CINAHL search strategies (EBSCO Host interface)

	Search Terms	Search Results
#1	(MH “Hemangioma”) OR (MH “Hemangioma, Cavernous”) OR “infantile hemangioma” OR “infantile hemangiomas” OR “infantile haemangiomas” OR “infantile haemangiomas” OR “IH”	1,163
#2	(MH “ Infant, Newborn, Diseases”) OR (MH “Infant”) OR (MH “Infant, Newborn”) OR “infant” OR “infants” OR “infantile” OR “newborn” OR “pediatric” OR “neonat*” OR (MH “Child”) OR “child” OR “children”	376,639
#3	S1 AND S2	452
#4	S3 AND limiters: English language	449
#5	S4 AND limiters: 1982-	448
#6	S5 AND limiters: Exclude MEDLINE records	90

Key: MH CINAHL medical subject heading; MW CINAHL subheading

EMBASE search strategies (OvidSP interface)

	Search Terms	Search Results
#1	Capillary hemangioma / or infantile hemangioma.tw. or infantile hemangiomas.tw. or infantile haemangioma.tw. or infantile haemangiomas.tw. or haemangioma.tw. or hemangiomas.tw. or IH.tw.	15,410
#2	Infant/ or child/ or newborn/ or congenital disorder/ or infant*.tw. or infantile.tw. or child.tw. or children.tw. or newborn.tw. or newborns.tw. or neonat*.tw	2,316,140
#3	1 AND 2	4,615
#4	Limit 3 to English	3,756
#5	Limit 4 to human	3,343
#6	5 not (review.pt. or editorial.pt. or letter.pt. or note.pt. or short survey.pt. or conference paper.pt. or meta analysis/ or practice guideline/ or systematic review/)	2,699
#7	Limit 6 to 1982-	2645
#8	Limit 7 to exclude MEDLINE journals	207

Key: / Emtree heading; .tw. abstract, title and drug trade name; /cn congenital; .fs. subheading; si.fs. side effects subheading; th.fs. therapy subheading; su.fs. surgery subheading; co.fs. complications subheading; pt. publication type

Appendix B. Screening and Quality Assessment Forms

Infantile Hemangioma Abstract Review Form

1. Does this reference include an abstract?
□ Yes □ No □ Cannot Determine

2. Does this study include newborns, infants or children (ages 0-18) with diagnosis of infantile hemangioma (or suspected hemangioma)?
(Do not include hemangioblastomas, hemangioendothelioma, cavernous hemangiomas/lesions/malformation, non-involuting congenital hemangiomas (NICH), rapid involuting congenital hemangiomas (RICH), vascular malformations, choroidal hemangiomas, diffuse hemangiomatosis, angiomas, verrucous hemangiomas)
□ Yes □ No □ Cannot Determine

3. Is this study original research (e.g., not commentaries, literature reviews, or systematic reviews, letters to the editor, editorials, case reports)?
□ Yes □ No □ Cannot Determine

4. Does this study address the effectiveness or harms of a diagnostic modality or surgical, laser or pharmacological intervention for infantile hemangioma?
□ Yes □ No □ Cannot Determine
Diagnostic modality/workup evaluation *Including but not limited to*:
Diagnostic imaging including MRI, CT, MRA, Echo, Ultrasound
Surgical interventions *Including but not limited to*: cryotherapy, resection, embolization, radiofrequency ablation therapy, incisional biopsy
Laser treatment *Including but not limited to*:
Pulsed dye, fractionated, argon, carbon dioxide, neodymium (Nd): YAG, Erbium lasers
Pharmacologic interventions *Including but not limited to*:
Beta-blockers (e.g., systemic propranolol, topical timolol); corticosteroids (topical, intralesional, systemic); sirolimus, imiquimod, interferon, bleomycin, vincristine, ACE inhibitors, antiangiogenic agents

5. Does this article address contextual questions including natural history, adverse outcomes of untreated infantile hemangioma, characteristics of the hemangioma that indicate risk of significant medical complications that would prompt immediate medical or surgical intervention, or evidence for the association of multiple cutaneous hemangiomas and increased risk of occult hemangiomas?
□ Yes □ No □ Cannot Determine

Retain for:
□ Background/Discussion □ Review of References □ Other: _____
Comments:

Infantile Hemangioma Full Text Review Form

1. Eligible study design:
□ RCT
□ Cohort study with comparison group
□ Case-control
□ Case series reporting harms and including at least 25 children with IH
□ Case series with <25 children with IH
□ None of the above

2. N participants:
_____

3. Study informs a key question:
□ KQ1: Benefits/harms of imaging
□ KQ2: Benefits/harms of corticosteroids/beta-blockers
□ KQ3: Benefits/harms of second-line therapies after corticosteroids/beta-blockers
□ KQ4: Benefits/harms of surgery/laser
□ Other: Benefits/harms of second-line after no or other drugs
□ Does not address a KQ

4. Please list intervention:
_____

5. Does this study include baseline and follow-up data for an outcome of interest?
□ Yes, baseline and follow-up
□ No, follow-up/final data only

6. Retain for:
□ Background/Discussion □ Review of references □ Contextual questions

7. Comments:

Harms Risk of Bias Assessment Form

RefID: _____ Reviewer:_____

Question	Yes	No	Unclear	Comments
1. Are any important harms or adverse events that may be a consequence of the intervention/exposure missing from the results? (RTI cohort)				
2. Were the harms predefined using standardized or precise definitions? (mcharms) *Pre-defined indicates that the harms that were expected are explicitly defined prior to the collection of these expected events. For example, if bleeding is listed as a harmful event, the criteria by which they determine the bleeding (i.e. body location, type, or amount of blood loss that counts as an event, etc) should be specified. Standardized classification of harms can be derived from any of the following:* *1) reference to standard terminology or classifications of harms from a recognized external organization(s)(such as government regulatory or health agencies. Examples of standardized terminology for harms includes, WHO-ART, MEDra, HTA report on the Measurement and Monitoring of Surgical Adverse Events)* *2) previously explicitly defined classifications of harms in the literature, or* *3) based on pre-specified clinical criteria, or* 4) *pre-specified laboratory test (may not need to have a specific cut-off level specified in all cases)* *In some instances only some of the harms identified in a study will be precisely defined. In this case, there must be some judgement if the nature of the harms not pre-defined.*				
3. Are all pre-specified harms reported? (RTI case series)				IF #2 is NO, this is unclear
4. Did the author(s) use STANDARD scale(s) or checklist(s) for harms collection? (mcharms) ***Standard*** *scales or checklists are those that have at least one of the following:* *-Established reliability and validity (specified in the text);* *-Are very widely used within the*				

discipline (may have to check the reference list for the scale) *In the instance where the methods indicate that a **NEW** scale or checklist was developed for the study specifically, the author(s) must explicitly specify the CONTENT of the new scale or checklist in sufficient detail (for example, the body systems evaluated, or the specific tests or questions included.)*				
5. Are the statistical methods used to assess the main harm or adverse event outcomes adequate? (RTI cohort)				

Note: This form derived from questions from the RTI Item bank and McHarms tool.
Good= 4-5 “yes”; Fair=3 “yes” out of 5; Poor=2 “yes” or less

QUADAS Diagnostic Accuracy Rating Tool – For Diagnosis studies Form

		Yes	No	Unclear	Comments
1	Was the spectrum of patients representative of the patients who will receive the test in practice?				
2	Were selection criteria clearly described?				
3	Is the reference standard likely to correctly classify the target condition?				
4	Is the time period between reference standard and index test short enough to be reasonably sure that the target condition did not change between the two tests?				
5	Did the whole sample or a random selection of the sample, receive verification using a reference standard of diagnosis?				
6	Did patients receive the same reference standard regardless of the index test result?				
7	Was the reference standard independent of the index test (i.e. the index test did not form part of the reference standard)?				
8	Was the execution of the index test described in sufficient detail to permit replication of the test?				
9	Was the execution of the reference standard described in sufficient detail to permit its replication?				
10	Were the index test results interpreted without knowledge of the results of the reference standard?				
11	Were the reference standard results interpreted without knowledge of the results of the index test?				
12	Were the same clinical data available when test results were interpreted as would be available when the test is used in practice?				
13	Were uninterpretable/ intermediate test results reported?				
14	Were withdrawals from the study explained?				

Newcastle-Ottawa Quality Assessment Form for Cohort Studies Form

Note: A study can be given a maximum of one star for each numbered item within the Selection and Outcome categories. A maximum of two stars can be given for Comparability.

REFID:_____ **Reviewer:_____**

Selection

1) Representativeness of the exposed cohort:

   a) Truly representative ***(one star)***
   b) Somewhat representative ***(one star)***
   c) Selected group
   d) No description of the derivation of the cohort

2) Selection of the non-exposed cohort

   a) Drawn from the same community as the exposed cohort ***(one star)***
   b) Drawn from a different source
   c) No description of the derivation of the non exposed cohort

3) Ascertainment of exposure:

   a) Secure record (e.g., surgical record) ***(one star)***
   b) Structured interview ***(one star)***
   c) Written self report
   d) No description
   e) Other

4) Demonstration that outcome of interest was not present at start of study:

   a) Yes ***(one star)***
   b) No

Comparability

5) Comparability of cohorts on the basis of the design or analysis controlled for confounders:

   a) The study controls for age ***(one star)***
   b) Study controls for other factors (list) _____***(one star)***
   c) Cohorts are not comparable on the basis of the design or analysis controlled for confounders

Outcome

6) Assessment of outcome:

   a) Independent blind assessment ***(one star)***
   b) Record linkage ***(one star)***
   c) Self report
   d) No description
   e) Other

7) Was follow-up long enough for outcomes to occur:

   a) Yes ***(one star)***
   b) No

   Indicate the median duration of follow-up and a brief rationale for the assessment above:_____

8) Adequacy of follow-up of cohorts:

   a) Complete follow up- all subject accounted for ***(one star)***
   b) Subjects lost to follow up unlikely to introduce bias- number lost less than or equal to 20% or description of those lost suggested no different from those followed. ***(one star)***
   c) Follow up rate greater than 80% and no description of those lost
   d) No statement

9) Would answers to any of these questions vary based on the specific outcome assessed? If yes, please explain:

_____

_____

Infantile Hemangioma CER: Risk of Bias for RCTs Form

Reviewer Initials: _____ Ref ID: _____

Risk of Bias	Criterion	Yes	No	Unclear	COMMENTS
Selection bias	Was the allocation sequence generated adequately (e.g., random number table, computer-generated randomization)?				
	Was the allocation of treatment adequately concealed (e.g., pharmacy-controlled randomization or use of sequentially numbered sealed envelopes)?				
	Were participants analyzed within the groups they were originally assigned to?				
	Does the design or analysis control account for important confounding and modifying variables through matching, stratification, multivariable analysis, or other approaches?				
Performa nce bias	Did researchers rule out any impact from a concurrent intervention or an unintended exposure that might bias results?				
	Did the study maintain fidelity to the intervention protocol?				
Attrition bias	If attrition (overall or differential nonresponse, dropout, loss to follow-up, or exclusion of participants) was a concern, were missing data handled appropriately (e.g., intention-to-treat analysis and imputation)?				
Detection bias	Was the length of follow-up different between the groups?				
	Were the outcome assessors blinded to the intervention or exposure status of participants?				
	Were interventions/exposures assessed/defined using clearly defined measures, implemented consistently across all study participants?				
	Were outcomes assessed using clearly defined measures, implemented consistently across all study participants?				
Reporting bias	Were the potential outcomes prespecified by the researchers?				
	Are all prespecified outcomes reported?				
Other	List outcomes of interest assessed: _____ Would answers to any of these questions vary by the specific outcome assessed? If yes, please explain in Comments box.				

OUTCOMES OF INTEREST FOR REVIEW

Imaging: Ability to identify presence, number, and extent of hemangiomas and associated structural anomalies (sensitivity and specificity)

Treatment: Size / volume of hemangioma; Impact on vision**;** Aesthetic appearance as assessed by clinician or parent**;** Degree of ulceration**;** Quality of life

Appendix C. Excluded Studies

Reasons for Exclusion

X-1 Does not include children with infantile hemangioma
X-2 Not original research
X-3 Does not address interventions/outcomes of interest
X-4 Ineligible study design
X-5 Not obtainable
X-6 Not in English

1. Argenta LC, Bishop E, Cho KJ, et al. Complete resolution of life-threatening hemangioma by embolization and corticosteroids. Plast Reconstr Surg. 1982 Dec;70(6):739-44. PMID: 6890694; X-1, X-2
2. Bardelli AM, Lasorella G. Primary and secondary ocular tumors in children. J Neurosurg Sci. 1982 Jan-Mar;26(1):11-6. PMID: 6815311; X-1
3. Biller HF, Krespi YP, Som PM. Combined therapy for vascular lesions of the head and neck with intra-arterial embolization and surgical excision. Otolaryngol Head Neck Surg. 1982 Jan-Feb;90(1):37-47. PMID: 6806755; X-1, X-2
4. Bloom DA, Scardino PT, Ehrlich RM, et al. The significance of lymph nodal involvement in renal angiomyolipoma. J Urol. 1982 Dec;128(6):1292-5. PMID: 7154190; X-1
5. Bookstein JJ, Cho KJ, Davis GB, et al. Arterioportal communications: observations and hypotheses concerning transsinusoidal and transvasal types. Radiology. 1982 Mar;142(3):581-90. PMID: 7063671; X-1
6. Bradley PJ, Singh SD. Congenital nasal masses: diagnosis and management. Clin Otolaryngol Allied Sci. 1982 Apr;7(2):87-97. PMID: 7094387; X-1
7. Brooks BS, El Gammal T, Beveridge WD. Erosion of vertebral pedicles by unusual vascular causes. Report of three cases. Neuroradiology. 1982;23(2):107-12. PMID: 7078720; X-1
8. Brown BZ, Huffaker G. Local injection of steroids for juvenile hemangiomas which disturb the visual axis. Ophthalmic Surg. 1982 Aug;13(8):630-3. PMID: 7133606; X-2
9. Carruth JA. The argon laser in he treatment of vascular naevi. Br J Dermatol. 1982 Sep;107(3):365-8. PMID: 7115616; X-1
10. Carruth JA, McKenzie AL. The argon laser in dermatology: safety aspects. Clin Exp Dermatol. 1982 May;7(3):247-53. PMID: 7105476; X-1
11. de Tribolet N, Kaech D, Perentes E. Cerebellar haematoma due to a cavernous angioma in a child. Acta Neurochir (Wien). 1982;60(1-2):37-43. PMID: 7058698; X-1
12. Demakas JJ, Sonntag VK, Kaplan AM, et al. Surgical management of pineal area tumors in early childhood. Surg Neurol. 1982 Jun;17(6):435-40. PMID: 7112375; X-1
13. Di Trapani G, Di Rocco C, Abbamondi AL, et al. Light microscopy and ultrastructural studies of Sturge-Weber disease. Childs Brain. 1982;9(1):23-36. PMID: 6460599; X-1
14. Edgerton MT. Vascular hamartomas and hemangiomas: classification and treatment. South Med J. 1982 Dec;75(12):1541-7. PMID: 7146992; X-1, X-2
15. Fabian JT, Rose AG. Tumours of the heart. A study of 89 cases. S Afr Med J. 1982 Jan 16;61(3):71-7. PMID: 6277017; X-1
16. Felder KS, Brockhurst RJ. Neovascular fundus abnormalities in peripheral uveitis. Arch Ophthalmol. 1982 May;100(5):750-4. PMID: 6177305; X-1
17. Fischer EG, Sotrel A, Welch K. Cerebral hemangioma with glial neoplasia (angioglioma?). Report of two cases. J Neurosurg. 1982 Mar;56(3):430-4. PMID: 7057243; X-1
18. Gilchrest BA, Rosen S, Noe JM. Chilling port wine stains improves the response to argon laser therapy. Plast Reconstr Surg. 1982 Feb;69(2):278-83. PMID: 7054797; X-1

19. Gresty MA, Ell JJ, Findley LJ. Acquired pendular nystagmus: its characteristics, localising value and pathophysiology. J Neurol Neurosurg Psychiatry. 1982 May;45(5):431-9. PMID: 7086456; X-1

20. Grundfest-Broniatowski S, Carey WD, Sivak MV, Jr., et al. Klippel-Trenaunay-Weber syndrome with visceral involvement and portal hypertension. Cleve Clin Q. 1982 Winter;49(4):239-47. PMID: 6301708; X-1

21. Hayman LA, Evans RA, Ferrell RE, et al. Familial cavernous angiomas: natural history and genetic study over a 5-year period. Am J Med Genet. 1982 Feb;11(2):147-60. PMID: 6950664; X-1

22. Hurvitz CH, Greenberg SH, Song CH, et al. Hemangiomatosis of the pleura with hemorrhage and disseminated intravascular coagulation. J Pediatr Surg. 1982 Feb;17(1):73-5. PMID: 7077482; X-1, X-2

23. Ilbawi M, DeLeon S, Riggs T, et al. Primary vascular tumors of the heart in infancy. Report of a case with successful surgical management. Chest. 1982 Apr;81(4):511-2. PMID: 7067518; X-1

24. Kaibara N, Mitsuyasu M, Katsuki I, et al. Generalized enchondromatosis with unusual complications of soft tissue calcifications and hemangiomas. Follow-up for over a twelve-year period. Skeletal Radiol. 1982;8(1):43-6. PMID: 7079783; X-1

25. Kalicinski ZH, Joszt W, Perdzynski W, et al. Hemangioma of the superior caval vein. J Pediatr Surg. 1982 Apr;17(2):178-9. PMID: 7077501; X-2

26. Kobus K, Licznerski A, Stepniewski J, et al. The surgical treatment of vascular tumours of the face. J Maxillofac Surg. 1982 May;10(2):99-112. PMID: 7047664; X-3, X-4

27. Kushner BJ. Intralesional corticosteroid injection for infantile adnexal hemangioma. Am J Ophthalmol. 1982 Apr;93(4):496-506. PMID: 7072814; X-4

28. Kveton JF, Pillsbury HC. Conservative treatment of infantile subglottic hemangioma with corticosteroids. Arch Otolaryngol. 1982 Feb;108(2):117-9. PMID: 7059313; X-2

29. Ladurner G, Fritsch G, Sager WD, et al. Computer tomography in children with stroke. Eur Neurol. 1982;21(4):235-41. PMID: 7117310; X-1

30. Liberski PP, Alwasiak J, Wegrzyn Z, et al. Sturge-Weber syndrome with a unilateral developmental anomaly of the cerebral hemisphere. Neuropatol Pol. 1982;20(3-4):505-10. PMID: 7183945; X-1

31. McCarthy JC, Goldberg MJ, Zimbler S. Orthopaedic dysfunction in the blue rubber-bleb nevus syndrome. J Bone Joint Surg Am. 1982 Feb;64(2):280-3. PMID: 7056783; X-1

32. Mencke HJ, Zilkens J, Bigalke KH, et al. The problem of intramuscular haemangioma. Arch Orthop Trauma Surg. 1982;100(4):243-7. PMID: 7159196; X-1

33. Moazam F, Talbert JL, Rodgers BM. Primary tumors of the liver in infancy and childhood. J Fla Med Assoc. 1982 Dec;69(12):991-6. PMID: 6296270; X-2

34. Moss LA, Stueber K, Hafiz MA. Congenital hemangioendothelioma of the hand--case report. J Hand Surg Am. 1982 Jan;7(1):53-6. PMID: 7061809; X-1

35. Nguyen L, Shandling B, Ein S, et al. Hepatic hemangioma in childhood: medical management or surgical management? J Pediatr Surg. 1982 Oct;17(5):576-9. PMID: 7175647; X-1

36. Niechajev IA, Karlsson S. Angiomatosis osteohypotrophica. Scand J Plast Reconstr Surg. 1982;16(1):77-85. PMID: 7112039; X-1

37. Niechajev IA, Karlsson S. Vascular tumours of the hand. Scand J Plast Reconstr Surg. 1982;16(1):67-75. PMID: 7112038; X-1

38. Norins AL, Treadwell PA. The management of persistent pediatric skin problems. Pediatr Clin North Am. 1982 Feb;29(1):37-53. PMID: 6460218; X-1, X-2

39. Ogawa Y, Inoue K. Electrothrombosis as a treatment of cirsoid angioma in the face and scalp and varicosis of the leg. Plast Reconstr Surg. 1982 Sep;70(3):310-8. PMID: 7111485; X-1

40. Pereyra R, Andrassy RJ, Mahour GH. Management of massive hepatic hemangiomas in infants and children: a review of 13 cases. Pediatrics. 1982 Aug;70(2):254-8. PMID: 7099792; X-3, X-4

41. Polus K. Skin haemangioma: treatment by cryosurgery. Acta Paediatr Acad Sci Hung. 1982;23(2):167-70. PMID: 7136598; X-3, X-4

42. Pretorius HT, Katikineni M, Kinsella TJ, et al. Thyroid nodules after high-dose external radiotherapy. Fine-needle aspiration cytology in diagnosis and management. Jama. 1982 Jun 18;247(23):3217-20. PMID: 7087060; X-1, X-2

43. Price JB, Jr., Schullinger JN, Santulli TV. Major hepatic resections for neoplasia in children. Arch Surg. 1982 Sep;117(9):1139-41. PMID: 6287966; X-1

44. Ramming KP, Holmes EC, Zarem HA, et al. Surgical management and reconstruction of extensive chest wall malignancies. Am J Surg. 1982 Jul;144(1):146-52. PMID: 6953769; X-1

45. Randall PA. Vascular mass. Preoperative occlusion of feeding vessel. N Y State J Med. 1982 Feb;82(2):189-91. PMID: 6952084; X-1, X-2

46. Ricketts RR, Stryker S, Raffensperger JG. Ventral fasciotomy in the management of hepatic hemangioendothelioma. J Pediatr Surg. 1982 Apr;17(2):187-8. PMID: 6210769; X-1

47. Sadan N, Sade J, Grunebaum M. The treatment of subglottic hemangiomas of infants with prednisone. Int J Pediatr Otorhinolaryngol. 1982 Mar;4(1):7-14. PMID: 7095995; X-4

48. Sanborn GE, Augsburger JJ, Shields JA. Treatment of circumscribed choroidal hemangiomas. Ophthalmology. 1982 Dec;89(12):1374-80. PMID: 6891765; X-1

49. Schneeweiss A, Blieden LC, Shem-Tov A, et al. Coarctation of the aorta with congenital hemangioma of the face and neck and aneurysm or dilatation of a subclavian or innominate artery. A new syndrome? Chest. 1982 Aug;82(2):186-7. PMID: 7047095; X-1

50. Shannon K, Buchanan GR, Votteler TP. Multiple hepatic hemangiomas: failure of corticosteroid therapy and successful hepatic artery ligation. Am J Dis Child. 1982 Mar;136(3):275-6. PMID: 7064957; X-2

51. Starzl TE, Iwatsuki S, Shaw BW, Jr., et al. Left hepatic trisegmentectomy. Surg Gynecol Obstet. 1982 Jul;155(1):21-7. PMID: 6283687; X-1

52. Verity CM, Strauss EH, Moyes PD, et al. Long-term follow-up after cerebral hemispherectomy: neurophysiologic, radiologic, and psychological findings. Neurology. 1982 Jun;32(6):629-39. PMID: 7201093; X-1

53. Abad JM, Alvarez F, Manrique M, et al. Cerebral arteriovenous malformations. Comparative results of surgical vs conservative treatment in 112 cases. J Neurosurg Sci. 1983 Jul-Sep;27(3):203-10. PMID: 6663354; X-1

54. Bart RS, Kopf AW. Tumor conference #50. Untreated massive hemangioma with satisfactory outcome. J Dermatol Surg Oncol. 1983 Nov;9(11):875-7. PMID: 6630701; X-2

55. Becht EW, Rumpelt HJ, Frohneberg D, et al. Angioma-like pseudometamorphosis in Wilms' tumors subjected to preoperative radio- and chemotherapy. Pathol Res Pract. 1983 Jun;177(1):22-31. PMID: 6312438; X-1

56. Bendl BJ, Bashir R, Dowling AD. Sturge-Weber syndrome. Cutis. 1983 Mar;31(3):286-94. PMID: 6839805; X-1

57. Benjamin B, Carter P. Congenital laryngeal hemangioma. Ann Otol Rhinol Laryngol. 1983 Sep-Oct;92(5 Pt 1):448-55. PMID: 6625442; X-2

58. Bernhard LM, Brant RG, Bakst MJ, et al. Hypertrophic hemangioma vs. hemangiopericytoma. J Foot Surg. 1983 Winter;22(4):308-13. PMID: 6643939; X-1

59. Bouwman DL, Walt AJ. Current status of resection for hepatic neoplasms. Semin Liver Dis. 1983 Aug;3(3):193-202. PMID: 6623102; X-1

60. Browne AF, Katz S, Miser J, et al. Blue Rubber Bleb Nevi as a cause of intussusception. J Pediatr Surg. 1983 Feb;18(1):7-9. PMID: 6834229; X-1

61. Charboneau JW, Hattery RR, Ernst EC, 3rd, et al. Spectrum of sonographic findings in 125 renal masses other than benign simple cyst. AJR Am J Roentgenol. 1983 Jan;140(1):87-94. PMID: 6295123; X-1

62. Chew E, Morin JD. Glaucoma in children. Pediatr Clin North Am. 1983 Dec;30(6):1043-60. PMID: 6646864; X-1

63. Corbella F, Arico M, Podesta AF, et al. Infantile hepatic hemangioendothelioma treated by radiotherapy. Pediatr Radiol. 1983;13(5):297-300. PMID: 6622093; X-1

64. Crow J, Gibbs DA, Cozens W, et al. Biochemical and histopathological studies on patients with mucopolysaccharidoses, two of whom had been treated by fibroblast transplantation. J Clin Pathol. 1983 Apr;36(4):415-30. PMID: 6403596; X-1

65. Dachman AH, Lichtenstein JE, Friedman AC, et al. Infantile hemangioendothelioma of the liver: a radiologic-pathologic-clinical correlation. AJR Am J Roentgenol. 1983 Jun;140(6):1091-6. PMID: 6602472; X-1

66. David TJ, Evans DI, Stevens RF. Haemangioma with thrombocytopenia (Kasabach-Merritt syndrome). Arch Dis Child. 1983 Dec;58(12):1022-3. PMID: 6660888; X-1

67. Edmondson HA, Peters RL. Tumors of the liver: pathologic features. Semin Roentgenol. 1983 Apr;18(2):75-83. PMID: 6306841; X-1, X-2

68. Ehren H, Mahour GH, Isaacs H, Jr. Benign liver tumors in infancy and childhood. Report of 48 cases. Am J Surg. 1983 Mar;145(3):325-9. PMID: 6837854; X-3, X-4

69. Esterly NB. Kasabach-Merritt syndrome in infants. J Am Acad Dermatol. 1983 Apr;8(4):504-13. PMID: 6853783; X-1

70. Ford CN. Serial excision and advancement flaps in the management of facial lesions. Otolaryngol Head Neck Surg. 1983 Apr;91(2):156-64. PMID: 6408572; X-1

71. Gibbs DA, Spellacy E, Tompkins R, et al. A clinical trial of fibroblast transplantation for the treatment of mucopolysaccharidoses. J Inherit Metab Dis. 1983;6(2):62-81. PMID: 6410119; X-1

72. Gonzalez DG, Breur K. Clinical data from irradiated growing long bones in children. Int J Radiat Oncol Biol Phys. 1983 Jun;9(6):841-6. PMID: 6863057; X-1

73. Gu BK. 10 cases of cavernous hemangioma treated with injection of "Xiao Zhi Ling" solution. J Tradit Chin Med. 1983 Dec;3(4):289-90. PMID: 6325829; X-1

74. Haik BG, Clancy P, Ellsworth RM, et al. Ocular manifestations in diffuse neonatal hemangiomatosis. J Pediatr Ophthalmol Strabismus. 1983 May-Jun;20(3):101-5. PMID: 6864423; X-1

75. Hall JG, Reed SD, Driscoll EP. Part I. Amyoplasia: a common, sporadic condition with congenital contractures. Am J Med Genet. 1983 Aug;15(4):571-90. PMID: 6614047; X-1

76. Hanchard B, Persaud V, Kerr G, et al. Primary infantile haemangioendothelioma of the liver. West Indian Med J. 1983 Mar;32(1):44-7. PMID: 6868571; X-1

77. Healy M, Herz DA, Pearl L. Spinal hemangiomas. Neurosurgery. 1983 Dec;13(6):689-91. PMID: 6657023; X-1

78. Hobby LW. Further evaluation of the potential of the argon laser in the treatment of strawberry hemangiomas. Plast Reconstr Surg. 1983 Apr;71(4):481-9. PMID: 6681910; X-2

79. Hurwitz A, Milwidsky A, Yarkoni S, et al. Severe fetal distress with hydramnios due to chorioangioma. Acta Obstet Gynecol Scand. 1983;62(6):633-5. PMID: 6367341; X-1

80. Jacobs AH. Vascular nevi. Pediatr Clin North Am. 1983 Jun;30(3):465-82. PMID: 6877893; X-2

81. Kadir S, Ernst CB, Hamper U, et al. Management of vascular soft tissue neoplasms using transcatheter embolization and surgical excision. Am J Surg. 1983 Sep;146(3):409-12. PMID: 6614340; X-1

82. Keeling JW, Gough DJ, Iliff P. The pathology of non-Rhesus hydrops. Diagn Histopathol. 1983 Apr-Jun;6(2):89-111. PMID: 6661995; X-1

83. Ketonen L, Koskiniemi ML. Gyriform calcification after herpes simplex virus encephalitis. J Comput Assist Tomogr. 1983 Dec;7(6):1070-2. PMID: 6630636; X-1

84. Koerper MA, Addiego JE, Jr., deLorimier AA, et al. Use of aspirin and dipyridamole in children with platelet trapping syndromes. J Pediatr. 1983 Feb;102(2):311-4. PMID: 6822944; X-1

85. Kopf AW, Bart RS. Tumor Conference #48. Massive congenital hemangioma resulting in death. J Dermatol Surg Oncol. 1983 Jul;9(7):509-12. PMID: 6853818; X-1

86. Kumakiri M, Muramoto F, Tsukinaga I, et al. Crystalline lamellae in the endothelial cells of a type of hemangioma characterized by the proliferation of immature endothelial cells and pericytes--angioblastoma (Nakagawa). J Am Acad Dermatol. 1983 Jan;8(1):68-75. PMID: 6826810; X-1

87. Landwehr AJ, Starink TM. Inflammatory linear verrucous epidermal naevus. Report of a case with bilateral distribution and nail involvement. Dermatologica. 1983;166(2):107-9. PMID: 6852314; X-1

88. Lavyne MH, Patterson RH, Jr. Subchoroidal trans-velum interpositum approach to mid-third ventricular tumors. Neurosurgery. 1983 Jan;12(1):86-94. PMID: 6828226; X-1

89. Majchrzak H, Wencel T, Bierzynska-Macyszyn G, et al. Possible significance of juvenile oral venous angioma as marker of intracerebral vascular lesion. J Neurosurg. 1983 Aug;59(2):348-50. PMID: 6864304; X-1

90. Maurer AH, Holder LE, Espinola DA, et al. Three-phase radionuclide scintigraphy of the hand. Radiology. 1983 Mar;146(3):761-75. PMID: 6219422; X-1

91. Moazam F, Rodgers BM, Talbert JL. Hepatic artery ligation for hepatic hemangiomatosis of infancy. J Pediatr Surg. 1983 Apr;18(2):120-3. PMID: 6854487; X-1

92. Muhlbauer JE, Margolis RJ, Mihm MC, Jr., et al. Minimal deviation melanoma: a histologic variant of cutaneous malignant melanoma in its vertical growth phase. J Invest Dermatol. 1983 Jun;80 Suppl:63s-5s. PMID: 6854057; X-1

93. Nair K, Khera SS, Chitre AP, et al. Cryosurgery in the management of haemangiomas. J Indian Dent Assoc. 1983 Nov;55(11):463-6. PMID: 6590630; X-1

94. Ohshiro T, Maruyama Y. The ruby and argon lasers in the treatment of naevi. Ann Acad Med Singapore. 1983 Apr;12(2 Suppl):388-95. PMID: 6684895; X-1, X-2

95. Paller AS, Esterly NB, Charrow J, et al. Pedal hemangiomas in Turner syndrome. J Pediatr. 1983 Jul;103(1):87-8. PMID: 6864400; X-1, X-2

96. Palmieri TJ. Subcutaneous hemangiomas of the hand. J Hand Surg Am. 1983 Mar;8(2):201-4. PMID: 6300216; X-1

97. Plesner-Rasmussen HJ, Marushak D, Andersen M. Sequelae of capillary hemangiomas of the eyelids and orbita. Scand J Plast Reconstr Surg. 1983;17(3):241-5. PMID: 6673091; X-2

98. Plesner-Rasmussen HJ, Marushak D, Goldschmidt E. Capillary haemangiomas of the eyelids and orbit. A review of 5 children. Acta Ophthalmol (Copenh). 1983 Aug;61(4):645-54. PMID: 6637426; X-2

99. Roberts JW, Devine CJ, Jr. Urethral hemangioma: treatment by total excision and grafting. J Urol. 1983 May;129(5):1053-4. PMID: 6343630; X-1

100. Rydholm A, Berg NO. Size, site and clinical incidence of lipoma. Factors in the differential diagnosis of lipoma and sarcoma. Acta Orthop Scand. 1983 Dec;54(6):929-34. PMID: 6670522; X-1

101. Savoiardo M, Strada L, Passerini A. Cavernous hemangiomas of the orbit: value of CT, angiography, and phlebography. AJNR Am J Neuroradiol. 1983 May-Jun;4(3):741-4. PMID: 6410846; X-1

102. Schwechheimer K, Kuhl G. Arteriovenous angioma of the vein of Galen causing cardiac failure in the neonate. Report on clinical and pathological findings in two cases. Neuropediatrics. 1983 Aug;14(3):184-7. PMID: 6621811; X-1

103. Shah K. Computed tomography and radiotherapy in giant hemangioma with thrombocytopenia. Comput Radiol. 1983 Sep-Oct;7(5):319-22. PMID: 6641198; X-1, X-2

104. Solbiati L, Bossi MC, Bellotti E, et al. Focal lesions in the spleen: sonographic patterns and guided biopsy. AJR Am J Roentgenol. 1983 Jan;140(1):59-65. PMID: 6600326; X-1

105. Stanley P, Grinnell VS, Stanton RE, et al. Therapeutic embolization of infantile hepatic hemangioma with polyvinyl alcohol. AJR Am J Roentgenol. 1983 Nov;141(5):1047-51. PMID: 6605046; X-2

106. Stillman AE, Hansen RC, Hallinan V, et al. Diffuse neonatal hemangiomatosis with severe gastrointestinal involvement. Favorable response to steroid therapy. Clin Pediatr (Phila). 1983 Aug;22(8):589-91. PMID: 6602682; X-1

107. Swerlick RA, Cooper PH. Pyogenic granuloma (lobular capillary hemangioma) within port-wine stains. J Am Acad Dermatol. 1983 May;8(5):627-30. PMID: 6863618; X-1

108. Trastek VF, van Heerden JA, Sheedy PF, 2nd, et al. Cavernous hemangiomas of the liver: resect or observe? Am J Surg. 1983 Jan;145(1):49-53. PMID: 6849494; X-1

109. Vorse HB, Smith EI, Luckstead EF, et al. Hepatic hemangiomatosis of infancy. Am J Dis Child. 1983 Jul;137(7):672-3. PMID: 6858982; X-1

110. Wu MC, Zhang XH, Chen H, et al. Experiences in 467 cases of hepatic resection. Acta Acad Med Wuhan. 1983;3(1):1-7. PMID: 6866375; X-1

111. Yoshida T, Kuratomi K, Mitsumasu T. Benign neoplasms of the larynx. A 10-year review of 38 patients. Auris Nasus Larynx. 1983;10 Suppl:S61-71. PMID: 6316888; X-2

112. Young PH. Lumbar hemangioendothelioma. Surg Neurol. 1983 Jul;20(1):55-6. PMID: 6867929; X-1

113. Zocchi D, Innao V, Calderoni P. Maffucci's syndrome. Report of 3 cases and review of the literature. Ital J Orthop Traumatol. 1983 Jun;9(2):263-6. PMID: 6654663; X-1

114. . Special symposia. The management of disseminated eruptive hemangiomata in infants. Pediatr Dermatol. 1984 Apr;1(4):312-7. PMID: 6494071; X-1

115. Abramson DH. Intraocular tumors. Hosp Pract (Off Ed). 1984 Oct;19(10):97-106. PMID: 6434568; X-1

116. Adzick NS, Strome M, Gang D, et al. Cryotherapy of subglottic hemangioma. J Pediatr Surg. 1984 Aug;19(4):353-7. PMID: 6481576; X-2

117. Bakker-Niezen SH, Walder HA, Merx JL. The tethered spinal cord syndrome. Z Kinderchir. 1984 Dec;39 Suppl 2:100-3. PMID: 6395542; X-1

118. Bart RS, Kopf AW. Tumor conference #53. Necrotizing hemangioma. J Dermatol Surg Oncol. 1984 Oct;10(10):769-73. PMID: 6491015; X-2

119. Bluemm RG, Baleriaux D, Lausberg G, et al. Initial experience with MR-imaging of intracranial midline-lesions and lesions of the cervical spine at half Tesla. Neurosurg Rev. 1984;7(4):287-302. PMID: 6099524; X-1

120. Carvell JE, Chopin D. Infantile idiopathic scoliosis in hemihypertrophy with haemangiomatosis. J R Coll Surg Edinb. 1984 Sep;29(5):321-5. PMID: 6094802; X-1

121. Chen TJ, Kuo T. Giant intracranial Masson's hemangioma. Report of a fatal case. Arch Pathol Lab Med. 1984 Jul;108(7):555-6. PMID: 6547319; X-2

122. Chuong R, Donoff RB. Intraparotid hemangioma in an adult. Case report and review of the literature. Int J Oral Surg. 1984 Aug;13(4):346-51. PMID: 6434455; X-1

123. Cibis GW, Tripathi RC, Tripathi BJ. Glaucoma in Sturge-Weber syndrome. Ophthalmology. 1984 Sep;91(9):1061-71. PMID: 6493715; X-1

124. Crandall AS. Developmental ocular abnormalities and glaucoma. Int Ophthalmol Clin. 1984 Spring;24(1):73-86. PMID: 6443569; X-1

125. Demuth RJ, Miller SH, Keller F. Complications of embolization treatment for problem cavernous hemangiomas. Ann Plast Surg. 1984 Aug;13(2):135-44. PMID: 6476734; X-1

126. Desgrippes Y, Bensahel H, Sonsino E, et al. Atypical bone angiomas in children. Ital J Orthop Traumatol. 1984 Jun;10(2):251-5. PMID: 6381397; X-1

127. Dixon JA, Rotering RH, Huether SE. Patient's evaluation of argon laser therapy of port wine stain, decorative tattoo, and essential telangiectasia. Lasers Surg Med. 1984;4(2):181-90. PMID: 6472031; X-1

128. Fitzsimons R. Intralesional corticosteroid injection of infantile adnexal haemangioma. Trans Ophthalmol Soc N Z. 1984;36:74-5. PMID: 6591621; X-2

129. Folkman J. Toward a new understanding of vascular proliferative disease in children. Pediatrics. 1984 Nov;74(5):850-6. PMID: 6208529; X-1

130. Garcia RL, Dixon SL. Occlusion amblyopia secondary to a mixed capillary-cavernous hemangioma. J Am Acad Dermatol. 1984 Feb;10(2 Pt 1):263-7. PMID: 6715593; X-1

131. Gooding CA, Brasch RC, Lallemand DP, et al. Nuclear magnetic resonance imaging of the brain in children. J Pediatr. 1984 Apr;104(4):509-15. PMID: 6707810; X-1

132. Greene EE, Iams JD. Chorioangioma: a case presentation. Am J Obstet Gynecol. 1984 Apr 15;148(8):1146-8. PMID: 6711654; X-1

133. Hachisuga T, Hashimoto H, Enjoji M. Angioleiomyoma. A clinicopathologic reappraisal of 562 cases. Cancer. 1984 Jul 1;54(1):126-30. PMID: 6722737; X-1

134. Hanada T, Nakahara S, Takita H, et al. 111In-labelled platelet scintigraphy in Kasabach-Merritt syndrome. Nihon Ketsueki Gakkai Zasshi. 1984 Sep;47(6):1359-65. PMID: 6542736; X-1

135. Hawkins DB, Crockett DM, Kahlstrom EJ, et al. Corticosteroid management of airway hemangiomas: long-term follow-up. Laryngoscope. 1984 May;94(5 Pt 1):633-7. PMID: 6717220; X-2

136. Heffner DK. Problems in pediatric otorhinolaryngic pathology. V. Diseases of the larynx and trachea. Int J Pediatr Otorhinolaryngol. 1984 Jul;7(3):203-19. PMID: 6480230; X-1

137. Heikkinen ES, Salminen PM. Surgical treatment of congenital thoraco-brachial arterio-venous macrofistula, complicated by haemorrhage, infection and congestive heart failure. Z Kinderchir. 1984 Oct;39(5):337-8. PMID: 6516595; X-1

138. Hermann G, Yeh HC, Schwartz I. Computed tomography of soft-tissue lesions of the extremities, pelvic and shoulder girdles: sonographic and pathological correlations. Clin Radiol. 1984 May;35(3):193-202. PMID: 6713795; X-1, X-2

139. Howell DM, Gumbiner CH, Martin GE. Congestive heart failure due to giant cutaneous cavernous hemangioma. Clin Pediatr (Phila). 1984 Sep;23(9):504-6. PMID: 6467784; X-1

140. Ikegami N, Nishijima K. Hemangioma of the buccal pad with phlebolithiasis: report of a case. Acta Med Okayama. 1984 Feb;38(1):79-87. PMID: 6702488; X-1

141. Johnson DH, Vinson AM, Wirth FH, et al. Management of hepatic hemangioendotheliomas of infancy by transarterial embolization: a report of two cases. Pediatrics. 1984 Apr;73(4):546-9. PMID: 6709438; X-1

142. Jooma R, Kendall BE, Hayward RD. Intracranial tumors in neonates: a report of seventeen cases. Surg Neurol. 1984 Feb;21(2):165-70. PMID: 6322370; X-1

143. Kaplan I, Sarig A, Taube E, et al. The CO2 laser in pediatric surgery. J Pediatr Surg. 1984 Jun;19(3):248-57. PMID: 6431072; X-1

144. Katoh H, Nakajima T, Yoshimura Y. The double-Z rhomboid plasty: an improvement in design. Plast Reconstr Surg. 1984 Dec;74(6):817-24. PMID: 6505101; X-1

145. Khosla VK, Banerjee AK, Mathuriya SN, et al. Giant cystic cavernoma in a child. Case report. J Neurosurg. 1984 Jun;60(6):1297-9. PMID: 6726375; X-1

146. Kulkarni MV, Shaff MI, Sandler MP, et al. Evaluation of renal masses by MR imaging. J Comput Assist Tomogr. 1984 Oct;8(5):861-5. PMID: 6088602; X-1

147. Lazerson J. An invasive hemangioma and failure to thrive. Hosp Pract (Off Ed). 1984 Dec;19(12):32, 4. PMID: 6438131; X-2

148. Leavitt A. Cavernous hemangioma of the face, larynx, and subglottic region. Med Pediatr Oncol. 1984;12(6):377-9. PMID: 6503857; X-1

149. Luna RF, Resende C, Tishler JM, et al. Computerized tomography in evaluation of hepatic neoplasms. South Med J. 1984 Aug;77(8):1015-9. PMID: 6087466; X-1

150. Lyon AJ, Johnson J. Non immune hydrops fetalis. J R Army Med Corps. 1984 Feb;130(1):66-8. PMID: 6716361; X-1

151. Ma GF, Leung PC. The management of the soft-tissue haemangiomatous manifestations of Maffucci's syndrome. Br J Plast Surg. 1984 Oct;37(4):615-8. PMID: 6498405; X-1

152. Maddox JL, Jr., Riordan TP, Odom RB. Pyomyositis in a neonate. J Am Acad Dermatol. 1984 Feb;10(2 Pt 2):391-4. PMID: 6707262; X-1

153. Maeda K. A successful case of urethral reconstruction in a child with persistent urethral bleeding due to an extensive cavernous haemangioma. Br J Plast Surg. 1984 Oct;37(4):536-8. PMID: 6498393; X-1

154. McBride JT. Stridor in childhood. J Fam Pract. 1984 Dec;19(6):782-90. PMID: 6502082; X-1

155. McIntosh C, Dehkharghani F. The neurocutaneous syndromes: diagnosis and management for the primary care pediatrician. J Ark Med Soc. 1984 Dec;81(7):354-60. PMID: 6240482; X-1

156. Messmer E, Font RL, Laqua H, et al. Cavernous hemangioma of the retina. Immunohistochemical and ultrastructural observations. Arch Ophthalmol. 1984 Mar;102(3):413-8. PMID: 6538410; X-1

157. Mizono G, Dedo HH. Subglottic hemangiomas in infants: treatment with CO2 laser. Laryngoscope. 1984 May;94(5 Pt 1):638-41. PMID: 6717221; X-4

158. Nelson LB, Melick JE, Harley RD. Intralesional corticosteroid injections for infantile hemangiomas of the eyelid. Pediatrics. 1984 Aug;74(2):241-5. PMID: 6462821; X-2

159. Newman SL, Goodwin CD. Colonic hemangioma in childhood. Diagnostic and therapeutic contribution of colonoscopy. Clin Pediatr (Phila). 1984 Oct;23(10):584-5. PMID: 6331940; X-1

160. Nielsen G. Arteriovenous malformations as a cause of congestive heart failure in the newborn and infant. Three cases with different haemodynamic mechanisms. Eur J Pediatr. 1984 Sep;142(4):298-300. PMID: 6541577; X-1

161. Nistal M, Paniagua R, Fuentes E, et al. Histogenesis of adenomatoid tumour associated to pseudofibromatous periorchitis in an infant with hydrocele. J Pathol. 1984 Dec;144(4):275-80. PMID: 6520651; X-1

162. Noronha R, Gonzalez-Crussi F. Hepatic angiosarcoma in childhood. A case report and review of the literature. Am J Surg Pathol. 1984 Nov;8(11):863-71. PMID: 6542321; X-1

163. Novitzky D, Rose AG, Morgan JA, et al. Primary cardiac haemangiomas. A report of 2 cases. S Afr Med J. 1984 Aug 18;66(7):267-70. PMID: 6463804; X-1

164. Pasyk KA, Dingman RO, Argenta LC, et al. The management of hemangiomas of the eyelid and orbit. Head Neck Surg. 1984 Mar-Apr;6(4):851-7. PMID: 6706624; X-2

165. Persky MS, Berenstein A, Cohen NL. Combined treatment of head and neck vascular masses with preoperative embolization. Laryngoscope. 1984 Jan;94(1):20-7. PMID: 6690874; X-2

166. Person VA, Lembach LJ, Tax HR, et al. Case comparisons of arch-area arteriovenous fistula and cavernous hemangioma. J Am Podiatry Assoc. 1984 Nov;74(11):569-71. PMID: 6501778; X-1

167. Petersen KE. ACTH in normal children and children with pituitary and adrenal diseases. II. Plasma ACTH (cortisol and growth hormone) values during insulin hypoglycaemia--patients with idiopathic hypopituitarism and intracranial tumour. Acta Paediatr Scand. 1984 May;73(3):372-8. PMID: 6331059; X-1

168. Pitanguy I, Caldeira AM, Calixto CA, et al. Clinical evaluation and surgical treatment of hemangiomata. Head Neck Surg. 1984 Oct;7(1):47-59. PMID: 6490384; X-1, X-2

169. Rao PL, Nair KV, Nooruddin SM, et al. Cryosurgery in the management of hemangiomas in children. Indian Pediatr. 1984 Feb;21(2):139-43. PMID: 6469296; X-4

170. Richardson MA, Cotton RT. Anatomic abnormalities of the pediatric airway. Pediatr Clin North Am. 1984 Aug;31(4):821-34. PMID: 6462801; X-1

171. Riggs T, Sholl JS, Ilbawi M, et al. In utero diagnosis of pericardial tumor with successful surgical repair. Pediatr Cardiol. 1984 Jan-Mar;5(1):23-5. PMID: 6462925; X-1

172. Rosen I, Salford L, Starck L. Sturge-Weber disease--neurophysiological evaluation of a case with secondary epileptogenesis, successfully treated with lobe-ectomy. Neuropediatrics. 1984 May;15(2):95-8. PMID: 6738822; X-1

173. Rothfus WE, Albright AL, Casey KF, et al. Cerebellar venous angioma: "benign" entity? AJNR Am J Neuroradiol. 1984 Jan-Feb;5(1):61-6. PMID: 6421127; X-1

174. Ryan EA, Reiss E. Oncogenous osteomalacia. Review of the world literature of 42 cases and report of two new cases. Am J Med. 1984 Sep;77(3):501-12. PMID: 6548080; X-1

175. Salyer KE. Use of a new hemostatic scalpel in plastic surgery. Ann Plast Surg. 1984 Dec;13(6):532-8. PMID: 6441505; X-1

176. Sant GR, Heaney JA, Ucci AA, Jr., et al. Computed tomographic findings in renal angiomyolipoma: an histologic correlation. Urology. 1984 Sep;24(3):293-6. PMID: 6474646; X-1

177. Sasaki GH, Pang CY, Wittliff JL. Pathogenesis and treatment of infant skin strawberry hemangiomas: clinical and in vitro studies of hormonal effects. Plast Reconstr Surg. 1984 Mar;73(3):359-70. PMID: 6701212; X-1

178. Schmidt RP, Lentle BC. Hemangioma with consumptive coagulopathy (Kasabach-Merritt syndrome) detection by indium-111 oxine-labeled platelets. Clin Nucl Med. 1984 Jul;9(7):389-91. PMID: 6432394; X-1, X-2

179. Smith JD, Cook TA. Argon laser treatment of hemangiomas in children. Int J Pediatr Otorhinolaryngol. 1984 May;7(2):153-8. PMID: 6540251; X-1

180. Sondel PM, Ritter MW, Wilson DG, et al. Use of 111In platelet scans in the detection and treatment of Kasabach-Merritt syndrome. J Pediatr. 1984 Jan;104(1):87-9. PMID: 6690678; X-1

181. Stringel G, Mercer S. Giant hemangioma in the newborn and infant. Complications and management. Clin Pediatr (Phila). 1984 Sep;23(9):498-502. PMID: 6467783; X-1, X-2

182. Suzuki J, Katakura R, Mori T. Interhemispheric approach through the lamina terminalis to tumors of the anterior part of the third ventricle. Surg Neurol. 1984 Aug;22(2):157-63. PMID: 6740479; X-1

183. Tax HR. The handicapped child. Clin Podiatry. 1984 Dec;1(3):459-76. PMID: 6242142; X-1

184. Tschappeler H. CT-evaluation of the pediatric mediastinum. Ann Radiol (Paris). 1984 Feb-Mar;27(2-3):160-5. PMID: 6721423; X-1

185. Tsementzis SA, Kennett RP, Hitchcock ER. Rupture of intracranial vascular lesions during arteriography. J Neurol Neurosurg Psychiatry. 1984 Aug;47(8):795-8. PMID: 6470721; X-1

186. Wakai S, Chiu CW. Rare combination of spinal lesions and spina bifida occulta: case report. Dev Med Child Neurol. 1984 Feb;26(1):117-21. PMID: 6365665; X-1

187. Weber TR, West KW, Cohen M, et al. Massive hemangioma in infants: therapeutic considerations. J Vasc Surg. 1984 May;1(3):423-8. PMID: 6481892; X-4

188. Weinblatt ME, Kahn E, Kochen JA. Hemangioendothelioma with intravascular coagulation and ischemic colitis. Cancer. 1984 Nov 15;54(10):2300-4. PMID: 6488150; X-1

189. Achauer BM, Vander Kam VM. Argon laser treatment of strawberry hemangioma in infancy. West J Med. 1985 Nov;143(5):628-32. PMID: 4082569; X-4

190. Adelt D, Zeumer H, Wolters J. Surgical treatment of cerebral arteriovenous malformations. Follow-up study of 43 cases. Acta Neurochir (Wien). 1985;76(1-2):45-9. PMID: 4003127; X-1

191. Alkalay AL, Puri AR, Pomerance JJ, et al. Mesenchymal hamartoma of the liver responsive to cyclophosphamide therapy: therapeutic approach. J Pediatr Surg. 1985 Apr;20(2):125-8. PMID: 4009357; X-1

192. Alpers CE, Edwards MS. Hemangiomatous anomaly of bone in Crouzon's syndrome: case report. Neurosurgery. 1985 Mar;16(3):391-4. PMID: 3982620; X-1

193. Alt B, Hafez GR, Trigg M, et al. Angiosarcoma of the liver and spleen in an infant. Pediatr Pathol. 1985;4(3-4):331-9. PMID: 3835556; X-1

194. Alves JC, Fernal WH, Christo MC, et al. Giant haemangioma of the thigh (Kasabach-Merritt syndrome): resection with temporary clamping of the common iliac artery. Br J Plast Surg. 1985 Jul;38(3):426-8. PMID: 4040413; X-1, X-2

195. Apfelberg DB, Maser MR, Lash H, et al. Benefits of the CO2 laser in oral hemangioma excision. Plast Reconstr Surg. 1985 Jan;75(1):46-50. PMID: 3917570; X-4

196. Arodi J, Auslender R, Atad J, et al. Giant chorioangioma of the placenta. Acta Obstet Gynecol Scand. 1985;64(1):91-2. PMID: 3883693; X-1

197. Bonafe JL, Laffitte F, Chavoin JP, et al. Hyperpigmentation induced by argon laser therapy of hemangiomas. Optical and electron microscope studies. Dermatologica. 1985;170(5):225-9. PMID: 4007217; X-1

198. Burrows PE, Rosenberg HC, Chuang HS. Diffuse hepatic hemangiomas: percutaneous transcatheter embolization with detachable silicone balloons. Radiology. 1985 Jul;156(1):85-8. PMID: 4001425; X-1, X-2

199. Chadduck WM, Binet EF, Farrell FW, Jr., et al. Intraventricular cavernous hemangioma: report of three cases and review of the literature. Neurosurgery. 1985 Feb;16(2):189-97. PMID: 3974830; X-1

200. Clodius L. Surgery for the extensive facial port-wine stain? Aesthetic Plast Surg. 1985;9(2):61-8. PMID: 3895849; X-1

201. Cotton RT, Tewfik TL. Laryngeal stenosis following carbon dioxide laser in subglottic hemangioma. Report of three cases. Ann Otol Rhinol Laryngol. 1985 Sep-Oct;94(5 Pt 1):494-7. PMID: 3931531; X-2

202. Craig RD, Purser JM, Lessells AM, et al. Argon laser therapy for cutaneous lesions. Br J Plast Surg. 1985 Apr;38(2):148-55. PMID: 3986414; X-1

203. Crockett DM, Healy GB, McGill TJ, et al. Benign lesions of the nose, oral cavity, and oropharynx in children: excision by carbon dioxide laser. Ann Otol Rhinol Laryngol. 1985 Sep-Oct;94(5 Pt 1):489-93. PMID: 3931530; X-2

204. Davis C, Symon L. The management of cerebral arteriovenous malformations. Acta Neurochir (Wien). 1985;74(1-2):4-11. PMID: 3976444; X-1

205. Dreno B, Patrice T, Litoux P, et al. The benefit of chilling in argon-laser treatment of port-wine stains. Plast Reconstr Surg. 1985 Jan;75(1):42-5. PMID: 3966106; X-1

206. Enjolras O, Riche MC, Merland JJ. Facial port-wine stains and Sturge-Weber syndrome. Pediatrics. 1985 Jul;76(1):48-51. PMID: 4011357; X-1

207. Feingold M. Picture of the month. Hemangioma and lymphangioma of the nose. Am J Dis Child. 1985 Mar;139(3):319-20. PMID: 3976616; X-1, X-2

208. Fischer AQ, Leibrock LG, Anderson JC. Evaluation of congenital extracranial masses by waterpath sonography. Pediatr Neurol. 1985 Mar-Apr;1(2):117-9. PMID: 3880395; X-1

209. Foley WD, Milde MW. Intra-arterial digital subtraction angiography. Radiol Clin North Am. 1985 Jun;23(2):293-319. PMID: 2986195; X-1

210. Frerebeau P, Benezech J, Segnarbieux F, et al. Intraventricular tumors in tuberous sclerosis. Childs Nerv Syst. 1985;1(1):45-8. PMID: 3986841; X-1

211. Fujino T, Yamamoto K, Kuboto J, et al. Microsurgical technique in resection of hemangioma in infants. Ann Plast Surg. 1985 Mar;14(3):190-204. PMID: 3994264; X-2

212. Haik BG, Saint Louis L, Smith ME, et al. Computed tomography of the nonrhegmatogenous retinal detachment in the pediatric patient. Ophthalmology. 1985 Aug;92(8):1133-42. PMID: 3840243; X-1

213. Han JS, Benson JE, Kaufman B, et al. MR imaging of pediatric cerebral abnormalities. J Comput Assist Tomogr. 1985 Jan-Feb;9(1):103-14. PMID: 3968257; X-1

214. Hayashi T, Fukui M, Shyojima K, et al. Giant cerebellar hemangioma in an infant. Childs Nerv Syst. 1985;1(4):230-3. PMID: 4064023; X-1, X-2

215. Helin I, Persson PH. Intra-abdominal cysts detected at prenatal ultrasound screening. Helv Paediatr Acta. 1985 Apr;40(1):55-9. PMID: 3916364; X-1

216. Hertzanu Y, Mendelsohn DB, Davidge-Pitts K, et al. Preoperative embolization in paediatric maxillofacial haemangiomas. J Laryngol Otol. 1985 Nov;99(11):1089-95. PMID: 4056594; X-1, X-2

217. Hill JH, Mafee MF, Chow JM, et al. Dynamic computerized tomography in the assessment of hemangioma. Am J Otolaryngol. 1985 Jan-Feb;6(1):23-8. PMID: 3977008; X-2

218. Horie H, Iwasaki I, Iida H, et al. Benign hemangioendothelioma of the pancreas with obstructive jaundice. Acta Pathol Jpn. 1985 Jul;35(4):975-9. PMID: 4072679; X-1

219. Iliev E, Chilova-Atanassova B. Hemangioma on the eyelids and ocular conjunctiva. Folia Med (Plovdiv). 1985;27(1):27-34. PMID: 3937800; X-3, X-4

220. Jacobson HG. Dense bone--too much bone: radiological considerations and differential diagnosis. Part II. Skeletal Radiol. 1985;13(2):97-113. PMID: 3883506; X-1

221. Laskin JL, Lawrence MA. An oral hemangioma in a three-month-old child: clinical report. Pediatr Dent. 1985 Sep;7(3):231-4. PMID: 3865163; X-1, X-2

222. Lofgren EP, Lofgren KA. Surgical treatment of cavernous hemangioma. Surgery. 1985 Apr;97(4):474-80. PMID: 3983824; X-1

223. Maillard GF, Geinoz J. Argon laser photocoagulation of various angiomas. Br J Plast Surg. 1985 Apr;38(2):156-62. PMID: 3986415; X-1, X-2

224. Mazoit JX, Brunelle F, Danel P, et al. Therapeutic embolization of hemangiomas and hemangioendotheliomas of the liver in infants. A hemodynamics study. Ann Radiol (Paris). 1985;28(3-4):283-8. PMID: 4014979; X-2

225. McIntosh WA, Lownie JF, Berezowski BM. Haemangioma of the mandible. Diagnosis and management. J Laryngol Otol. 1985 Sep;99(9):913-7. PMID: 4045312; X-1

226. Miller JH, Greenspan BS. Integrated imaging of hepatic tumors in childhood. Part II: Benign lesions (congenital, reparative, and inflammatory). Radiology. 1985 Jan;154(1):91-100. PMID: 3880615; X-1

227. Milligan NS, Edwards JC, Monro JL, et al. Excision of giant haemangioma in the newborn using hypothermia and cardiopulmonary bypass. Anaesthesia. 1985 Sep;40(9):875-8. PMID: 4051152; X-1

228. Mohr G, Hardy J, Gauvin P. Chiasmal apoplexy due to ruptured cavernous hemangioma of the optic chiasm. Surg Neurol. 1985 Dec;24(6):636-40. PMID: 4060042; X-1

229. Narcy P, Contencin P, Bobin S, et al. Treatment of infantile subglottic hemangioma. A report of 49 cases. Int J Pediatr Otorhinolaryngol. 1985 Jul;9(2):157-64. PMID: 4030237; X-3, X-4

230. Nem-Yun B, Zulkiflee Laidin A. Giant cavernous hemangioma of the anterior chest wall in a neonate: a case report. Med J Malaysia. 1985 Sep;40(3):252-6. PMID: 3842722; X-1, X-2

231. Ogata S, Mizoguchi H, Arita M, et al. A case of hemangiomyoma of the ureter in a child. Eur Urol. 1985;11(5):355-6. PMID: 4076279; X-1

232. O'Sullivan TJ, Healy GB. Complications of Venturi jet ventilation during microlaryngeal surgery. Arch Otolaryngol. 1985 Feb;111(2):127-31. PMID: 3977727; X-1

233. Paletta FX. Vascular tumors: 30-year inventory. Aesthetic Plast Surg. 1985;9(4):281-6. PMID: 4091084; X-2

234. Pancurak J, Goldberg MF, Frenkel M, et al. Cavernous hemangioma of the retina. Genetic and central nervous system involvement. Retina. 1985 Fall-Winter;5(4):215-20. PMID: 3835615; X-1

235. Parkin JL, Dixon JA. Argon laser treatment of head and neck vascular lesions. Otolaryngol Head Neck Surg. 1985 Apr;93(2):211-6. PMID: 3921911; X-3, X-4

236. Pode D, Meretik S, Shapiro A, et al. Diagnosis and management of renal angiomyolipoma. Urology. 1985 May;25(5):461-7. PMID: 3887727; X-1

237. Popescu V. Intratumoral ligation in the management of orofacial cavernous haemangiomas. J Maxillofac Surg. 1985 Jun;13(3):99-107. PMID: 3860592; X-1

238. Ruff RJ, Osborn AG, Harnsberger HR, et al. Extracalvarial soft tissues in cranial computed tomography. Normal anatomy and pathology. Invest Radiol. 1985 Jul;20(4):374-80. PMID: 4044178; X-1, X-2

239. Saive C, Trotteur G, Magotteaux P, et al. Portal cavernoma in a 9-year-old child. J Belge Radiol. 1985;68(6):462-3. PMID: 3912384; X-1

240. Schneider PE. Hemangioma of the tongue and adjacent structures (a case report). J Oral Med. 1985 Jul-Sep;40(3):115-9. PMID: 3162011; X-2

241. Servelle M. Klippel and Trenaunay's syndrome. 768 operated cases. Ann Surg. 1985 Mar;201(3):365-73. PMID: 2983626; X-1

242. Smith SW, Carruthers JD. Intractable periocular hemangioma of infancy. Can J Ophthalmol. 1985 Oct;20(6):220-4. PMID: 4063879; X-1, X-2

243. Sun TC, Swee RG, Shives TC, et al. Chondrosarcoma in Maffucci's syndrome. J Bone Joint Surg Am. 1985 Oct;67(8):1214-9. PMID: 4055846; X-1

244. Tateno A, Matsui A, Sakuragawa N, et al. Two siblings with multiple intracranial haemangiomatosis with calcification. J Neurol. 1985;232(2):112-4. PMID: 4020390; X-1

245. Trout HH, 3rd, McAllister HA, Jr., Giordano JM, et al. Vascular malformations. Surgery. 1985 Jan;97(1):36-41. PMID: 3966228; X-1

246. Upton J, Mulliken JB, Murray JE. Classification and rationale for management of vascular anomalies in the upper extremity. J Hand Surg Am. 1985 Nov;10(6 Pt 2):970-5. PMID: 4078289; X-1, X-2

247. van Wering JH, van der Slikke JW. Prenatal diagnosis of chorioangioma associated with polyhydramnios using ultrasound. Eur J Obstet Gynecol Reprod Biol. 1985 Apr;19(4):255-9. PMID: 3891446; X-1

248. Vilalta J, Mascaro JM. Hemangiolymphangioma of the tongue treated by transfixion technique. J Dermatol Surg Oncol. 1985 Feb;11(2):168-70. PMID: 2981911; X-1

249. Wakai S, Ueda Y, Inoh S, et al. Angiographically occult angiomas: a report of thirteen cases with analysis of the cases documented in the literature. Neurosurgery. 1985 Oct;17(4):549-56. PMID: 4058688; X-1

250. Walter C. The treatment of hemangioma with fibrin glue. Facial Plast Surg. 1985 Summer;2(4):357-62. PMID: 3877661; X-2

251. Wannakrairot P, Benjavongkulchai S. Giant hemangioma of liver with bleeding tendency: report of 2 cases. J Med Assoc Thai. 1985 Aug;68(8):432-8. PMID: 4067463; X-2

252. Wright GL, Smith RJ, Katz CD, et al. Benign parotid diseases of childhood. Laryngoscope. 1985 Aug;95(8):915-20. PMID: 4021684; X-3, X-4

253. Yanai A, Fukuda O, Soyano S, et al. Argon laser therapy of port-wine stains: effects and limitations. Plast Reconstr Surg. 1985 Apr;75(4):520-7. PMID: 3983252; X-1

254. Yenrudi S, Shuangshoti S. Bleeding of intracranial angioma as a cause of intrauterine death of fetus. J Med Assoc Thai. 1985 Nov;68(11):605-8. PMID: 4086953; X-1

255. Yu DT, Sheth KJ. Cystic renal involvement in tuberous sclerosis. Clin Pediatr (Phila). 1985 Jan;24(1):36-9. PMID: 3880684; X-1

256. Abe S. Local steroid therapy of adnexal strawberry hemangioma in infants - long-term follow-up. Eur J Plast Surg. 1986;9(1):29-35. PMID: 1987096212; X-2

257. Apfelberg DB. Summary of carbon dioxide laser usage in plastic surgery. Scand J Plast Reconstr Surg. 1986;20(1):19-24. PMID: 3775288; X-1

258. Apfelberg DB, Bailin P, Rosenberg H. Preliminary investigation of KTP/532 laser light in the treatment of hemangiomas and tattoos. Lasers Surg Med. 1986;6(1):38-42, 56-7. PMID: 3959714; X-1

259. Bell AJ, Chisholm M, Hickton M. Reversal of coagulopathy in Kasabach-Merritt syndrome with tranexamic acid. Scand J Haematol. 1986 Sep;37(3):248-52. PMID: 3787175; X-1, X-2

260. Beran M, Petruson B. Changes in the nasal mucosa of habitual nose-bleeders. Acta Otolaryngol. 1986 Sep-Oct;102(3-4):308-14. PMID: 3776525; X-1

261. Biondi A, Scotti G, Scialfa G, et al. Magnetic resonance imaging of cerebral cavernous angiomas. Acta Radiol Suppl. 1986;369:82-5. PMID: 2980619; X-1

262. Brahams D. Explanation and disclosure of risks in the treatment of children. Lancet. 1986 Apr 19;1(8486):925-6. PMID: 2870397; X-1

263. Burke DR, Verstandig A, Edwards O, et al. Infantile hemangioendothelioma: angiographic features and factors determining efficacy of hepatic artery embolization. Cardiovasc Intervent Radiol. 1986;9(3):154-7. PMID: 3089623; X-1

264. Carruth JA, Shakespeare P. Toward the ideal treatment for the port wine stain with the argon laser: better prediction and an "optimal" technique. Lasers Surg Med. 1986;6(1):2-4. PMID: 3959711; X-1

265. Choa DI, Smith MC, Evans JN, et al. Subglottic haemangioma in children. J Laryngol Otol. 1986 Apr;100(4):447-54. PMID: 3958591; X-3, X-4

266. Cleland WJ, Riding K. Subglottic hemangiomas in infants. J Otolaryngol. 1986 Apr;15(2):119-23. PMID: 3712542; X-2

267. Clodius L. Surgery for the facial port-wine stain: technique and results. Ann Plast Surg. 1986 Jun;16(6):457-71. PMID: 3273061; X-1

268. Cohen RC, Myers NA. Diagnosis and management of massive hepatic hemangiomas in childhood. J Pediatr Surg. 1986 Jan;21(1):6-9. PMID: 3511216; X-3, X-4

269. de Slegte RG, Valk J, Broere G, et al. Further experience with ultrasound examinations in the postoperative brain. Acta Neurochir (Wien). 1986;81(3-4):106-12. PMID: 3751693; X-1

270. Deady JP, Willshaw HE. Vascular hamartomas in childhood. Trans Ophthalmol Soc U K. 1986;105 (Pt 6):712-6. PMID: 3477898; X-1

271. Di Lorenzo N, Nardi P, Ciappetta P, et al. Benign tumors and tumorlike conditions of the spine. Radiological features, treatment, and results. Surg Neurol. 1986 May;25(5):449-56. PMID: 3961662; X-1

272. Dixon JA, Davis RK, Gilbertson JJ. Laser photocoagulation of vascular malformations of the tongue. Laryngoscope. 1986 May;96(5):537-41. PMID: 3754609; X-1

273. Dyer C. Death from interventionist radiology: a cautionary tale. Br Med J (Clin Res Ed). 1986 Sep 13;293(6548):686-7. PMID: 3092980; X-2

274. Ehrlich MG, Zaleske DJ. Pediatric orthopedic pain of unknown origin. J Pediatr Orthop. 1986 Jul-Aug;6(4):460-8. PMID: 3734072; X-1

275. Famiglietti PJ. Intralesional corticosteroid injection for capillary hemangioma of the eyelid. Trans Pa Acad Ophthalmol Otolaryngol. 1986;38(1):371-3. PMID: 3765021; X-2

276. Fawcett WAt, Ferry GD, Gorin LJ, et al. Immunodeficiency secondary to structural intestinal defects. Malrotation of the small bowel and cavernous hemangioma of the jejunum. Am J Dis Child. 1986 Feb;140(2):169-72. PMID: 3484895; X-1

277. Fernell E, Hagberg B, Hagberg G, et al. Epidemiology of infantile hydrocephalus in Sweden. I. Birth prevalence and general data. Acta Paediatr Scand. 1986 Nov;75(6):975-81. PMID: 3564981; X-1

278. Fishman MA, Baram TZ. Megalencephaly due to impaired cerebral venous return in a Sturge-Weber variant syndrome. J Child Neurol. 1986 Apr;1(2):115-8. PMID: 3598114; X-1

279. Forbes G, Earnest Ft, Jackson IT, et al. Therapeutic embolization angiography for extra-axial lesions in the head. Mayo Clin Proc. 1986 Jun;61(6):427-41. PMID: 3012215; X-1

280. Goldberg NS, Hebert AA, Esterly NB. Sacral hemangiomas and multiple congenital abnormalities. Arch Dermatol. 1986 Jun;122(6):684-7. PMID: 3717979; X-3

281. Golitz LE, Rudikoff J, O'Meara OP. Diffuse neonatal hemangiomatosis. Pediatr Dermatol. 1986 Feb;3(2):145-52. PMID: 3952031; X-1

282. Gough JD, Keeling JW, Castle B, et al. The obstetric management of non-immunological hydrops. Br J Obstet Gynaecol. 1986 Mar;93(3):226-34. PMID: 3964598; X-1

283. Haik BG, Ellsworth RM. Pediatric orbital tumors. Trans New Orleans Acad Ophthalmol. 1986;34:89-109. PMID: 3726971; X-2

284. Hobby LW. Argon laser treatment of superficial vascular lesions in children. Lasers Surg Med. 1986;6(1):16-9, 46-9. PMID: 3959710; X-2

285. Hurvitz CH, Alkalay AL, Sloninsky L, et al. Cyclophosphamide therapy in life-threatening vascular tumors. J Pediatr. 1986 Aug;109(2):360-3. PMID: 3734975; X-2

286. Kaban LB, Mulliken JB. Vascular anomalies of the maxillofacial region. J Oral Maxillofac Surg. 1986 Mar;44(3):203-13. PMID: 3456442; X-2

287. Kibbi AG, Mihm MC, Jr., Sober AJ, et al. Diagnosis and management of malignant melanoma. Compr Ther. 1986 May;12(5):23-31. PMID: 2940047; X-1

288. Leithiser RE, Jr., Fyfe D, Weatherby E, 3rd, et al. Prenatal sonographic diagnosis of atrial hemangioma. AJR Am J Roentgenol. 1986 Dec;147(6):1207-8. PMID: 3535456; X-1

289. Liu P, Daneman A, Stringer DA, et al. Computed tomography of hemangiomas and related soft-tissue lesions in children. Can Assoc Radiol J. 1986 Dec;37(4):248-55. PMID: 2950108; X-3, X-4

290. Machen BC, Williams JP, Lum GB, et al. Intracranial gyriform calcification associated with subarachnoid fat. J Comput Tomogr. 1986 Oct;10(4):385-8. PMID: 3780268; X-1

291. Maeda M, Yamashiro Y. Diagnostic red blood cell scintigraphy in GI tract bleeding from an intestinal hemangioma. J Pediatr Gastroenterol Nutr. 1986 Nov-Dec;5(6):987-9. PMID: 3025396; X-1, X-2

292. McCaffrey TV, Cortese DA. Neodymium:YAG laser treatment of subglottic hemangioma. Otolaryngol Head Neck Surg. 1986 Mar;94(3):382-4. PMID: 3083371; X-2

293. McGahan JP, Schneider JM. Fetal neck hemangioendothelioma with secondary hydrops fetalis: sonographic diagnosis. J Clin Ultrasound. 1986 Jun;14(5):384-8. PMID: 3088056; X-1

294. Miall-Allen VM, Morgan B, Cooper P, et al. Peripheral arteriovenous fistula as a cause of neonatal cardiac failure. Int J Cardiol. 1986 Feb;10(2):177-9. PMID: 3943936; X-1

295. Minami A, Usui M, Ogino T, et al. Simultaneous reconstruction of bone and skin defects by free fibular graft with a skin flap. Microsurgery. 1986;7(1):38-45. PMID: 3702664; X-1

296. Morgan RF, Horowitz JH, Wanebo HJ, et al. Surgical management of vascular malformations of the head and neck. Am J Surg. 1986 Oct;152(4):424-9. PMID: 3766876; X-1

297. Nishizaki T, Tamaki N, Matsumoto S, et al. Consideration of the operative indications for posterior fossa venous angiomas. Surg Neurol. 1986 May;25(5):441-5. PMID: 3961660; X-1

298. Oranje AP. Blue rubber bleb nevus syndrome. Pediatr Dermatol. 1986 Sep;3(4):304-10. PMID: 3022262; X-1

299. Paley D, Evans DC. Angiomatous involvement of an extremity. A spectrum of syndromes. Clin Orthop Relat Res. 1986 May(206):215-8. PMID: 3708978; X-1

300. Paley D, Jackson RW. Synovial haemangioma of the knee joint: diagnosis by arthroscopy. Arthroscopy. 1986;2(3):174-7. PMID: 3768113; X-1

301. Patel CB, Tsai TM, Kleinert HE. Hemangioma of the median nerve: a report of two cases. J Hand Surg Am. 1986 Jan;11(1):76-9. PMID: 3944449; X-2

302. Persky MS. Congenital vascular lesions of the head and neck. Laryngoscope. 1986 Sep;96(9 Pt 1):1002-15. PMID: 3747686; X-1

303. Pribyl C, Burke SW, Roberts JM, et al. Infiltrating angiolipoma or intramuscular hemangioma? A report of five cases. J Pediatr Orthop. 1986 Mar-Apr;6(2):172-6. PMID: 3958171; X-1, X-2

304. Rosenfeld H, Sherman R. Treatment of cutaneous and deep vascular lesions with the Nd:YAG laser. Lasers Surg Med. 1986;6(1):20-3, 50-1. PMID: 3959712; X-1, X-2

305. Schofield D, Zaatari GS, Gay BB. Klippel-Trenaunay and Sturge-Weber syndromes with renal hemangioma and double inferior vena cava. J Urol. 1986 Aug;136(2):442-5. PMID: 3016342; X-1, X-2

306. Seimon LP, Hekmat F. Synovial hemangioma of the knee. J Pediatr Orthop. 1986 May-Jun;6(3):356-9. PMID: 3711330; X-1, X-2

307. Shikhani AH, Shehadi SI. Surgical treatment of giant hemangiomas of the head and neck. Otolaryngol Head Neck Surg. 1986 Jan;94(1):113-22. PMID: 3081847; X-1

308. Shorr N, Seiff SR. Central retinal artery occlusion associated with periocular corticosteroid injection for juvenile hemangioma. Ophthalmic Surg. 1986 Apr;17(4):229-31. PMID: 3714192; X-2

309. Shu QS, Hu SS, Xie AF. Advances in the design of special cryosurgical apparatus in China. Cryobiology. 1986 Apr;23(2):184-93. PMID: 3698646; X-1

310. Shulman RJ, Holmes R, Ferry GD, et al. Splanchnic bed vascular malformations and the development of portal hypertension. J Pediatr Surg. 1986 Apr;21(4):355-7. PMID: 3701554; X-1

311. Silberman S, Fresco R, Suarez C. Pseudo-Chediak-Higashi anomaly in a child with a hepatic vascular malformation. Am J Pediatr Hematol Oncol. 1986 Spring;8(1):38-42. PMID: 3013038; X-1

312. Silver L. Argon laser photocoagulation of port wine stain hemangiomas. Lasers Surg Med. 1986;6(1):24-8, 52-5. PMID: 3959713; X-1

313. Simard JM, Garcia-Bengochea F, Ballinger WE, Jr., et al. Cavernous angioma: a review of 126 collected and 12 new clinical cases. Neurosurgery. 1986 Feb;18(2):162-72. PMID: 3960293; X-1

314. Spraker MK. The vascular lesions of childhood. Dermatol Clin. 1986 Jan;4(1):79-87. PMID: 3720028; X-2

315. Stanley P, Gomperts E, Woolley MM. Kasabach-Merritt syndrome treated by therapeutic embolization with polyvinyl alcohol. Am J Pediatr Hematol Oncol. 1986 Winter;8(4):308-11. PMID: 3799931; X-1, X-2

316. Stiller AG, Skafish PR. Placental chorioangioma: a rare cause of fetomaternal transfusion with maternal hemolysis and fetal distress. Obstet Gynecol. 1986 Feb;67(2):296-8. PMID: 3945441; X-1

317. Suzuki A, Ito S, Takechi H. Follow-up study of cartilaginous bone tumors. Acta Med Okayama. 1986 Jun;40(3):147-61. PMID: 3526817; X-1

318. Tagle P, Huete I, Mendez J, et al. Intracranial cavernous angioma: presentation and management. J Neurosurg. 1986 May;64(5):720-3. PMID: 3701420; X-1

319. Takeshita M, Kagawa M, Izawa M, et al. Hemorrhagic stroke in infancy, childhood, and adolescence. Surg Neurol. 1986 Nov;26(5):496-500. PMID: 3764653; X-1

320. Tanaka K, Shimao S, Okada T, et al. Kasabach-Merritt syndrome with disseminated intravascular coagulopathy treated by exchange transfusion and surgical excision. Dermatologica. 1986;173(2):90-4. PMID: 3792604; X-1, X-2

321. Trout HH, 3rd. Management of patients with hemangiomas and arteriovenous malformations. Surg Clin North Am. 1986 Apr;66(2):333-8. PMID: 3952606; X-1, X-2

322. Trout HH, 3rd, McAllister HA, Jr., Giordano JM. Vascular anomalies. J Vasc Surg. 1986 May;3(5):833-6. PMID: 3009904; X-1, X-2

323. Vomberg PP, Buller HA, Marsman JW, et al. Hepatic artery embolisation; successful treatment of multinodular haemangiomatosis of the liver. Eur J Pediatr. 1986 Feb;144(5):472-4. PMID: 3956535; X-1

324. Weiss SW, Enzinger FM. Spindle cell hemangioendothelioma. A low-grade angiosarcoma resembling a cavernous hemangioma and Kaposi's sarcoma. Am J Surg Pathol. 1986 Aug;10(8):521-30. PMID: 3740350; X-1

325. White AK, Smith RJ. Thyroid nodules in children. Otolaryngol Head Neck Surg. 1986 Jul;95(1):70-5. PMID: 3106898; X-1

326. Wilson S, Venzel JM, Miller R. Angiography, gingival hyperplasia and Sturge-Weber syndrome: report of case. ASDC J Dent Child. 1986 Jul-Aug;53(4):283-6. PMID: 2942585; X-1

327. Wong PC, Arulkumaran S, Ratnam SS, et al. Acute polyhydramnios and cord presentation--complication of chorioangioma of the placenta--a case report. Int J Gynaecol Obstet. 1986 Feb;24(1):61-4. PMID: 2874072; X-1

328. Yamasaki T, Handa H, Yamashita J, et al. Intracranial and orbital cavernous angiomas. A review of 30 cases. J Neurosurg. 1986 Feb;64(2):197-208. PMID: 3944629; X-1

329. Yoshimoto T, Suzuki J. Radical surgery on cavernous angioma of the brainstem. Surg Neurol. 1986 Jul;26(1):72-8. PMID: 3715704; X-1

330. Adams SJ, Swain CP, Mills TN, et al. The effect of wavelength, power and treatment pattern on the outcome of laser treatment of port-wine stains. Br J Dermatol. 1987 Oct;117(4):487-94. PMID: 3314972; X-1

331. Apfelberg DB, Smith T, Lash H, et al. Preliminary report on use of the neodymium-YAG laser in plastic surgery. Lasers Surg Med. 1987;7(2):189-98. PMID: 3613811; X-1

332. Bank ER, Hernandez RJ, Byrne WJ. Gastrointestinal hemangiomatosis in children: demonstration with CT. Radiology. 1987 Dec;165(3):657-8. PMID: 3500485; X-1, X-2

333. Battistella PA, Mattesi P, Casara GL, et al. Bilateral cerebral occipital calcifications and migraine-like headache. Cephalalgia. 1987 Jun;7(2):125-9. PMID: 3111714; X-1

334. Bogan S, Simon JW, Krohel GB, et al. Astigmatism associated with adnexal masses in infancy. Arch Ophthalmol. 1987 Oct;105(10):1368-70. PMID: 3662910; X-3

335. Brauner GJ, Schliftman A. Laser surgery for children. J Dermatol Surg Oncol. 1987 Feb;13(2):178-86. PMID: 2948981; X-1

336. Burrows PE, Lasjaunias PL, Ter Brugge KG, et al. Urgent and emergent embolization of lesions of the head and neck in children: indications and results. Pediatrics. 1987 Sep;80(3):386-94. PMID: 3627890; X-3, X-4

337. Byrne JM, Gates RD. Single-case study of left cerebral hemispherectomy: development in the first five years of life. J Clin Exp Neuropsychol. 1987 Aug;9(4):423-34. PMID: 3597733; X-1

338. Cervera A, Corral MJ, Gomez Campdera FJ, et al. Idiopathic hypercalciuria in children. Classification, clinical manifestations and outcome. Acta Paediatr Scand. 1987 Mar;76(2):271-8. PMID: 3591293; X-1

339. Chandna S, Bhatnagar V, Mitra DK, et al. Hemangiolymphangioma of the urinary bladder in a child. J Pediatr Surg. 1987 Nov;22(11):1051-2. PMID: 3430315; X-1, X-2

340. Cohen AJ, Sbaschnig RJ, Hochholzer L, et al. Mediastinal hemangiomas. Ann Thorac Surg. 1987 Jun;43(6):656-9. PMID: 3592837; X-1

341. Cohen BA. Hemangiomas in infancy and childhood. Pediatr Ann. 1987 Jan;16(1):17-26. PMID: 3562091; X-2

342. Colver GB, Savin JA. Port wine stains. J R Soc Med. 1987 Oct;80(10):603. PMID: 3694594; X-1

343. Dado DV, Stalnecker MC, Kernahan DA. Experience with electrothrombosis in the treatment of angiomas. Ann Plast Surg. 1987 Jan;18(1):12-6. PMID: 3548553; X-1

344. Daum R, Denecke HJ, Roth H. Tumour-induced intraluminal stenoses of the cervical trachea--tumour excision and tracheoplasty. Prog Pediatr Surg. 1987;21:50-7. PMID: 3107073; X-2

345. Dombrowski MP, Budev H, Wolfe HM, et al. Fetal hemorrhage from umbilical cord hemangioma. Obstet Gynecol. 1987 Sep;70(3 Pt 2):439-42. PMID: 3627598; X-1

346. Fernell E, Hagberg B, Hagberg G, et al. Epidemiology of infantile hydrocephalus in Sweden. III. Origin in preterm infants. Acta Paediatr Scand. 1987 May;76(3):418-23. PMID: 2440228; X-1

347. Fernell E, Hagberg B, Hagberg G, et al. Epidemiology of infantile hydrocephalus in Sweden. II. Origin in infants born at term. Acta Paediatr Scand. 1987 May;76(3):411-7. PMID: 2440227; X-1

348. Fleury P, Smits N, van Baal S. The incidence of hepatic hamartomas in tuberous sclerosis. Evaluation by ultrasonography. Rofo. 1987 Jun;146(6):694-6. PMID: 3037642; X-1

349. Goldsmith MM, 3rd, Strope GL, Postma DS. Presentation and management of postcricoid hemangiomata in infancy. Laryngoscope. 1987 Jul;97(7 Pt 1):851-3. PMID: 3600138; X-2

350. Govender S, Charles RW, Kelman IE. Vertebral haemangiomas. A report of 2 cases. S Afr Med J. 1987 Nov 7;72(9):640-2. PMID: 3686305; X-1

351. Govrin-Yehudain J, Moscona AR, Calderon N, et al. Treatment of hemangiomas by sclerosing agents: an experimental and clinical study. Ann Plast Surg. 1987 Jun;18(6):465-9. PMID: 3605981; X-3, X-4

352. Griffin C, DeLaPaz R, Enzmann D. Magnetic resonance appearance of slow flow vascular malformations of the brainstem. Neuroradiology. 1987;29(6):506-11. PMID: 3431693; X-1

353. Haynes R, Sobel DF, Holeman G. Cranial arteriovenous hemangioma in a neonate. AJNR Am J Neuroradiol. 1987 Sep-Oct;8(5):916-8. PMID: 3118685; X-1, X-2

354. Hendren WG, Monfort GJ. Symptomatic bilateral renal angiomyolipomas in a child. J Urol. 1987 Feb;137(2):256-7. PMID: 3806815; X-1

355. Hilborne LH, Glasgow BJ, Layfield LJ. Fine-needle aspiration cytology of juvenile hemangioma of the parotid gland: a case report. Diagn Cytopathol. 1987 Jun;3(2):152-5. PMID: 3595412; X-2

356. Jackson CG, Levine SC, McKennan KX. Hemangioma of the middle ear. Am J Otol. 1987 Mar;8(2):131-2. PMID: 3591920; X-2

357. Jones WP, Keller FS, Odrezin GT, et al. Venous hemangioma of the gallbladder. Gastrointest Radiol. 1987;12(4):319-21. PMID: 3305129; X-1, X-2

358. Kawahara M, Takeshita T, Akita S. Anesthetic management of a patient with Kasabach-Merritt syndrome. Anesth Prog. 1987 Jan-Feb;34(1):17-9. PMID: 3472474; X-1

359. Kremer I, Nissenkorn I, Feuerman P, et al. Congenital orbital vascular malformation complicated by massive retrobulbar hemorrhage. J Pediatr Ophthalmol Strabismus. 1987 Jul-Aug;24(4):190-3. PMID: 3668767; X-1

360. Larsen EC, Zinkham WH, Eggleston JC, et al. Kasabach-Merritt syndrome: therapeutic considerations. Pediatrics. 1987 Jun;79(6):971-80. PMID: 3108848; X-1

361. Leung AK. Port-wine stain associated with maternal use of lithium carbonate. J Natl Med Assoc. 1987 Aug;79(8):877-8. PMID: 3149678; X-1

362. Lofland GK, Filston HC. Giant cutaneous hemangioma associated with axillary arteriovenous fistula causing congestive heart failure in the newborn infant. J Pediatr Surg. 1987 May;22(5):458-60. PMID: 3585670; X-1, X-2

363. Magnin PH, Schroh RG, Barquin MA. Endovascular papillary angioendothelioma in children. Pediatr Dermatol. 1987 Dec;4(4):332-5. PMID: 3444784; X-1

364. Mahboubi S, Sunaryo FP, Glassman MS, et al. Computed tomography, management, and follow-up in infantile hemangioendothelioma of the liver in infants and children. J Comput Tomogr. 1987 Oct;11(4):370-5. PMID: 3443011; X-1

365. Marks MW, Argenta LC, Thornton JW. Rapid expansion: experimental and clinical experience. Clin Plast Surg. 1987 Jul;14(3):455-63. PMID: 3608355; X-1

366. Mawk JR, Leibrock LG, McComb RD, et al. Metameric capillary hemangioma producing complete myelographic block in an infant. Case report. J Neurosurg. 1987 Sep;67(3):456-9. PMID: 3612279; X-1, X-2

367. Miller JH. Technetium-99m-labeled red blood cells in the evaluation of hemangiomas of the liver in infants and children. J Nucl Med. 1987 Sep;28(9):1412-8. PMID: 3625294; X-3, X-4

368. Milner RH, Sykes PJ. Diffuse cavernous haemangiomas of the upper limb. J Hand Surg Br. 1987 Jun;12(2):199-202. PMID: 3624977; X-1

369. Narasimharao KL, Patel RV, Mitra S, et al. Mixed angioma of parotid gland simulating malignancy. Indian J Cancer. 1987 Jun;24(2):91-4. PMID: 3692533; X-1

370. Nguyen JP, Djindjian M, Gaston A, et al. Vertebral hemangiomas presenting with neurologic symptoms. Surg Neurol. 1987 Apr;27(4):391-7. PMID: 3824146; X-1

371. Nohara Y, Horiguchi H, Tsuji H, et al. Dental deformities caused by radium therapy for hemangioma of upper lip. Gifu Shika Gakkai Zasshi. 1987 Dec;14(2):426-35. PMID: 3504860; X-2

372. Osguthorpe JD, Halstead L. Invasive congenital hemangiomas of the nose. Otolaryngol Head Neck Surg. 1987 Jul;97(1):76-8. PMID: 3112690; X-1, X-2

373. Patterson RM, Maher F, Sitrin C. The prenatal sonographic visualization of a fetal calvarial capillary hemangioma. Journal of Diagnostic Medical Sonography. 1987;3(6):286-8. PMID: 1988134432; X-1, X-2

374. Plavsic B, Jereb-Provic B. Radiologic and endoscopic diagnosis of duodenal angioma. Acta Radiol. 1987 Nov-Dec;28(6):735-8. PMID: 2962610; X-1

375. Poe R, Blair PA. Hemangioma of the head and neck. J La State Med Soc. 1987 Apr;139(4):17-20. PMID: 3484323; X-1, X-2

376. Powell TG, West CR, Pharoah PO, et al. Epidemiology of strawberry haemangioma in low birthweight infants. Br J Dermatol. 1987 May;116(5):635-41. PMID: 3593631; X-3

377. Ravussin P, Bayer-Berger M, Monnier P, et al. Percutaneous transtracheal ventilation for laser endoscopic procedures in infants and small children with laryngeal obstruction: report of two cases. Can J Anaesth. 1987 Jan;34(1):83-6. PMID: 3829291; X-2

378. Ruiz-Maldonado R, Tamayo L, Laterza AM, et al. Phacomatosis pigmentovascularis: a new syndrome? Report of four cases. Pediatr Dermatol. 1987 Nov;4(3):189-96. PMID: 3422849; X-1

379. Sato Y, Frey EE, Wicklund B, et al. Embolization therapy in the management of infantile hemangioma with Kasabach Merritt syndrome. Pediatr Radiol. 1987;17(6):503-4. PMID: 3317252; X-2

380. Sauer L, Harrison MR, Bond SJ, et al. Long-term percutaneous biliary drainage in an infant with hemangioendothelioma. J Pediatr Surg. 1987 Jul;22(7):606-8. PMID: 3612453; X-1

381. Schieken LS, Brenner JI, Baker KR, et al. Aneurysm of the ascending aorta associated with sternal cleft, cutaneous hemangioma, and occlusion of the right innominate artery in a neonate. Am Heart J. 1987 Jan;113(1):202-4. PMID: 3541557; X-2

382. Schubert A, Todd MM, Luerssen TG, et al. Loss of intraoperative evoked responses during dorsal column surgery associated with isolated postoperative sensory deficit. J Clin Monit. 1987 Oct;3(4):277-81. PMID: 3681361; X-1

383. Sencer S, Coulter-Knoff A, Day D, et al. Splenic hemangioma with thrombocytopenia in a newborn. Pediatrics. 1987 Jun;79(6):960-6. PMID: 3588149; X-1

384. Shah KD, Beck AR, Jhaveri MK, et al. Infantile hemangioendothelioma of heterotopic intrathoracic liver associated with diaphragmatic hernia. Hum Pathol. 1987 Jul;18(7):754-6. PMID: 3596593; X-1

385. Shapshay SM, David LM, Zeitels S. Neodymium-YAG laser photocoagulation of hemangiomas of the head and neck. Laryngoscope. 1987 Mar;97(3 Pt 1):323-30. PMID: 3821352; X-2

386. Silver RK, Huff RW. Intrapartum management of the fetus with idiopathic hydrocephalus. Am J Perinatol. 1987 Jan;4(1):16-9. PMID: 3539132; X-1

387. Snyderman NL, Johnson JT. Salivary gland tumors. Diagnostic characteristics of the common types. Postgrad Med. 1987 Oct;82(5):105-8, 10-2. PMID: 2823241; X-1, X-2

388. Stillwell TJ, Gomez MR, Kelalis PP. Renal lesions in tuberous sclerosis. J Urol. 1987 Sep;138(3):477-81. PMID: 3625844; X-1

389. Stringel G. Giant hemangioma: treatment with intermittent pneumatic compression. J Pediatr Surg. 1987 Jan;22(1):7-10. PMID: 2950220; X-1, X-2

390. Stringel G, Dastous J. Klippel-Trenaunay syndrome and other cases of lower limb hypertrophy: pediatric surgical implications. J Pediatr Surg. 1987 Jul;22(7):645-50. PMID: 3039103; X-1

391. Suh YL, Cho KJ, Chi JG, et al. Infantile hemangioendothelioma of the liver--a case report. J Korean Med Sci. 1987 Sep;2(3):195-200. PMID: 3268177; X-1

392. Sutula FC, Glover AT. Eyelid necrosis following intralesional corticosteroid injection for capillary hemangioma. Ophthalmic Surg. 1987 Feb;18(2):103-5. PMID: 3574861; X-2

393. Tan OT, Stafford TJ. Treatment of port-wine stains at 577 nm: clinical results. Med Instrum. 1987 Aug;21(4):218-21. PMID: 3452742; X-1

394. Vaksmann G, Rey C, Marache P, et al. Severe congestive heart failure in newborns due to giant cutaneous hemangiomas. Am J Cardiol. 1987 Aug 1;60(4):392-4. PMID: 3618503; X-2

395. Vankova B, Barinka L. Haemangiomas of the tongue. Acta Chir Plast. 1987;29(4):242-8. PMID: 2449790; X-1, X-2

396. Viljoen D, Saxe N, Pearn J, et al. The cutaneous manifestations of the Klippel-Trenaunay-Weber syndrome. Clin Exp Dermatol. 1987 Jan;12(1):12-7. PMID: 2820629; X-1

397. Willshaw HE, Deady JP. Vascular hamartomas in childhood. J Pediatr Surg. 1987 Mar;22(3):281-3. PMID: 3559873; X-1

398. Woods JE. Extended use of sodium tetradecyl sulfate in treatment of hemangiomas and other related conditions. Plast Reconstr Surg. 1987 Apr;79(4):542-9. PMID: 3823245; X-1

399. Yagupsky P, Giladi Y. Group A beta-hemolytic streptococcal septicemia complicating infected hemangioma in children. Pediatr Dermatol. 1987 May;4(1):24-6. PMID: 3295826; X-2

400. Yeoman CM. Management of haemangioma involving facial, mandibular and pharyngeal structures. Br J Oral Maxillofac Surg. 1987 Jun;25(3):195-203. PMID: 3474017; X-1

401. Yoshikawa M, Hayashi T, Sato T, et al. A case of pericardial hemangioma with consumption coagulopathy cured by radiotherapy. Pediatr Radiol. 1987;17(2):149-50. PMID: 3104872; X-1, X-2

402. Alexander LJ, Moates KN. Cavernous hemangioma of the retina. J Am Optom Assoc. 1988 Jul;59(7):539-48. PMID: 3403902; X-1

403. Awaya S, Miyake S. Form vision deprivation amblyopia: further observations. Graefes Arch Clin Exp Ophthalmol. 1988;226(2):132-6. PMID: 3360338; X-1

404. Beninson J, Hurley JP. Hemolymphangioma in a neonate--a therapeutic problem--case history. Angiology. 1988 Dec;39(12):1043-7. PMID: 3189949; X-1

405. Black CT, Luck SR, Raffensperger JG. Bronchoplastic techniques for pediatric lung salvage. J Pediatr Surg. 1988 Jul;23(7):653-6. PMID: 3204465; X-1

406. Blute ML, Malek RS, Segura JW. Angiomyolipoma: clinical metamorphosis and concepts for management. J Urol. 1988 Jan;139(1):20-4. PMID: 3336097; X-1

407. Boechat MI, Kangarloo H, Ortega J, et al. Primary liver tumors in children: comparison of CT and MR imaging. Radiology. 1988 Dec;169(3):727-32. PMID: 2847233; X-1

408. Brunelle FO, Chaumont P, Teillac D, et al. Facial vascular malformations in children. Conventional and digital, diagnostic and therapeutic angiography. Pediatr Radiol. 1988;18(5):377-82. PMID: 3174277; X-1

409. Cohen EK, Kressel HY, Perosio T, et al. MR imaging of soft-tissue hemangiomas: correlation with pathologic findings. AJR Am J Roentgenol. 1988 May;150(5):1079-81. PMID: 3258709; X-1

410. Corbally MT, McMullin JP. Diffuse cavernous hemangioma of the rectosigmoid and low anterior resection using the autostapler. J Pediatr Surg. 1988 Nov;23(11):1032-3. PMID: 3244080; X-1

411. De SK, Dey DD. Tumours of the mastoid temporal bone: with interesting cases in the paediatric age group. J Laryngol Otol. 1988 Jul;102(7):582-7. PMID: 3411206; X-1

412. Droste PJ, Ellis FD, Sondhi N, et al. Linear subcutaneous fat atrophy after corticosteroid injection of periocular hemangiomas. Am J Ophthalmol. 1988 Jan 15;105(1):65-9. PMID: 3337195; X-2

413. Farmer JP, Cosgrove GR, Villemure JG, et al. Intracerebral cavernous angiomas. Neurology. 1988 Nov;38(11):1699-704. PMID: 3185904; X-1

414. Feinfield RE, Hesse RJ, Scharfenberg JC. Orbital angiolipoma. Arch Ophthalmol. 1988 Aug;106(8):1093-5. PMID: 3401137; X-1

415. Fernell E, Hagberg B, Hagberg G, et al. Epidemiology of infantile hydrocephalus in Sweden. Current aspects of the outcome in preterm infants. Neuropediatrics. 1988 Aug;19(3):143-5. PMID: 3221986; X-1

416. Fernell E, Hagberg B, Hagberg G, et al. Epidemiology of infantile hydrocephalus in Sweden: a clinical follow-up study in children born at term. Neuropediatrics. 1988 Aug;19(3):135-42. PMID: 2464773; X-1

417. Fong PH, Chan HL, Tan W. Initial experience with the argon laser in cutaneous vascular lesions. Ann Acad Med Singapore. 1988 Oct;17(4):498-501. PMID: 3223738; X-1, X-2

418. Furusaka T, Ishiyama E, Kida A, et al. Indication of cryosurgery on tonsillar diseases. Acta Otolaryngol Suppl. 1988;454:292-8. PMID: 3066107; X-1

419. Gillespie JB, Mallory SB, Kearns GL, et al. Altered gentamicin disposition in a child with a cavernous hemangioma. J Am Acad Dermatol. 1988 Nov;19(5 Pt 2):965-8. PMID: 3192781; X-1

420. Gozal D, Soudry M, Arad P, et al. Arteriovenous haemangioma of the joint capsule of the knee in a child. Eur J Pediatr. 1988 Dec;148(3):198-9. PMID: 3215195; X-1

421. Hagberg G, Fernell E, von Wendt L. Epidemiology of infantile hydrocephalus in Sweden. Reduced optimality in prepartum, partum and postpartum conditions. A case-control study. Neuropediatrics. 1988 Feb;19(1):16-23. PMID: 3362308; X-1

422. Hatzis J, Kostakis P, Tosca A, et al. Nuchal nevus flammeus as a skin marker of prognosis in alopecia areata. Dermatologica. 1988;177(3):149-51. PMID: 3169340; X-1

423. Hauben DJ. Reduction cheiloplasty for upper lip hemangioma. Plast Reconstr Surg. 1988 Oct;82(4):694-7. PMID: 3420193; X-1

424. Herter T, Brandt M, Szuwart U. Cavernous hemangiomas in children. Childs Nerv Syst. 1988 Jun;4(3):123-7. PMID: 3396017; X-1

425. Holcomb GW, 3rd, O'Neill JA, Jr., Mahboubi S, et al. Experience with hepatic hemangioendothelioma in infancy and childhood. J Pediatr Surg. 1988 Jul;23(7):661-6. PMID: 3204467; X-1

426. Holloway H, Johnson J, Sandler M. Detection of an ileal cavernous hemangioma by technetium-99m red blood cell imaging. Clin Nucl Med. 1988 Jan;13(1):32-4. PMID: 3349695; X-1

427. Imakita M, Yutani C, Ishibashi-Ueda H, et al. A case of hydrops fetalis due to placental chorioangioma. Acta Pathol Jpn. 1988 Jul;38(7):941-5. PMID: 3055811; X-1

428. Iwatsuki S, Starzl TE. Personal experience with 411 hepatic resections. Ann Surg. 1988 Oct;208(4):421-34. PMID: 3178330; X-1

429. Konior RJ, Holinger LD, Russell EJ. Superselective embolization of laryngeal hemangioma. Laryngoscope. 1988 Aug;98(8 Pt 1):830-4. PMID: 3398657; X-2

430. Lack EE, Upton MP. Histopathologic review of salivary gland tumors in childhood. Arch Otolaryngol Head Neck Surg. 1988 Aug;114(8):898-906. PMID: 2839210; X-1, X-3

431. Leonard MP, Nickel JC, Morales A. Cavernous hemangiomas of the bladder in the pediatric age group. J Urol. 1988 Dec;140(6):1503-4. PMID: 3057231; X-1

432. Leung AK, Lowry RB, Mitchell I, et al. Klippel-Trenaunay and Sturge-Weber syndrome with extensive Mongolian spots, hypoplastic larynx and subglottic stenosis. Clin Exp Dermatol. 1988 Mar;13(2):128-32. PMID: 2850877; X-1

433. Levin AV, Selbst SM. Vulvar hemangioma simulating child abuse. Clin Pediatr (Phila). 1988 Apr;27(4):213-5. PMID: 3349732; X-1, X-2

434. Levy I, Danziger Y, Mechlis-Frish S, et al. Technetium-labeled red blood cell imaging to evaluate soft tissue hemangioma of the hand. Pediatr Dermatol. 1988 Feb;5(1):47-9. PMID: 2837746; X-1

435. Liu HC, Chang MH, Lue HC, et al. Hepatic hemangioma in infancy and early childhood. Taiwan Yi Xue Hui Za Zhi. 1988 Mar;87(3):288-96. PMID: 3397726; X-1

436. Loh W, Jr., Miller JH, Gomperts ED. Imaging with technetium 99m-labeled erythrocytes in evaluation of the Kasabach-Merritt syndrome. J Pediatr. 1988 Nov;113(5):856-9. PMID: 3183843; X-1

437. Malm M, Jurell G, Glas JE. Argon laser treatment of port wine stain. Scand J Plast Reconstr Surg Hand Surg. 1988;22(3):245-8. PMID: 3252454; X-1

438. Maruiwa M, Nakamura Y, Motomura K, et al. Cornelia de Lange syndrome associated with Wilms' tumour and infantile haemangioendothelioma of the liver: report of two autopsy cases. Virchows Arch A Pathol Anat Histopathol. 1988;413(5):463-8. PMID: 2845644; X-1

439. Mastroiacovo P, Spagnolo A, Marni E, et al. Birth defects in the Seveso area after TCDD contamination. Jama. 1988 Mar 18;259(11):1668-72. PMID: 3343773; X-1

440. Michaud LJ, Jaffe KM, Benjamin DR, et al. Hemangioblastoma of the conus medullaris associated with cutaneous hemangioma. Pediatr Neurol. 1988 Sep-Oct;4(5):309-12. PMID: 3242536; X-1

441. Monnier PH, Ravussin P, Savary M, et al. Percutaneous transtracheal ventilation for laser endoscopic treatment of laryngeal and subglottic lesions. Clin Otolaryngol Allied Sci. 1988 Jun;13(3):209-17. PMID: 3402098; X-1, X-2

442. Myer CM, 3rd, Miller R, Gray S. Nasal presentation of an intracranial vascular anomaly. Int J Pediatr Otorhinolaryngol. 1988 May;15(2):221-5. PMID: 3397243; X-1

443. Narasimharao KL, Kaushik S, Malik AK, et al. Tongue hemangiomas. Indian Pediatr. 1988 Jan;25(1):92-4. PMID: 3220530; X-2

444. Nuutinen EM, Puistola U, Herva R, et al. Two cases of large placental chorioangioma with fetal and neonatal complications. Eur J Obstet Gynecol Reprod Biol. 1988 Dec;29(4):315-20. PMID: 2976380; X-1

445. Occhiogrosso M, Spada A, Vailati G. Forth ventricle hematoma in a eight-year-old child. J Neurosurg Sci. 1988 Apr-Jun;32(2):87-9. PMID: 3199216; X-1

446. Ogita S, Tsuto T, Deguchi E, et al. Giant cavernous haemangioma: treatment with intralesional injection of OK-432. Z Kinderchir. 1988 Dec;43(6):408-9. PMID: 3239253; X-1

447. Plowman PN, Harnett AN. Radiotherapy in benign orbital disease. I: Complicated ocular angiomas. Br J Ophthalmol. 1988 Apr;72(4):286-8. PMID: 3378026; X-1, X-2

448. Qureshi SA, Gregg JE, Galloway RW. Computed tomographic appearances of massive neonatal hemangioma of the liver: a case report. J Comput Tomogr. 1988 Apr;12(2):135-7. PMID: 3168523; X-1, X-2

449. Ranne RD, Ashcraft KW, Holder TM, et al. Hepatic hemangioma: resection using hypothermic circulatory arrest in the newborn. J Pediatr Surg. 1988 Oct;23(10):924-6. PMID: 3236162; X-1

450. Rappaport ZH. Corpus callosum section in the treatment of intractable seizures in the Sturge-Weber syndrome. Childs Nerv Syst. 1988 Aug;4(4):231-2. PMID: 3167877; X-1

451. Rizzo R, Micali G, Incorpora G, et al. A very aggressive form of facial hemangioma. Pediatr Dermatol. 1988 Nov;5(4):263-5. PMID: 3231585; X-1, X-2

452. Sato SE, Herschler J, Lynch PJ, et al. Congenital glaucoma associated with cutis marmorata telangiectatica congenita: two case reports. J Pediatr Ophthalmol Strabismus. 1988 Jan-Feb;25(1):13-7. PMID: 3343635; X-1

453. Scott GA, Rosai J. Spindle cell hemangioendothelioma. Report of seven additional cases of a recently described vascular neoplasm. Am J Dermatopathol. 1988 Aug;10(4):281-8. PMID: 2458050; X-1

454. Shorr N, Goldberg RA, David LM. Laser treatment of juvenile hemangioma. Ophthal Plast Reconstr Surg. 1988;4(3):131-4. PMID: 3154730; X-2

455. Soberman MS, Plauth WH, Winn KJ, et al. Hemangioma of the right ventricle causing outflow tract obstruction. J Thorac Cardiovasc Surg. 1988 Aug;96(2):307-9. PMID: 3398552; X-1, X-2

456. Srinivas CR, Rao PL. Sudoriparous angioma--regression following intravascular aethoxysclerol, a sclerosing agent. Br J Dermatol. 1988 Jul;119(1):111-3. PMID: 3408654; X-1

457. Taratuto AL, Zurbriggen G, Sevlever G, et al. Epithelioid hemangioendothelioma of the central nervous system. Immunohistochemical and ultrastructural observations of a pediatric case. Pediatr Neurosci. 1988;14(1):11-4. PMID: 3217280; X-1

458. Tolmie JL, Browne BH, McGettrick PM, et al. A familial syndrome with coats' reaction retinal angiomas, hair and nail defects and intracranial calcification. Eye (Lond). 1988;2 (Pt 3):297-303. PMID: 3402627; X-1

459. Totsuka Y, Fukuda H, Tomita K. Compression therapy for parotid haemangioma in infants. A report of three cases. J Craniomaxillofac Surg. 1988 Nov;16(8):366-70. PMID: 3204160; X-2

460. Vaillant L, Lorette G, Chantepie A, et al. Multiple cutaneous hemangiomas and coarctation of the aorta with right aortic arch. Pediatrics. 1988 May;81(5):707-10. PMID: 3357730; X-2

461. Vellodi A, Bini RM. Malignant ventricular arrhythmias caused by hyperkalaemia complicating the Kasabach-Merritt syndrome. J R Soc Med. 1988 Mar;81(3):167-8. PMID: 3357160; X-1

462. Wagner RS, Caputo AR, Del Negro RG, et al. Trabeculectomy with cyclocryotherapy for infantile glaucoma in the Sturge-Weber syndrome. Ann Ophthalmol. 1988 Aug;20(8):289-91, 95. PMID: 3190106; X-1

463. Weir MR. Atypical idiopathic hypercalciuria in an adolescent. J Adolesc Health Care. 1988 Nov;9(6):498-500. PMID: 3182367; X-1

464. Weiss SW. Pedal hemangioma (venous malformation) occurring in Turner's syndrome: an additional manifestation of the syndrome. Hum Pathol. 1988 Sep;19(9):1015-8. PMID: 3417285; X-1

465. Wenig BL, Abramson AL. Congenital subglottic hemangiomas: a treatment update. Laryngoscope. 1988 Feb;98(2):190-2. PMID: 3123827; X-4

466. Wick MR, Rocamora A. Reactive and malignant "angioendotheliomatosis": a discriminant clinicopathological study. J Cutan Pathol. 1988 Oct;15(5):260-71. PMID: 3209761; X-1

467. Wright JE. Doyne Lecture: Current concepts in orbital disease. Eye (Lond). 1988;2 (Pt 1):1-11. PMID: 3044844; X-1, X-2

468. Yamaguchi K, Yamaguchi K, Tamai M. Cavernous hemangioma of the retina in a pediatric patient. Ophthalmologica. 1988;197(3):127-9. PMID: 3231418; X-1

469. Albright AL, Gartner JC, Wiener ES. Lumbar cutaneous hemangiomas as indicators of tethered spinal cords. Pediatrics. 1989 Jun;83(6):977-80. PMID: 2657627; X-3, X-4

470. Anand R, Augsburger JJ, Shields JA. Circumscribed choroidal hemangiomas. Arch Ophthalmol. 1989 Sep;107(9):1338-42. PMID: 2783066; X-1

471. Apfelberg DB, Maser MR, Lash H, et al. Sapphire tip technology for YAG laser excisions in plastic surgery. Plast Reconstr Surg. 1989 Aug;84(2):273-9. PMID: 2748740; X-1

472. Apfelberg DB, Maser MR, White DN, et al. A preliminary study of the combined effect of neodymium: YAG laser photocoagulation and direct steroid instillation in the treatment of capillary/cavernous hemangiomas of infancy. Ann Plast Surg. 1989 Feb;22(2):94-104. PMID: 2735715; X-4

473. Augsburger JJ. Birthmarks of the eye and eyelids as indicators of ocular or systemic tumors. J Ophthalmic Nurs Technol. 1989 Sep-Oct;8(5):197-202. PMID: 2795670; X-1

474. Azmy AF, Stephenson J, Ziervogel M. Angiomyolipoma causing life-threatening hematuria in a child with tuberous sclerosis. J Pediatr Surg. 1989 Dec;24(12):1308-9. PMID: 2593064; X-1

475. Brooks M. Small bowel volvulus, mesenteric band, cavernous haemangioma, and failure to thrive. Scott Med J. 1989 Oct;34(5):535-6. PMID: 2587983; X-1

476. Buckingham MJ, Crone KR, Ball WS, et al. Management of cerebral cavernous angiomas in children presenting with seizures. Childs Nerv Syst. 1989 Dec;5(6):347-9. PMID: 2611768; X-1

477. Casale AJ, Menashe DS. Massive strawberry hemangioma of the male genitalia. J Urol. 1989 Mar;141(3):593-4. PMID: 2918599; X-2

478. Castle VP, Shulkin BL, Coates G, et al. The use of indium-111 oxine platelet scintigraphy and survival studies in pediatric patients with thrombocytopenia. J Nucl Med. 1989 Nov;30(11):1819-24. PMID: 2509647; X-1, X-3

479. Chiron C, Raynaud C, Tzourio N, et al. Regional cerebral blood flow by SPECT imaging in Sturge-Weber disease: an aid for diagnosis. J Neurol Neurosurg Psychiatry. 1989 Dec;52(12):1402-9. PMID: 2614436; X-1

480. Cogen MS, Elsas FJ. Eyelid depigmentation following corticosteroid injection for infantile ocular adnexal hemangioma. J Pediatr Ophthalmol Strabismus. 1989 Jan-Feb;26(1):35-8. PMID: 2915311; X-2

481. Colombo F, Benedetti A, Pozza F, et al. Linear accelerator radiosurgery of cerebral arteriovenous malformations. Neurosurgery. 1989 Jun;24(6):833-40. PMID: 2664545; X-1

482. Corboy JR, Galetta SL. Familial cavernous angiomas manifesting with an acute chiasmal syndrome. Am J Ophthalmol. 1989 Sep 15;108(3):245-50. PMID: 2774032; X-1

483. Cornelius AS, Womer RB, Jakacki R. Multiple hemangioendotheliomas of the liver. Med Pediatr Oncol. 1989;17(6):501-4. PMID: 2586364; X-1

484. de Keizer RJ, Scheffer E. Masquerade of eyelid tumours. Doc Ophthalmol. 1989 Aug;72(3-4):309-21. PMID: 2625092; X-1

485. Ferrante L, Acqui M, d'Addetta R, et al. Neuroradiological findings in cavernous hemangioma. An analysis of 15 cases. Zentralbl Neurochir. 1989;50(3-4):184-7. PMID: 2642237; X-1

486. Fradis M, Podoshin L, Simon J, et al. Combined treatment of large head and neck capillaro-venous malformation by a fibrosing agent. J Laryngol Otol. 1989 Apr;103(4):390-8. PMID: 2715693; X-1

487. Frima-Verhoeven PA, Op de Coul AA, Tijssen CC, et al. Intracranial cavernous angiomas: diagnosis and therapy. Eur Neurol. 1989;29(1):56-60. PMID: 2707292; X-1

488. Furst CJ, Lundell M, Ahlback SO, et al. Breast hypoplasia following irradiation of the female breast in infancy and early childhood. Acta Oncol. 1989;28(4):519-23. PMID: 2789829; X-3

489. Furst CJ, Silfversward C, Holm LE. Mortality in a cohort of radiation treated childhood skin hemangiomas. Acta Oncol. 1989;28(6):789-94. PMID: 2611031; X-3

490. Gangemi M, Longatti P, Maiuri F, et al. Cerebral cavernous angiomas in the first year of life. Neurosurgery. 1989 Sep;25(3):465-8; discussion 8-9. PMID: 2771019; X-1

491. Glassberg E, Lask G, Rabinowitz LG, et al. Capillary hemangiomas: case study of a novel laser treatment and a review of therapeutic options. J Dermatol Surg Oncol. 1989 Nov;15(11):1214-23. PMID: 2808890; X-1, X-2

492. Goldberg DJ. Laser surgery of the skin. Am Fam Physician. 1989 Nov;40(5):109-16. PMID: 2510483; X-1

493. Gonen R, Fong K, Chiasson DA. Prenatal sonographic diagnosis of hepatic hemangioendothelioma with secondary nonimmune hydrops fetalis. Obstet Gynecol. 1989 Mar;73(3 Pt 2):485-7. PMID: 2644601; X-1

494. Hanna BD, Bernstein M. Tranexamic acid in the treatment of Kasabach-Merritt syndrome in infants. Am J Pediatr Hematol Oncol. 1989 Summer;11(2):191-5. PMID: 2751074; X-1, X-2

495. Ito H, Yamasaki T, Okamoto O, et al. Infantile hemangioendothelioma of the liver in patient with interstitial deletion of chromosome 6q: report of an autopsy case. Am J Med Genet. 1989 Nov;34(3):325-9. PMID: 2596522; X-1

496. Ito M, Sato K, Maruki C, et al. Surgical treatment of Sturge-Weber syndrome--case report. Neurol Med Chir (Tokyo). 1989 Jan;29(1):60-4. PMID: 2472571; X-1

497. Korn EL, Goodrich S. Use of the carbon dioxide laser to remove an eyelid hemangioma. Ophthalmic Surg. 1989 Dec;20(12):887-8. PMID: 2517140; X-2

498. Kristal H, Sperber F. Hepatic angiomyolipoma in a tuberous sclerosis patient. Isr J Med Sci. 1989 Jul;25(7):412-4. PMID: 2668223; X-1

499. Kushner BJ, Meyers FL. Good visual outcome after endophthalmitis in an eye previously treated successfully for amblyopia. J Pediatr Ophthalmol Strabismus. 1989 Mar-Apr;26(2):69-71. PMID: 2785175; X-1, X-2

500. Lanigan SW, Cartwright P, Cotterill JA. Continuous wave dye laser therapy of port wine stains. Br J Dermatol. 1989 Sep;121(3):345-52. PMID: 2803960; X-1

501. Leary DL, Weiskittel DA, Blane CE, et al. Follow-up imaging of benign pediatric liver tumors. Pediatr Radiol. 1989;19(4):234-6. PMID: 2546119; X-1

502. Luukkonen P, Jarvinen HJ, Rintala R. Colo-anal sleeve resection for rectal hemangioma. Case report. Acta Chir Scand. 1989 Nov-Dec;155(11-12):613-6. PMID: 2618519; X-1

503. Machin GA, Kent S. Pulmonary thromboembolism from a large hemangioma in a 4-week-old infant. Pediatr Pathol. 1989;9(1):73-8. PMID: 2717500; X-1, X-2

504. Mallory SB, Morris P. Bleeding hemangioma detected by enuresis blanket. Pediatr Dermatol. 1989 Jun;6(2):139-40. PMID: 2748474; X-2

505. Mulder JJ, van den Broek P. Surgical treatment of infantile subglottic hemangioma. Int J Pediatr Otorhinolaryngol. 1989 Feb;17(1):57-63. PMID: 2707979; X-2

506. Narbone MC, D'Amico D, Bramanti P, et al. Bilateral cortical calcifications with benign clinical course: an unusual case of Sturge-Weber syndrome? Acta Neurol (Napoli). 1989 Dec;11(6):423-7. PMID: 2618827; X-1

507. Niedt GW, Greco MA, Wieczorek R, et al. Hemangioma with Kaposi's sarcoma-like features: report of two cases. Pediatr Pathol. 1989;9(5):567-75. PMID: 2813203; X-1

508. Nishio A, Sakaguchi M, Murata K, et al. Lateral situated sinus pericranii. Case report. Surg Neurol. 1989 Nov;32(5):382-6. PMID: 2814792; X-1

509. Ogunmekan AO, Hwang PA, Hoffman HJ. Sturge-Weber-Dimitri disease: role of hemispherectomy in prognosis. Can J Neurol Sci. 1989 Feb;16(1):78-80. PMID: 2924212; X-1

510. Ozsoylu S, Irken G, Gurgey A. High dose intravenous methylprednisolone for Kassabach-Merritt syndrome. Eur J Pediatr. 1989 Feb;148(5):403-5. PMID: 2920745; X-1, X-2

511. Picci P, Sudanese A, Greggi T, et al. Intramuscular hemangioma in infancy: diagnostic and therapeutic considerations. J Pediatr Orthop. 1989 Jan-Feb;9(1):72-5. PMID: 2915042; X-2

512. Remacle M, Declaye X, Mayne A. Subglottic haemangioma in the infant: contribution by CO2 laser. J Laryngol Otol. 1989 Oct;103(10):930-4. PMID: 2511264; X-3, X-4

513. Reyes BA, Vazquez-Botet M, Capo H. Intralesional steroids in cutaneous hemangioma. J Dermatol Surg Oncol. 1989 Aug;15(8):828-32. PMID: 2754087; X-2

514. Sadan N, Horowitz I, Choc L, et al. Giant hemangioma with thrombocytopenia and osteolysis successfully treated with prednisone. J Pediatr Orthop. 1989 Jul-Aug;9(4):472-5. PMID: 2732330; X-1, X-2

515. Seifert V, Trost HA, Dietz H. Cavernous angiomas of the supratentorial compartment. Zentralbl Neurochir. 1989;50(2):89-92. PMID: 2516390; X-1

516. Skopec LL, Lakatua DJ. Non-immune fetal hydrops with hepatic hemangioendothelioma and Kasabach-Merritt syndrome: a case report. Pediatr Pathol. 1989;9(1):87-93. PMID: 2717502; X-1

517. Smith MB, Hardin WD, Jr., Moynihan PC. Differentiation and treatment of hemangiomas and arteriovenous malformations. J La State Med Soc. 1989 Jun;141(6):41-3. PMID: 2732611; X-1, X-2

518. Staindl O. Treatment of hemangiomas of the face with magnesium seeds. Arch Otorhinolaryngol. 1989;246(4):213-7. PMID: 2597082; X-3, X-4

519. Stanley P, Geer GD, Miller JH, et al. Infantile hepatic hemangiomas. Clinical features, radiologic investigations, and treatment of 20 patients. Cancer. 1989 Aug 15;64(4):936-49. PMID: 2663135; X-4

520. Suen JY, Waner M. Treatment of oral cavity vascular malformations using the neodymium:YAG laser. Arch Otolaryngol Head Neck Surg. 1989 Nov;115(11):1329-33. PMID: 2553074; X-1, X-2

521. Tan OT, Sherwood K, Gilchrest BA. Treatment of children with port-wine stains using the flashlamp-pulsed tunable dye laser. N Engl J Med. 1989 Feb 16;320(7):416-21. PMID: 2913507; X-1

522. Taylor RS, Joseph DB, Kohaut EC, et al. Renal angiomyolipoma associated with lymph node involvement and renal cell carcinoma in patients with tuberous sclerosis. J Urol. 1989 Apr;141(4):930-2. PMID: 2926893; X-1

523. Trussart V, Berry I, Manelfe C, et al. Epileptogenic cerebral vascular malformations and MRI. J Neuroradiol. 1989 Dec;16(4):273-84. PMID: 2638394; X-1

524. van Baal JG, Fleury P, Brummelkamp WH. Tuberous sclerosis and the relation with renal angiomyolipoma. A genetic study on the clinical aspects. Clin Genet. 1989 Mar;35(3):167-73. PMID: 2706800; X-1

525. Vazquez-Botet R, Reyes BA, Vazquez-Botet M. Sclerodermiform linear atrophy after the use of intralesional steroids for periorbital hemangiomas: a review of complications. J Pediatr Ophthalmol Strabismus. 1989 May-Jun;26(3):124-7. PMID: 2723973; X-2

526. Walker EP, Butler PH, Pickering JW, et al. Histology of port wine stains after copper vapour laser treatment. Br J Dermatol. 1989 Aug;121(2):217-23. PMID: 2775646; X-1

527. Weiss AH. Adrenal suppression after corticosteroid injection of periocular hemangiomas. Am J Ophthalmol. 1989 May 15;107(5):518-22. PMID: 2540659; X-4

528. White CW, Sondheimer HM, Crouch EC, et al. Treatment of pulmonary hemangiomatosis with recombinant interferon alfa-2a. N Engl J Med. 1989 May 4;320(18):1197-200. PMID: 2710192; X-1

529. Yeoman LJ, Shaw D. Computerized tomography appearances of pelvic haemangioma involving the large bowel in childhood. Pediatr Radiol. 1989;19(6-7):414-6. PMID: 2771480; X-1, X-2

530. Achauer BM, Vander Kam VM, Miller SR. Clinical experience with the pulsed-dye laser in the treatment of capillary malformations (port-wine stains): a preliminary report. Ann Plast Surg. 1990 Nov;25(5):344-52. PMID: 2256647; X-1

531. Adam YG, Alberts W. Retroperitoneal hemangioma. Am Surg. 1990 Jun;56(6):374-6. PMID: 1972007; X-2

532. Aguirre Vila-Coro A, Dominguez R, Calk JB, et al. Congenital generalized fibromatosis. Ann Ophthalmol (Skokie). 1990 Jun;22(6):217-21. PMID: X-1

533. Akashi S, Motizuki H. Screening for hypercalciuria. Acta Paediatr Jpn. 1990 Dec;32(6):701-9. PMID: 2082673; X-1

534. Ali MA, Fahmy IA, Spaeth GL. Trabeculectomy for glaucoma associated with Sturge-Weber syndrome. Ophthalmic Surg. 1990 May;21(5):352-5. PMID: 2381658; X-1

535. Apfelberg DB, Maser MR, Lash H, et al. YAG laser resection of complicated hemangiomas of the hand and upper extremity. J Hand Surg Am. 1990 Sep;15(5):765-73. PMID: 2229976; X-1

536. Apfelberg DB, Maser MR, White DN, et al. Benefits of contact and noncontact YAG laser for periorbital hemangiomas. Ann Plast Surg. 1990 May;24(5):397-408. PMID: 2350150; X-1

537. Apfelberg DB, Maser MR, White DN, et al. Combination treatment for massive cavernous hemangioma of the face: YAG laser photocoagulation plus direct steroid injection followed by YAG laser resection with sapphire scalpel tips, aided by superselective embolization. Lasers Surg Med. 1990;10(3):217-23. PMID: 2345471; X-1

538. Ashinoff R, Geronemus RG. Effect of the topical anesthetic EMLA on the efficacy of pulsed dye laser treatment of port-wine stains. J Dermatol Surg Oncol. 1990 Nov;16(11):1008-11. PMID: 2246405; X-1

539. Asthana AK, Tandon SC, Pant GC, et al. Radiation therapy for symptomatic vertebral haemangioma. Clin Oncol (R Coll Radiol). 1990 May;2(3):159-62. PMID: 2261405; X-1

540. Aylett SE, Williams AF, Bevan DH, et al. The Kasabach-Merritt syndrome: treatment with intermittent pneumatic compression. Arch Dis Child. 1990 Jul;65(7):790-1. PMID: 2386388; X-1

541. Bandoh Y, Yanai A, Tsuzuki K. Dye laser treatment of port-wine stains. Aesthetic Plast Surg. 1990 Fall;14(4):287-91. PMID: 2239519; X-1

542. Basaklar AC. Haemangiomas of the gastrointestinal tract in children. Z Kinderchir. 1990 Apr;45(2):114-6. PMID: 2360368; X-1

543. Blodi CF, Russell SR, Pulido JS, et al. Direct and feeder vessel photocoagulation of retinal angiomas with dye yellow laser. Ophthalmology. 1990 Jun;97(6):791-5; discussion 6-7. PMID: 2374684; X-1

544. Bottoni F, Canevini MP, Canger R, et al. Twin vessels in familial retinal cavernous hemangioma. Am J Ophthalmol. 1990 Mar 15;109(3):285-9. PMID: 2309859; X-1

545. Bowyer JJ, Sheppard M. Capillary haemangioma presenting as a lung pseudocyst. Arch Dis Child. 1990 Oct;65(10):1162-4. PMID: 2248511; X-1, X-2

546. Brocheler J, Thron A. Intracranial arterial aneurysms in children. Clinical, neuroradiological and histological findings. Neurosurg Rev. 1990;13(4):309-13. PMID: 2280842; X-1

547. Casey WF, Rice LJ, Hannallah RS, et al. A comparison between bupivacaine instillation versus ilioinguinal/iliohypogastric nerve block for postoperative analgesia following inguinal herniorrhaphy in children. Anesthesiology. 1990 Apr;72(4):637-9. PMID: 2321781; X-1

548. Chazotte C, Girz B, Koenigsberg M, et al. Spontaneous infarction of placental chorioangioma and associated regression of hydrops fetalis. Am J Obstet Gynecol. 1990 Oct;163(4 Pt 1):1180-1. PMID: 2220924; X-1

549. Costello SA, Seywright M. Postirradiation malignant transformation in benign haemangioma. Eur J Surg Oncol. 1990 Dec;16(6):517-9. PMID: 2253799; X-1

550. Dabashi Y, Eisen RN. Infantile hemangioendothelioma of the pelvis associated with Kasabach-Merritt syndrome. Pediatr Pathol. 1990;10(3):407-15. PMID: 2349157; X-1

551. Davenport M, Salisbury J, Karani J, et al. Retroperitoneal haemangiolymphangioma presenting with projectile vomiting and thrombocytopaenia at 2 weeks of age. J R Soc Med. 1990 Sep;83(9):591-2. PMID: 2213812; X-1

552. Dawson MH. Tuberous sclerosis. J La State Med Soc. 1990 Mar;142(3):35-8. PMID: 2319202; X-1

553. Diwan R. Laser therapy in the treatment of congenital vascular abnormalities. Md Med J. 1990 Apr;39(4):343-6. PMID: 2333019; X-1

554. Edwards WH, Jr., Sawyers JL, Adkins RB, Jr. Major hepatic resection: an update. South Med J. 1990 Jan;83(1):18-22. PMID: 2154037; X-1

555. Enjolras O, Riche MC, Merland JJ, et al. Management of alarming hemangiomas in infancy: a review of 25 cases. Pediatrics. 1990 Apr;85(4):491-8. PMID: 2097998; X-3, X-4

556. Epstein MA, Berman PH, Schut L. Cavernous angioma presenting as atypical facial and head pain. J Child Neurol. 1990 Jan;5(1):27-30. PMID: 2299136; X-1

557. Epstein RH, Brummett RR, Jr., Lask GP. Incendiary potential of the flash-lamp pumped 585-nm tunable dye laser. Anesth Analg. 1990 Aug;71(2):171-5. PMID: 2375518; X-1

558. Fernell E, Hagberg G, Hagberg B. Infantile hydrocephalus--the impact of enhanced preterm survival. Acta Paediatr Scand. 1990 Nov;79(11):1080-6. PMID: 2267927; X-1

559. Fivush B. Irritability and dysuria in infants with idiopathic hypercalciuria. Pediatr Nephrol. 1990 May;4(3):262-3. PMID: 2133372; X-1

560. Ford MD, Codere F. Perilymphatic subcutaneous atrophy in adnexal hemangioma: a complication of intralesional corticosteroid injection. Ophthalmic Surg. 1990 Mar;21(3):215-7. PMID: 2348971; X-2

561. Franca-Martins AM, Graubard Z, Holloway GA, et al. Placental haemangioma associated with acute fetal anemia in labour. Acta Med Port. 1990 May-Jun;3(3):187-9. PMID: 2220431; X-1

562. Franks R, Rothera M. Cardiopulmonary bypass for resection of low tracheal haemangioma. Arch Dis Child. 1990 Jun;65(6):630-2. PMID: 2378524; X-2

563. Friedman EM, Vastola AP, McGill TJ, et al. Chronic pediatric stridor: etiology and outcome. Laryngoscope. 1990 Mar;100(3):277-80. PMID: 2308452; X-3, X-4

564. Furst CJ, Lundell M, Holm LE. Tumors after radiotherapy for skin hemangioma in childhood. A case-control study. Acta Oncol. 1990;29(5):557-62. PMID: 2206565; X-3

565. Gangemi M, Maiuri F, Donati P, et al. Familial cerebral cavernous angiomas. Neurol Res. 1990 Sep;12(3):131-6. PMID: 1979841; X-1

566. Gaspar L, Szabo G. Manifestation of the advantages and disadvantages of using the CO2 laser in oral surgery. J Clin Laser Med Surg. 1990 Feb;8(1):39-43. PMID: 10148946; X-3, X-4

567. Goldstein MH. The elastic flap: an expanding vermilion myocutaneous flap for lip repairs. Facial Plast Surg. 1990;7(2):119-25. PMID: 2132232; X-1, X-2

568. Gozal D, Saad N, Bader D, et al. Diffuse neonatal haemangiomatosis: successful management with high dose corticosteroids. Eur J Pediatr. 1990 Feb;149(5):321-4. PMID: 2311628; X-1

569. Greene LA, Freedman PD, Friedman JM, et al. Capillary hemangioma of the maxilla. A report of two cases in which angiography and embolization were used. Oral Surg Oral Med Oral Pathol. 1990 Sep;70(3):268-73. PMID: 2216353; X-1

570. Gunes HA, Egilmez R, Dulger M. Ovarian haemangioma. Br J Clin Pract. 1990 Dec;44(12):734-5. PMID: 2102218; X-1, X-2

571. Hamvas A, Perlman JM, Volpe JJ. Brain death secondary to arteriovenous hemangioma of the forearm. Pediatr Neurol. 1990 Jan-Feb;6(1):63-4. PMID: 2310440; X-1, X-2

572. Hardy PA, Kucharczyk W, Henkelman RM. Cause of signal loss in MR images of old hemorrhagic lesions. Radiology. 1990 Feb;174(2):549-55. PMID: 2296664; X-1

573. Heffez DS, Zinreich SJ, Long DM. Surgical resection of intrinsic brain stem lesions: an overview. Neurosurgery. 1990 Nov;27(5):789-97; discussion 97-8. PMID: 2259410; X-1

574. Held JL, Haber RS, Silvers DN, et al. Benign neonatal hemangiomatosis: review and description of a patient with unusually persistent lesions. Pediatr Dermatol. 1990 Mar;7(1):63-6. PMID: 2343009; X-1

575. Hofhuis WJ, Oranje AP, Bouquet J, et al. Blue rubber-bleb naevus syndrome: report of a case with consumption coagulopathy complicated by manifest thrombosis. Eur J Pediatr. 1990 May;149(8):526-8. PMID: 2347349; X-1

576. Ikeda DM, Caron KH, Faison JD. Term infant with progressive tachypnea. Invest Radiol. 1990 Jan;25(1):79-81. PMID: 2298554; X-1, X-2

577. Ito M, Sato K, Ohnuki A, et al. Sturge-Weber disease: operative indications and surgical results. Brain Dev. 1990;12(5):473-7. PMID: 2288377; X-1

578. Iwach AG, Hoskins HD, Jr., Hetherington J, Jr., et al. Analysis of surgical and medical management of glaucoma in Sturge-Weber syndrome. Ophthalmology. 1990 Jul;97(7):904-9. PMID: 2381705; X-1

579. Iwatsuki S, Todo S, Starzl TE. Excisional therapy for benign hepatic lesions. Surg Gynecol Obstet. 1990 Sep;171(3):240-6. PMID: 1696751; X-1

580. Jeter TS, Hackney FL, Aufdemorte TB. Cavernous hemangioma of the zygoma: report of cases. J Oral Maxillofac Surg. 1990 May;48(5):508-12. PMID: 2329401; X-1, X-2

581. Kaplan P, Normandin J, Jr., Wilson GN, et al. Malformations and minor anomalies in children whose mothers had prenatal diagnosis: comparison between CVS and amniocentesis. Am J Med Genet. 1990 Nov;37(3):366-70. PMID: 2260567; X-1

582. Kodachi K, Kojima T, Shimbashi T, et al. Hemangioma of the fingers. Handchir Mikrochir Plast Chir. 1990 Jan;22(1):49-52. PMID: 2311997; X-1, X-2

583. Koivu MK, Nuutinen EM. Large placental chorioangioma as a cause of congestive heart failure in newborn infants. Pediatr Cardiol. 1990 Oct;11(4):221-4. PMID: 2274453; X-1

584. Lanigan SW, Cotterill JA. The treatment of port wine stains with the carbon dioxide laser. Br J Dermatol. 1990 Aug;123(2):229-35. PMID: 2119215; X-1

585. Leighton DM, Benghanem T, Montagne JP, et al. A case of rectal bleeding in infancy. Australas Radiol. 1990 Feb;34(1):89-90. PMID: 2357199; X-1, X-2

586. Lieb WE, Shields JA, Cohen SM, et al. Color Doppler imaging in the management of intraocular tumors. Ophthalmology. 1990 Dec;97(12):1660-4. PMID: 2087296; X-1

587. Lundell M, Furst CJ, Hedlund B, et al. Radium treatment for hemangioma in early childhood. Reconstruction and dosimetry of treatments, 1920-1959. Acta Oncol. 1990;29(5):551-6. PMID: 2206564; X-3

588. Luthringer DJ, Virmani R, Weiss SW, et al. A distinctive cardiovascular lesion resembling histiocytoid (epithelioid) hemangioma. Evidence suggesting mesothelial participation. Am J Surg Pathol. 1990 Nov;14(11):993-1000. PMID: 2240358; X-1

589. Malone PS, Kiely EM, Spitz L. Diffuse cavernous haemangioma of the rectum in childhood. Br J Surg. 1990 Mar;77(3):338-9. PMID: 2322806; X-1

590. McShane MA, Finn JP, Hall-Craggs MA, et al. Neonatal hemangiomatosis presenting as infantile spasms. Neuropediatrics. 1990 Nov;21(4):211-2. PMID: 2290483; X-1

591. Meeuwis J, Bos CE, Hoeve LJ, et al. Subglottic hemangiomas in infants: treatment with intralesional corticosteroid injection and intubation. Int J Pediatr Otorhinolaryngol. 1990 Jun;19(2):145-50. PMID: 2373598; X-4

592. Montgomery SP, Guillot AP, Barth RA. MRI of disseminated neonatal hemangiomatosis: case report. Pediatr Radiol. 1990;20(3):204-5. PMID: 2352803; X-1

593. Morgan DW, Evans JN. Developmental nasal anomalies. J Laryngol Otol. 1990 May;104(5):394-403. PMID: 2370465; X-3, X-4

594. Mucitelli DR, Charles EZ, Kraus FT. Chorioangiomas of intermediate size and intrauterine growth retardation. Pathol Res Pract. 1990 Aug;186(4):455-8. PMID: 2247373; X-1

595. Ochi JW, Kearns DB, Seid AB, et al. Do angiomas of the nasal septum exist? Int J Pediatr Otorhinolaryngol. 1990 Jun;19(2):169-73. PMID: 2165038; X-1, X-2

596. Oi S, Matsumoto S, Choi JU, et al. Brain tumors diagnosed in the first year of life in five Far-Eastern countries. Statistical analysis of 307 cases. Childs Nerv Syst. 1990 Mar;6(2):79-85. PMID: 2340533; X-1

597. Paes EH, Vollmar JF. Aneurysma transformation in congenital venous angiodysplasias in lower extremities. Int Angiol. 1990 Apr-Jun;9(2):90-6. PMID: 2174953; X-1

598. Pickering JW, Walker EP, Butler PH, et al. Copper vapour laser treatment of port-wine stains and other vascular malformations. Br J Plast Surg. 1990 May;43(3):273-82. PMID: 2350632; X-1

599. Poirier VC, Ablin DS, Frank EH. Diffuse neonatal hemangiomatosis: a case report. AJNR Am J Neuroradiol. 1990 Nov-Dec;11(6):1097-9. PMID: 2124035; X-1

600. Powars D, Adams RJ, Nichols FT, et al. Delayed intracranial hemorrhage following cerebral infarction in sickle cell anemia. J Assoc Acad Minor Phys. 1990;1(3):79-82. PMID: 2136621; X-1

601. Qureshi S, Abbasi Z, Qadeer N, et al. Kasabach-Merritt syndrome. J Pak Med Assoc. 1990 Jul;40(7):159-61. PMID: 2125659; X-1

602. Raroque HG, Jr., Mandler RN, Griffey MS, et al. Neoplastic angioendotheliomatosis. Arch Neurol. 1990 Aug;47(8):929-30. PMID: 2375700; X-1

603. Restrepo M, Munoz N, Day N, et al. Birth defects among children born to a population occupationally exposed to pesticides in Colombia. Scand J Work Environ Health. 1990 Aug;16(4):239-46. PMID: 2389130; X-1, X-3

604. Reyes BA, Geronemus R. Treatment of port-wine stains during childhood with the flashlamp-pumped pulsed dye laser. J Am Acad Dermatol. 1990 Dec;23(6 Pt 1):1142-8. PMID: 2273116; X-1

605. Rigamonti D, Spetzler RF, Medina M, et al. Cerebral venous malformations. J Neurosurg. 1990 Oct;73(4):560-4. PMID: 2398388; X-1

606. Rothman KF, Nutile A, Appel C. The use of dolls as a teaching aid for children undergoing treatment with the flashlamp-pulsed tunable dye laser. J Am Acad Dermatol. 1990 May;22(5 Pt 1):854-5. PMID: 2347974; X-1

607. Ryoppy S, Poussa M, Heiskanen O, et al. Resection of a thoracic vertebra for hemangioma--operation under deep hypothermia and circulatory arrest. A case report. J Bone Joint Surg Am. 1990 Sep;72(8):1245-9. PMID: 2398095; X-1

608. Salloum E, Flamant F, Caillaud JM, et al. Diagnostic and therapeutic problems of soft tissue tumors other than rhabdomyosarcoma in infants under 1 year of age: a clinicopathological study of 34 cases treated at the Institut Gustave-Roussy. Med Pediatr Oncol. 1990;18(1):37-43. PMID: 2294390; X-2

609. Schafer J, Pirsig W. Digital signal analysis of snoring sounds in children. Int J Pediatr Otorhinolaryngol. 1990 Dec;20(3):193-202. PMID: 2089017; X-1, X-3

610. Scott RM. Brain stem cavernous angiomas in children. Pediatr Neurosurg. 1990;16(6):281-6. PMID: 2134736; X-1

611. Sherwood KA, Tan OT. Treatment of a capillary hemangioma with the flashlamp pumped-dye laser. J Am Acad Dermatol. 1990 Jan;22(1):136-7. PMID: 2298954; X-2

612. Shulkin BL, Argenta LC, Cho KJ, et al. Kasabach-Merritt syndrome: treatment with epsilon-aminocaproic acid and assessment by indium 111 platelet scintigraphy. J Pediatr. 1990 Nov;117(5):746-9. PMID: 2231207; X-1, X-2

613. Smith JA, Jr. Laser treatment of bladder hemangioma. J Urol. 1990 Feb;143(2):282-4. PMID: 2299718; X-3, X-4

614. Staindl O. Hemangiomas of the lips: treatment with magnesium seeds. Facial Plast Surg. 1990;7(2):114-8. PMID: 2132231; X-2

615. Stewart G, Farmer G. Sturge-Weber and Klippel-Trenaunay syndromes with absence of inferior vena cava. Arch Dis Child. 1990 May;65(5):546-7. PMID: 2162657; X-1

616. Suska P, Jakubovsky J, Polak S. Premature delivery and placenta. A morphological study. Czech Med. 1990;13(4):193-212. PMID: 2081444; X-1

617. Taylor JL, Hockley AD, Downing R. Vascular anomalies of the scalp. Childs Nerv Syst. 1990 Sep;6(6):356-9. PMID: 2257551; X-1, X-2

618. Tjaden BL, Buscema J, Haller JA, Jr., et al. Vulvar congenital dysplastic angiopathy. Obstet Gynecol. 1990 Mar;75(3 Pt 2):552-4. PMID: 2154731; X-1

619. Tokuda Y, Uozumi T, Sakoda K, et al. Giant congenital capillary hemangioma of pericranium--case report. Neurol Med Chir (Tokyo). 1990 Dec;30(13):1029-33. PMID: 1714050; X-2

620. Tong YC, Chieng PU, Tsai TC, et al. Renal angiomyolipoma: report of 24 cases. Br J Urol. 1990 Dec;66(6):585-9. PMID: 2265329; X-1

621. Townshend LM, Buckley EG. Linear subcutaneous fat atrophy after a single corticosteroid injection for ocular adnexal hemangioma. Am J Ophthalmol. 1990 Jan 15;109(1):102-3. PMID: 2297019; X-2

622. van der Stricht J. The sclerosing therapy in congenital vascular defects. Int Angiol. 1990 Jul-Sep;9(3):224-7. PMID: 2090706; X-1

623. Weber TR, Connors RH, Tracy TF, Jr., et al. Complex hemangiomas of infants and children. Individualized management in 22 cases. Arch Surg. 1990 Aug;125(8):1017-20; discussion 20-1. PMID: 2198856; X-3, X-4

624. Wetzel LH, Levine E. Soft-tissue tumors of the foot: value of MR imaging for specific diagnosis. AJR Am J Roentgenol. 1990 Nov;155(5):1025-30. PMID: 2120930; X-1

625. Winters Z, Mannell A. Parotid haemangioma. A case report. S Afr J Surg. 1990 Sep;28(3):105-6. PMID: 2218752; X-1

626. Yohannan MD, Abdulla AM, Patel PJ. Neonatal hepatic haemangioendothelioma: presentation with jaundice and microangiopathic haemolytic anaemia. Eur J Pediatr. 1990 Aug;149(11):804-5. PMID: 2226558; X-1

627. . Laser treatment of cutaneous vascular lesions. Med Lett Drugs Ther. 1991 Nov 1;33(856):104-6. PMID: 1943977; X-1, X-2

628. Achauer BM, Vander Kam VM. Strawberry hemangioma of infancy: early definitive treatment with an argon laser. Plast Reconstr Surg. 1991 Sep;88(3):486-9;discussion 90-1. PMID: 1871229; X-2

629. Achauer BM, Vander Kam VM. Ulcerated anogenital hemangioma of infancy. Plast Reconstr Surg. 1991 May;87(5):861-6; discussion 7-8. PMID: 2017494; X-4

630. Apfelberg DB, Lane B, Marx MP. Combined (team) approach to hemangioma management: arteriography with superselective embolization plus YAG laser/sapphire-tip resection. Plast Reconstr Surg. 1991 Jul;88(1):71-82. PMID: 2052663; X-1

631. Ashinoff R, Geronemus RG. Flashlamp-pumped pulsed dye laser for port-wine stains in infancy: earlier versus later treatment. J Am Acad Dermatol. 1991 Mar;24(3):467-72. PMID: 2061448; X-1

632. Ashinoff R, Geronemus RG. Capillary hemangiomas and treatment with the flash lamp-pumped pulsed dye laser. Arch Dermatol. 1991 Feb;127(2):202-5. PMID: 1990985; X-4

633. Azizkhan RG. Life-threatening hematochezia from a rectosigmoid vascular malformation in Klippel-Trenaunay syndrome: long-term palliation using an argon laser. J Pediatr Surg. 1991 Sep;26(9):1125-7; discussion 8. PMID: 1719183; X-1

634. Barak S, Katz J, Kaplan I. The CO2 laser in surgery of vascular tumors of the oral cavity in children. ASDC J Dent Child. 1991 Jul-Aug;58(4):293-6. PMID: 1939793; X-2

635. Baurmash H, DeChiara S. A conservative approach to the management of orofacial vascular lesions in infants and children: report of cases. J Oral Maxillofac Surg. 1991 Nov;49(11):1222-5. PMID: 1941339; X-2

636. Bertalanffy H, Gilsbach JM, Eggert HR, et al. Microsurgery of deep-seated cavernous angiomas: report of 26 cases. Acta Neurochir (Wien). 1991;108(3-4):91-9. PMID: 2031478; X-1

637. Bise RN, Jackson IT, Fukuta K, et al. Nasal bone haemangiomas: rare entities treatable by craniofacial approach. Br J Plast Surg. 1991 Apr;44(3):206-9. PMID: 2025757; X-1

638. Boyd MJ, Collin JR. Capillary haemangiomas: an approach to their management. Br J Ophthalmol. 1991 May;75(5):298-300. PMID: 2036348; X-4

639. Bradley M, Stewart I, Metreweli C. Diagnosis of the peripheral cavernous haemangioma: comparison of ultrasound, CT and RBC scintigraphy. Clin Radiol. 1991 Jul;44(1):34-7. PMID: 1873950; X-1

640. Brauner G, Schliftman A, Cosman B. Evaluation of argon laser surgery in children under 13 years of age. Plast Reconstr Surg. 1991 Jan;87(1):37-43. PMID: 1984281; X-1

641. Byard RW, Burrows PE, Izakawa T, et al. Diffuse infantile haemangiomatosis: clinicopathological features and management problems in five fatal cases. Eur J Pediatr. 1991 Feb;150(4):224-7. PMID: 1843615; X-1

642. Caroli A, Zanasi S, Marcuzzi M, et al. Hemangioma of the hand. Chir Organi Mov. 1991 Oct-Dec;76(4):317-25. PMID: 1800043; X-1

643. Chen FS, Wong TK, Shyr MH, et al. Comparison of inguinal nerve block and intravenous fentanyl in relieving postinguinal herniorrhaphy pain for pediatric outpatients. Ma Zui Xue Za Zhi. 1991 Jun;29(2):580-5. PMID: 1758250; X-1

644. Copley IB, Derwael EF. Investigation and treatment of a multiple limb birth. Br J Neurosurg. 1991;5(3):281-7. PMID: 1892571; X-1, X-2

645. Currie BG, Schell D, Bowring AC. Giant hemangioma of the arm associated with cardiac failure and the Kasabach-Merritt syndrome in a neonate. J Pediatr Surg. 1991 Jun;26(6):734-7. PMID: 1941468; X-2

646. de Prost Y, Teillac D, Bodemer C, et al. Successful treatment of Kasabach-Merritt syndrome with pentoxifylline. J Am Acad Dermatol. 1991 Nov;25(5 Pt 1):854-5. PMID: 1802912; X-1, X-2

647. Demick DA. Cerebrovascular malformation causing sudden death. Analysis of three cases and review of the literature. Am J Forensic Med Pathol. 1991 Mar;12(1):45-9. PMID: 2063819; X-1

648. Destro M, D'Amico DJ, Gragoudas ES, et al. Retinal manifestations of neurofibromatosis. Diagnosis and management. Arch Ophthalmol. 1991 May;109(5):662-6. PMID: 1902661; X-1

649. Dresse MF, David M, Hume H, et al. Successful treatment of Kasabach-Merritt syndrome with prednisone and epsilon-aminocaproic acid. Pediatr Hematol Oncol. 1991 Oct-Dec;8(4):329-34. PMID: 1669958; X-1

650. Dutton SC, Plowman PN. Paediatric haemangiomas: the role of radiotherapy. Br J Radiol. 1991 Mar;64(759):261-9. PMID: 2021799; X-2

651. Ezekowitz A, Mulliken J, Folkman J. Interferon alpha therapy of haemangiomas in newborns and infants. Br J Haematol. 1991 Oct;79 Suppl 1:67-8. PMID: 1931713; X-4

652. Fellows KE, Hoffer FA, Markowitz RI, et al. Multiple collaterals to hepatic infantile hemangioendotheliomas and arteriovenous malformations: effect on embolization. Radiology. 1991 Dec;181(3):813-8. PMID: 1947103; X-1

653. Fernell E, Gillberg C, von Wendt L. Autistic symptoms in children with infantile hydrocephalus. Acta Paediatr Scand. 1991 Apr;80(4):451-7. PMID: 2058395; X-1

654. Fletcher CD, Beham A, Schmid C. Spindle cell haemangioendothelioma: a clinicopathological and immunohistochemical study indicative of a non-neoplastic lesion. Histopathology. 1991 Apr;18(4):291-301. PMID: 2071088; X-1

655. Fragu P, Lemarchand-Venencie F, Benhamou S, et al. Long-term effects in skin and thyroid after radiotherapy for skin angiomas: a French retrospective cohort study. Eur J Cancer. 1991;27(10):1215-22. PMID: 1835589; X-1

656. Garner TB, Del Curling O, Jr., Kelly DL, Jr., et al. The natural history of intracranial venous angiomas. J Neurosurg. 1991 Nov;75(5):715-22. PMID: 1919693; X-1

657. Glatt HJ, Putterman AM, Van Aalst JJ, et al. Adrenal suppression and growth retardation after injection of periocular capillary hemangioma with corticosteroids. Ophthalmic Surg. 1991 Feb;22(2):95-7. PMID: 2038483; X-2

658. Gloviczki P, Stanson AW, Stickler GB, et al. Klippel-Trenaunay syndrome: the risks and benefits of vascular interventions. Surgery. 1991 Sep;110(3):469-79. PMID: 1653464; X-1

659. Goerg C, Schwerk WB, Goerg K. Splenic lesions: sonographic patterns, follow-up, differential diagnosis. Eur J Radiol. 1991 Jul-Aug;13(1):59-66. PMID: 1889432; X-3, X-4

660. Goldberg DJ, Sciales CW. Pyogenic granuloma in children. Treatment with the flashlamp-pumped pulsed dye laser. J Dermatol Surg Oncol. 1991 Dec;17(12):960-2. PMID: 1960269; X-1, X-2

661. Imai T, Matsuo N, Yamashita T, et al. Two cases of hemangioma of the upper lip in infants--treatment using the Nd: YAG laser. Aichi Gakuin Dent Sci. 1991;4:35-44. PMID: 1819335; X-2

662. Kerr R, Frey C. MR imaging in tarsal tunnel syndrome. J Comput Assist Tomogr. 1991 Mar-Apr;15(2):280-6. PMID: 1672132; X-1

663. Kondziolka D, Dempsey PK, Lunsford LD. The case for conservative management of venous angiomas. Can J Neurol Sci. 1991 Aug;18(3):295-9. PMID: 1913363; X-1

664. Kristidis P, de Silva M, Howman-Giles R, et al. Infantile hepatic haemangioma: investigation and treatment. J Paediatr Child Health. 1991 Feb;27(1):57-61. PMID: 2043394; X-2

665. Lai FM, Allen PW, Yuen PM, et al. Locally metastasizing vascular tumor. Spindle cell, epithelioid, or unclassified hemangioendothelioma? Am J Clin Pathol. 1991 Nov;96(5):660-3. PMID: 1951188; X-1

666. Ledley RS, Lusted LB. Reasoning foundations of medical diagnosis. MD Comput. 1991 Sep-Oct;8(5):300-15. PMID: 1749340; X-1

667. Luks FI, Yazbeck S, Brandt ML, et al. Benign liver tumors in children: a 25-year experience. J Pediatr Surg. 1991 Nov;26(11):1326-30. PMID: 1812268; X-3, X-4

668. Madrid M. Management of facial arteriovenous malformations. J Vasc Nurs. 1991 Jun;9(2):16-20. PMID: 1859797; X-1

669. Maillard GF, Clavel PR. Aesthetic units in skin grafting of the face. Ann Plast Surg. 1991 Apr;26(4):347-52. PMID: 1872540; X-1

670. Masih AS, Woods GL, Thiele GM, et al. Detection of cytomegalovirus in bronchoalveolar lavage: a comparison of techniques. Mod Pathol. 1991 Jan;4(1):108-12. PMID: 1850516; X-1

671. Masterson J, Woods D, Lau G, et al. Isolated colonic hemangioma in a child. Can Assoc Radiol J. 1991 Dec;42(6):431-4. PMID: 1751906; X-1

672. Melchior B, Bensahel H, Desgrippes Y. Lower limb bone hemangiomas in children: report of two cases. J Pediatr Orthop. 1991 Jul-Aug;11(4):482-4. PMID: 1860947; X-1

673. Morelli JG, Tan OT, Weston WL. Treatment of ulcerated hemangiomas with the pulsed tunable dye laser. Am J Dis Child. 1991 Sep;145(9):1062-4. PMID: 1877568; X-4

674. Nelson JS. Selective photothermolysis and removal of cutaneous vasculopathies and tattoos by pulsed laser. Plast Reconstr Surg. 1991 Oct;88(4):723-31. PMID: 1896548; X-1

675. Neumann RA, Knobler RM, Lindmaier AP. Photoelectric quantitative evaluation of argon laser treatment of port wine stains. Br J Dermatol. 1991 Feb;124(2):181-6. PMID: 2004003; X-1

676. Patrice SJ, Wiss K, Mulliken JB. Pyogenic granuloma (lobular capillary hemangioma): a clinicopathologic study of 178 cases. Pediatr Dermatol. 1991 Dec;8(4):267-76. PMID: 1792196; X-1

677. Paul KP, Borner C, Muller KM, et al. Capillary hemangioma of the right main bronchus treated by sleeve resection in infancy. Am Rev Respir Dis. 1991 Apr;143(4 Pt 1):876-9. PMID: 2008998; X-2

678. Perrone HC, Ajzen H, Toporovski J, et al. Metabolic disturbance as a cause of recurrent hematuria in children. Kidney Int. 1991 Apr;39(4):707-10. PMID: 2051727; X-1

679. Pfeiffer N. Infants with port wine stains respond to pulsed dye laser. J Clin Laser Med Surg. 1991 Oct;9(5):335-6. PMID: 10149474; X-1

680. Pontisso P, Basso G, Perilongo G, et al. Does hepatitis B virus play a role in primary liver cancer in children of Western countries? Cancer Detect Prev. 1991;15(5):363-8. PMID: 1661202; X-1

681. Premachandra DJ, Milton CM. Childhood haemangiomas of the head and neck. Clin Otolaryngol Allied Sci. 1991 Apr;16(2):117-23. PMID: 2070524; X-2

682. Rebeiz E, April MM, Bohigian RK, et al. Nd-YAG laser treatment of venous malformations of the head and neck: an update. Otolaryngol Head Neck Surg. 1991 Nov;105(5):655-61. PMID: 1754247; X-1

683. Robertson JS, Wiegand DA, Schaitkin BM. Life-threatening hemangioma arising from the parotid gland. Otolaryngol Head Neck Surg. 1991 Jun;104(6):858-62. PMID: 1908981; X-2

684. Robinson JR, Awad IA, Little JR. Natural history of the cavernous angioma. J Neurosurg. 1991 Nov;75(5):709-14. PMID: 1919692; X-1

685. Scheibner A, Wheeland RG. Use of the argon-pumped tunable dye laser for port-wine stains in children. J Dermatol Surg Oncol. 1991 Sep;17(9):735-9. PMID: 1890246; X-1

686. Schild SE, Buskirk SJ, Frick LM, et al. Radiotherapy for large symptomatic hemangiomas. Int J Radiat Oncol Biol Phys. 1991 Aug;21(3):729-35. PMID: 1869466; X-1, X-2

687. Scott TA, Augsburger JJ, Brady LW, et al. Low dose ocular irradiation for diffuse choroidal hemangiomas associated with bullous nonrhegmatogenous retinal detachment. Retina. 1991;11(4):389-93. PMID: 1813954; X-1

688. Seccia A, Salgarello M. Treatment of angiomas with sclerosing injection of hydroxypolyethoxydodecan. Angiology. 1991 Jan;42(1):23-9. PMID: 1992855; X-1

689. Seid AB, Pransky SM, Kearns DB. The open surgical approach to subglottic hemangioma. Int J Pediatr Otorhinolaryngol. 1991 Jul;22(1):85-90. PMID: 1917342; X-2

690. Seo JK, Lee BK, Kim KH, et al. Surgical treatment of giant cavernous hemangiomas of the liver--analysis of 7 patients. J Korean Med Sci. 1991 Jun;6(2):127-33. PMID: 1751017; X-1

691. Shieh CC, Wang PJ. Giant nevocellular nevi with rickets and brainstem tumor. Pediatr Neurol. 1991 Nov-Dec;7(6):452-4. PMID: 1665693; X-1

692. Sihota R, Kumar H, Sood NN. The additive influence of nevus flammeus and the nevus of Ota on congenital glaucoma. Indian J Ophthalmol. 1991 Jul-Sep;39(3):122-4. PMID: 1841885; X-1

693. Steiman HR, Cullen CL, Geist JR. Bilateral mandibular regional odontodysplasia with vascular nevus. Pediatr Dent. 1991 Sep-Oct;13(5):303-6. PMID: 1667684; X-1

694. Toye R, Armstrong P, Dacie JE. Lymphangiohaemangioma of the mediastinum. Br J Radiol. 1991 Jan;64(757):62-4. PMID: 1998842; X-1

695. Weatherford DA, Abrams RS, Wallace JG. Vascular malformation: case report and literature review. J S C Med Assoc. 1991 Nov;87(11):539-42. PMID: 1766244; X-1

696. White CW, Wolf SJ, Korones DN, et al. Treatment of childhood angiomatous diseases with recombinant interferon alfa-2a. J Pediatr. 1991 Jan;118(1):59-66. PMID: 1986099; X-2

697. Wowra B, Layer G, Schad LR, et al. Three-dimensional time-of-flight MR-angiography and the surgical indication of brainstem cavernomas. Acta Neurochir (Wien). 1991;112(3-4):77-82. PMID: 1776522; X-1

698. Abernethy LJ, Phelan E, Rosenfeld JV. Choroid plexus angioma: a rare cause of cerebral hemorrhage in childhood. Pediatr Radiol. 1992;22(2):138-9. PMID: 1501945; X-1

699. Alani HM, Warren RM. Percutaneous photocoagulation of deep vascular lesions using a fiberoptic laser wand. Ann Plast Surg. 1992 Aug;29(2):143-8. PMID: 1530264; X-2

700. Alexander E, 3rd, Loeffler JS. Radiosurgery for intracranial vascular malformations: techniques, results, and complications. Clin Neurosurg. 1992;39:273-91. PMID: 1458744; X-1

701. Assaf A, Nasr A, Johnson T. Corticosteroids in the management of adnexal hemangiomas in infancy and childhood. Ann Ophthalmol. 1992 Jan;24(1):12-8. PMID: 1543320; X-4

702. Barton DJ, Miller JH, Allwright SJ, et al. Distinguishing soft-tissue hemangiomas from vascular malformations using technetium-labeled red blood cell scintigraphy. Plast Reconstr Surg. 1992 Jan;89(1):46-52; discussion 3-5. PMID: 1727262; X-3, X-4

703. Beals RK, Lovrien EW. Diffuse capillary hemangiomas associated with skeletal hypotrophy. J Pediatr Orthop. 1992 May-Jun;12(3):401-2. PMID: 1573010; X-1, X-2

704. Bergeson PS, Rekate HL, Tack ED. Cerebral cavernous angiomas in the newborn. Clin Pediatr (Phila). 1992 Jul;31(7):435-7. PMID: 1617869; X-1

705. Bertalanffy H, Kuhn G, Scheremet R, et al. Indications for surgery and prognosis in patients with cerebral cavernous angiomas. Neurol Med Chir (Tokyo). 1992 Aug;32(9):659-66. PMID: 1383853; X-1

706. Bilyk JR, Adamis AP, Mulliken JB. Treatment options for periorbital hemangioma of infancy. Int Ophthalmol Clin. 1992 Summer;32(3):95-109. PMID: 1639604; X-1, X-2

707. Brahams D. Cosmetic surgery for portwine stain. Lancet. 1992 Apr 25;339(8800):1045-6. PMID: 1349063; X-1, X-2

708. Buchanan DS, Fagan PA, Turner J. Cavernous haemangioma of the temporal bone. J Laryngol Otol. 1992 Dec;106(12):1086-8. PMID: 1487668; X-1

709. Castro R, Meek R, Bean C, et al. Successful treatment of a giant cavernous hemangioma with oral cyclophosphamide (cytoxan) in an infant. Del Med J. 1992 Dec;64(12):745-9. PMID: 1478327; X-1

710. Chow LT, Chow WH, Fong DT. Epithelioid hemangioendothelioma of the brain. Am J Surg Pathol. 1992 Jun;16(6):619-25. PMID: 1376023; X-1

711. Churchyard A, Khangure M, Grainger K. Cerebral cavernous angioma: a potentially benign condition? Successful treatment in 16 cases. J Neurol Neurosurg Psychiatry. 1992 Nov;55(11):1040-5. PMID: 1469400; X-1

712. Cooper M, Slovis TL, Madgy DN, et al. Congenital subglottic hemangioma: frequency of symmetric subglottic narrowing on frontal radiographs of the neck. AJR Am J Roentgenol. 1992 Dec;159(6):1269-71. PMID: 1442399; X-3, X-4

713. Davidoff AM, Filston HC. Treatment of infantile subglottic hemangioma with electrocautery. J Pediatr Surg. 1992 Apr;27(4):436-9. PMID: 1522452; X-2

714. De Laey JJ, Heintz B, Pollet L. Retinal angioma and juvenile sex-linked retinoschisis. Ophthalmic Paediatr Genet. 1992 Jun;13(2):73-6. PMID: 1495769; X-1

715. Deans RM, Harris GJ, Kivlin JD. Surgical dissection of capillary hemangiomas. An alternative to intralesional corticosteroids. Arch Ophthalmol. 1992 Dec;110(12):1743-7. PMID: 1463416; X-3, X-4

716. Doi O, Takada Y. Kasabach-Merritt syndrome in two neonates. J Pediatr Surg. 1992 Dec;27(12):1507-8. PMID: 1469553; X-1

717. Donati P, Maiuri F, Gangemi M, et al. Cavernous angioma of the pineal region. J Neurosurg Sci. 1992 Jul-Sep;36(3):155-60. PMID: 1484302; X-1

718. Drut R, Drut RM, Toulouse JC. Hepatic hemangioendotheliomas, placental chorioangiomas, and dysmorphic kidneys in Beckwith-Wiedemann syndrome. Pediatr Pathol. 1992 Mar-Apr;12(2):197-203. PMID: 1570237; X-1

719. Ebeling U, Huber P. Localization of central lesions by correlation of CT findings and neurological deficits. Acta Neurochir (Wien). 1992;119(1-4):17-22. PMID: 1481744; X-1

720. Eto H, Toriyama K, Tsuda N, et al. Flow cytometric DNA analysis of vascular soft tissue tumors, including African endemic-type Kaposi's sarcoma. Hum Pathol. 1992 Sep;23(9):1055-60. PMID: 1516928; X-1

721. Ezekowitz RA, Mulliken JB, Folkman J. Interferon alfa-2a therapy for life-threatening hemangiomas of infancy. N Engl J Med. 1992 May 28;326(22):1456-63. PMID: 1489383; X-4

722. Farley TJ, Klionsky N. Mixed hemangioma and cystic lymphangioma of the esophagus in a child. J Pediatr Gastroenterol Nutr. 1992 Aug;15(2):178-80. PMID: 1403466; X-1

723. Farrell MA, DeRosa MJ, Curran JG, et al. Neuropathologic findings in cortical resections (including hemispherectomies) performed for the treatment of intractable childhood epilepsy. Acta Neuropathol. 1992;83(3):246-59. PMID: 1557956; X-1

724. Ferrante L, Palma L, d'Addetta R, et al. Intracranial cavernous angioma. Neurosurg Rev. 1992;15(2):125-33. PMID: 1635626; X-1

725. Filling-Katz MR, Levin SW, Patronas NJ, et al. Terminal transverse limb defects associated with familial cavernous angiomatosis. Am J Med Genet. 1992 Feb 1;42(3):346-51. PMID: 1536177; X-1

726. Frieden IJ, Esterly NB. Pyogenic granulomas of infancy masquerading as strawberry hemangiomas. Pediatrics. 1992 Dec;90(6):989-91. PMID: 1437442; X-1

727. Fujii K, Matsushima T, Inamura T, et al. Natural history and choice of treatment in forty patients with medullary venous malformation (MVM). Neurosurg Rev. 1992;15(1):13-20. PMID: 1584432; X-1

728. Garden JM, Bakus AD, Paller AS. Treatment of cutaneous hemangiomas by the flashlamp-pumped pulsed dye laser: prospective analysis. J Pediatr. 1992 Apr;120(4 Pt 1):555-60. PMID: 1552392; X-4

729. Goodman P, Dominguez R, Castillo M. Diffuse neonatal hemangiomatosis: imaging findings in two patients. Comput Med Imaging Graph. 1992 Mar-Apr;16(2):117-20. PMID: 1568198; X-1

730. Greenspan A, McGahan JP, Vogelsang P, et al. Imaging strategies in the evaluation of soft-tissue hemangiomas of the extremities: correlation of the findings of plain radiography, angiography, CT, MRI, and ultrasonography in 12 histologically proven cases. Skeletal Radiol. 1992;21(1):11-8. PMID: 1546331; X-1

731. Hellmann JR, Myer CM, 3rd, Prenger EC. Therapeutic alternatives in the treatment of life-threatening vasoformative tumors. Am J Otolaryngol. 1992 Jan-Feb;13(1):48-53. PMID: 1585985; X-1

732. Holy A, Geronemus RG. Treatment of periorbital port-wine stains with the flashlamp-pumped pulsed dye laser. Arch Ophthalmol. 1992 Jun;110(6):793-7. PMID: 1596226; X-1

733. Horak D, Svec F, Isakov Y, et al. Use of poly(2-hydroxyethyl methacrylate) for endovascular occlusion in pediatric surgery. Clin Mater. 1992;9(1):43-8. PMID: 10149958; X-1

734. Huston J, 3rd, Forbes GS, Ruefenacht DA, et al. Magnetic resonance imaging of facial vascular anomalies. Mayo Clin Proc. 1992 Aug;67(8):739-47. PMID: 1434912; X-3, X-4

735. Illum N, Winther Nielsen H, Guldhammer Skov B. Recurrent nodular haemangiomas in Klippel-Trenaunay syndrome. Acta Paediatr. 1992 May;81(5):456-8. PMID: 1323362; X-1, X-2

736. Karabocuoglu M, Basarer N, Aydogan U, et al. Development of Kasabach-Merritt syndrome following needle aspiration of a hemangioma. Pediatr Emerg Care. 1992 Aug;8(4):218-20. PMID: 1513734; X-1

737. Keleti D, Flickinger JC, Hobson SR, et al. Radiotherapy of lymphoproliferative diseases of the orbit. Surveillance of 65 cases. Am J Clin Oncol. 1992 Oct;15(5):422-7. PMID: 1524043; X-1

738. Kennard CD, Whitaker DC. Iontophoresis of lidocaine for anesthesia during pulsed dye laser treatment of port-wine stains. J Dermatol Surg Oncol. 1992 Apr;18(4):287-94. PMID: 1560152; X-1

739. Khandelwal N, Malik N, Rao DS, et al. Vertebral hemangioma with spinal cord compression: the role of pre-operative embolisation. Indian Pediatr. 1992 Jun;29(6):771-3. PMID: 1500142; X-1, X-2

740. Knych SA, Goldberg MJ, Wolfe HJ. Intraosseous arteriovenous malformation in a pediatric patient. Clin Orthop Relat Res. 1992 Mar(276):307-12. PMID: 1537171; X-1

741. Komiyama M, Khosla VK, Yamamoto Y, et al. Embolization in high-flow arteriovenous malformations of the face. Ann Plast Surg. 1992 Jun;28(6):575-83. PMID: 1622040; X-1

742. Korolev BA, Pavlunin AV, Karpova NA. Congenital pulmonary arteriovenous aneurysms. Cor et Vasa. 1992;34(2):149-57. PMID: 1993144530; X-1

743. Kroh H, Taraszewska A, Ruzikowski E, et al. Neuropathological changes in resected temporal lobe of patients with cryptogenic epilepsy. Neuropatol Pol. 1992;30(2):133-45. PMID: 1297928; X-1

744. Louis DS, Fortin PT. Perineural hemangiomas of the upper extremity: report of four cases. J Hand Surg Am. 1992 Mar;17(2):308-11. PMID: 1564281; X-1

745. Luomanen M. Experience with a carbon dioxide laser for removal of benign oral soft-tissue lesions. Proc Finn Dent Soc. 1992;88(1-2):49-55. PMID: 1470632; X-1

746. Lyon DB, Tang TT, Kidder TM. Epithelioid hemangioendothelioma of the orbital bones. Ophthalmology. 1992 Dec;99(12):1773-8. PMID: 1480392; X-1

747. Malik S, Cohen BH, Robinson J, et al. Progressive vision loss. A rare manifestation of familial cavernous angiomas. Arch Neurol. 1992 Feb;49(2):170-3. PMID: 1736851; X-1

748. Mast HL, Haller JO, Solomon M. Benign lesions of the mandibular and maxillary region in children: characterization by CT and MRI. Comput Med Imaging Graph. 1992 Jan-Feb;16(1):1-9. PMID: 1313327; X-1

749. Matsushima T, Fukui M, Inoue T, et al. Microsurgical and magnetic resonance imaging anatomy of the cerebello-medullary fissure and its application during fourth ventricle surgery. Neurosurgery. 1992 Mar;30(3):325-30. PMID: 1620293; X-1

750. McHugh K, Burrows PE. Infantile hepatic hemangioendotheliomas: significance of portal venous and systemic collateral arterial supply. J Vasc Interv Radiol. 1992 May;3(2):337-44. PMID: 1627883; X-1

751. Messineo A, Wesson DE, Filler RM, et al. Juvenile hemangiomas involving the thoracic trachea in children: report of two cases. J Pediatr Surg. 1992 Oct;27(10):1291-3. PMID: 1403505; X-1, X-2

752. Miaux Y, Lemarchand-Venencie F, Cyna-Gorse F, et al. MR imaging of breast hemangioma in female infants. Pediatr Radiol. 1992;22(6):463-4. PMID: 1437377; X-3, X-4

753. Miller JG, Orton CI. Long term follow-up of a case of Kasabach-Merritt syndrome successfully treated with radiotherapy and corticosteroids. Br J Plast Surg. 1992 Oct;45(7):559-61. PMID: 1446205; X-1

754. Mizoi K, Yoshimoto T, Suzuki J. Clinical analysis of ten cases with surgically treated brain stem cavernous angiomas. Tohoku J Exp Med. 1992 Feb;166(2):259-67. PMID: 1566274; X-1

755. Mizutani T, Tanaka H, Aruga T. Multiple arteriovenous malformations located in the cerebellum, posterior fossa, spinal cord, dura, and scalp with associated port-wine stain and supratentorial venous anomaly. Neurosurgery. 1992 Jul;31(1):137-40; discussion 40-1. PMID: 1641094; X-1

756. Oakes WJ. The natural history of patients with the Sturge-Weber syndrome. Pediatr Neurosurg. 1992;18(5-6):287-90. PMID: 1476938; X-1

757. Ohshiro T, Chen I. Low reactive-level 830 nm diode laser therapy (LLLT) successfully accelerates regression of strawberry haemangioma in the infant: Case reports. Laser Therapy. 1992;4(3):127-32. PMID: 1993040388; X-2

758. Padalkar JA, Bapat VS, Phadke MA, et al. Successful treatment of hepatic hemangiomas with corticosteroids. Indian Pediatr. 1992 Jun;29(6):769-70. PMID: 1500141; X-2

759. Paltiel HJ, Patriquin HB, Keller MS, et al. Infantile hepatic hemangioma: Doppler US. Radiology. 1992 Mar;182(3):735-42. PMID: 1535887; X-4

760. Park DD, Ricketts RR. Infantile gastrointestinal hemangioma as a cause of chronic anemia. South Med J. 1992 Feb;85(2):201-3. PMID: 1738891; X-2

761. Perez-Guillermo M, Sola Perez J, Garcia Rojo B, et al. Fine needle aspiration cytology of cutaneous vascular tumours. Cytopathology. 1992;3(4):231-44. PMID: 1330048; X-1, X-2

762. Pierce RN, Dunn L, Knisely AS. Consumptive coagulopathy in utero associated with multiple vascular malformations. Pediatr Pathol. 1992 Jan-Feb;12(1):67-71. PMID: 1561152; X-1

763. Pongprasit P. Corticosteroid treatment of extensive hemangiomas: analysis of 22 cases in children. J Med Assoc Thai. 1992 Dec;75(12):671-9. PMID: 1308535; X-4

764. Rajput A, Gauderer MW, Hack M. Inguinal hernias in very low birth weight infants: incidence and timing of repair. J Pediatr Surg. 1992 Oct;27(10):1322-4. PMID: 1403513; X-1

765. Reid WH, Miller ID, Murphy MJ, et al. Treatment of portwine stains using the pulsed dye laser. Br J Plast Surg. 1992 Nov-Dec;45(8):565-70. PMID: 1493527; X-1

766. Robinson D, Segal M, Halperin N, et al. Neuropeptidergic innervation of intramuscular hemangiomas. Exp Mol Pathol. 1992 Jun;56(3):186-96. PMID: 1379196; X-1

767. Rootman J, Kao SC, Graeb DA. Multidisciplinary approaches to complicated vascular lesions of the orbit. Ophthalmology. 1992 Sep;99(9):1440-6. PMID: 1407977; X-1

768. Santos-Dias A. CO 2 laser surgery in hemophilia treatment. J Clin Laser Med Surg. 1992 Aug;10(4):297-301. PMID: 10183941; X-1

769. Scott RM, Barnes P, Kupsky W, et al. Cavernous angiomas of the central nervous system in children. J Neurosurg. 1992 Jan;76(1):38-46. PMID: 1727167; X-1

770. Shriner DL, Wagner RF, Jr., Weedn VW, et al. Informed consent and risk management in dermatology: to what extent do dermatologists disclose alternate diagnostic and treatment options to their patients? J Contemp Health Law Policy. 1992 Spring;8:137-62. PMID: 10118984; X-1

771. Spiller JC, Sharma V, Woods GM, et al. Diffuse neonatal hemangiomatosis treated successfully with interferon alfa-2a. J Am Acad Dermatol. 1992 Jul;27(1):102-4. PMID: 1619055; X-1

772. Sullivan TJ, Clarke MP, Morin JD. The ocular manifestations of the Sturge-Weber syndrome. J Pediatr Ophthalmol Strabismus. 1992 Nov-Dec;29(6):349-56. PMID: 1287171; X-1

773. Takamatsu H, Akiyama H, Noguchi H, et al. Endorectal pull-through operation for diffuse cavernous hemangiomatosis of the sigmoid colon, rectum and anus. Eur J Pediatr Surg. 1992 Aug;2(4):245-7. PMID: 1390557; X-1

774. Tan OT, Stafford TJ. EMLA for laser treatment of portwine stains in children. Lasers Surg Med. 1992;12(5):543-8. PMID: 1406008; X-1

775. Tan SA, Yeo SH. Placental chorioangioma: a case report and review. Singapore Med J. 1992 Feb;33(1):83-5. PMID: 1598615; X-1

776. Troughton AH, Paxton RM. Direct puncture venography in subcutaneous cavernous haemangiomas. Clin Radiol. 1992 Apr;45(4):250-3. PMID: 1395381; X-1

777. Turjman F, Arteaga C, Tavernier T, et al. Haemorrhagic complications of intracerebral cavernomas: value of MRI. J Neuroradiol. 1992;19(2):107-17. PMID: 1629774; X-1

778. Van Campenhout I, Patriquin H. Malignant microvasculature in abdominal tumors in children: detection with Doppler US. Radiology. 1992 May;183(2):445-8. PMID: 1373242; X-1

779. Vedung S, Atterhem H. Argon laser treatment of port-wine stains: the patients' evaluations of the result. Plast Reconstr Surg. 1992 Sep;90(3):430-5. PMID: 1513888; X-1

780. Waner M, Suen JY, Dinehart S. Treatment of hemangiomas of the head and neck. Laryngoscope. 1992 Oct;102(10):1123-32. PMID: 1405964; X-1, X-2

781. White WL, Mumma JV, Tomasovic JJ. Congenital oculomotor nerve palsy, cerebellar hypoplasia, and facial capillary hemangioma. Am J Ophthalmol. 1992 May 15;113(5):497-500. PMID: 1575222; X-2

782. Wirth T, Rauch G, Ruschoff J, et al. Synovial haemangioma of the knee joint. Int Orthop. 1992;16(2):130-2. PMID: 1428309; X-2

783. Zide BM, Karp NS. Maximizing gain from rectangular tissue expanders. Plast Reconstr Surg. 1992 Sep;90(3):500-4; discussion 5-6. PMID: 1513899; X-1

784. Abdul-Wahab BR, Olusegun OA. Haemangioma of the vallecula causing acute upper airway obstruction in a 6 1/2 week old Nigerian infant with strawberry naevus. Trop Geogr Med. 1993 Mar;45(1):33-5. PMID: 8470305; X-1

785. Acciarri N, Padovani R, Giulioni M, et al. Intracranial and orbital cavernous angiomas: a review of 74 surgical cases. Br J Neurosurg. 1993;7(5):529-39. PMID: 8267890; X-1

786. Agarwal HC, Sandramouli S, Sihota R, et al. Sturge-Weber syndrome: management of glaucoma with combined trabeculotomy-trabeculectomy. Ophthalmic Surg. 1993 Jun;24(6):399-402. PMID: 8336891; X-1

787. Alter GJ, Trengove-Jones G, Horton CE, Jr. Hemangioma of penis and scrotum. Urology. 1993 Aug;42(2):205-8. PMID: 8367930; X-2

788. Apfelberg DB, Smoller B. Preliminary analysis of histological results of Hexascan device with continuous tunable dye laser at 514 (argon) and 577 NM (yellow). Lasers Surg Med. 1993;13(1):106-12. PMID: 8426517; X-1

789. Armstrong AL, Finch RG, Bailie FB. Serious group A streptococcal infections complicating cryotherapy to lip haemangiomas. Clin Exp Dermatol. 1993 Nov;18(6):537-9. PMID: 8252791; X-2

790. Ashinoff R, Geronemus RG. Failure of the flashlamp-pumped pulsed dye laser to prevent progression to deep hemangioma. Pediatr Dermatol. 1993 Mar;10(1):77-80. PMID: 8493176; X-2

791. Atebara NH, Shields JA. Capillary hemangioma of the optic disc associated with a total retinal detachment. Ophthalmic Surg. 1993 Oct;24(10):686-8. PMID: 8259247; X-2

792. Awad IA, Robinson JR, Jr., Mohanty S, et al. Mixed vascular malformations of the brain: clinical and pathogenetic considerations. Neurosurgery. 1993 Aug;33(2):179-88; discussion 88. PMID: 8367039; X-1

793. Baronia AK, Pandey CK, Kaushik S. Diffuse oral facial cavernous hemangioma causing severe airway obstruction after intramuscular ketamine. Anesthesiology. 1993 Dec;79(6):1421-4. PMID: 8267215; X-1

794. Benedikt RA, Brown DC, Walker R, et al. Sturge-Weber syndrome: cranial MR imaging with Gd-DTPA. AJNR Am J Neuroradiol. 1993 Mar-Apr;14(2):409-15. PMID: 8456721; X-1

795. Blei F, Orlow SJ, Geronemus RG. Interferon alfa-2a therapy for extensive perianal and lower extremity hemangioma. J Am Acad Dermatol. 1993 Jul;29(1):98-9. PMID: 8315084; X-2

796. Blei F, Orlow SJ, Geronemus RG. Supraumbilical midabdominal raphe, sternal atresia, and hemangioma in an infant: response of hemangioma to laser and interferon alfa-2a. Pediatr Dermatol. 1993 Mar;10(1):71-6. PMID: 8493175; X-2

797. Bloom PA, Laidlaw A, Easty DL. Spontaneous development of retinal ischaemia and rubeosis in eyes with retinal racemose angioma. Br J Ophthalmol. 1993 Feb;77(2):124-5. PMID: 8435415; X-1

798. Breviere GM, Bonnevalle M, Pruvo JP, et al. Use of Ethibloc in the treatment of cystic and venous angiomas in children. 19 cases. Eur J Pediatr Surg. 1993 Jun;3(3):166-70. PMID: 8353118; X-1

799. Burton BK, Schulz CJ, Burd LI. Spectrum of limb disruption defects associated with chorionic villus sampling. Pediatrics. 1993 May;91(5):989-93. PMID: 8474823; X-1

800. Carrington PR, Rowley MJ, Fowler M, et al. Kasabach-Merritt syndrome with bone involvement: the pseudomalignant sign of Gorham. J Am Acad Dermatol. 1993 Jul;29(1):117-9. PMID: 8315070; X-1

801. de Vathaire F, Fragu P, Francois P, et al. Long-term effects on the thyroid of irradiation for skin angiomas in childhood. Radiat Res. 1993 Mar;133(3):381-6. PMID: 8451391; X-3

802. Devaney K, Vinh TN, Sweet DE. Synovial hemangioma: a report of 20 cases with differential diagnostic considerations. Hum Pathol. 1993 Jul;24(7):737-45. PMID: 8319952; X-1

803. Diaz-Landaeta L, Kerdel FA. Hyperhidrotic, painful lesion. Eccrine angiomatous hamartoma. Arch Dermatol. 1993 Jan;129(1):107, 10. PMID: 8420481; X-1

804. Donauer E, Reif J, al-Khalaf B, et al. Intraventricular haemorrhage caused by aneurysms and angiomas. Acta Neurochir (Wien). 1993;122(1-2):23-31. PMID: 8333305; X-1

805. Ecklund J, Schut L, Rorke L. Associated vascular malformations and neoplasms in children. Pediatr Neurosurg. 1993 Jul-Aug;19(4):196-201. PMID: 8329304; X-1

806. Enjolras O, Mulliken JB. The current management of vascular birthmarks. Pediatr Dermatol. 1993 Dec;10(4):311-3. PMID: 8302734; X-1

807. Faro SH, Mahboubi S, Ortega W. CT diagnosis of rib anomalies, tumors, and infection in children. Clin Imaging. 1993 Jan-Mar;17(1):1-7. PMID: 8439835; X-1

808. Fiore F, Califano L, Cortese A, et al. Hemangiomas of the maxillofacial area. Usefulness of 99Tcm-labelled red cell scintigraphy. Nucl Med Commun. 1993 May;14(5):378-83. PMID: 8510878; X-1

809. Fornage BD, McGavran MH, Duvic M, et al. Imaging of the skin with 20-MHz US. Radiology. 1993 Oct;189(1):69-76. PMID: 8372222; X-1

810. Fox MW, Onofrio BM. The natural history and management of symptomatic and asymptomatic vertebral hemangiomas. J Neurosurg. 1993 Jan;78(1):36-45. PMID: 8416240; X-1

811. Frodel JL, Jr., Whitaker DC. Primary reconstruction of congenital facial lesion defects with tissue expansion. J Dermatol Surg Oncol. 1993 Dec;19(12):1110-6. PMID: 8282910; X-1

812. Fuchs B, Philipp C, Engel-Murke F, et al. Techniques for endoscopic and non-endoscopic intracorporeal laser applications. Endosc Surg Allied Technol. 1993 Aug;1(4):217-23. PMID: 8050024; X-1, X-2

813. Fukunaga M, Shimoda T, Nikaido T, et al. Soft tissue vascular tumors. A flow cytometric DNA analysis. Cancer. 1993 Apr 1;71(7):2233-41. PMID: 8453543; X-1

814. Gangemi M, Maiuri F, Donati PA, et al. Rapid growth of a brain-stem cavernous angioma. Acta Neurol (Napoli). 1993 Apr;15(2):132-7. PMID: 8328323; X-1

815. Garden JM, Bakus AD. Clinical efficacy of the pulsed dye laser in the treatment of vascular lesions. J Dermatol Surg Oncol. 1993 Apr;19(4):321-6. PMID: 8478471; X-1

816. Gelb AB, Van Meter SH, Billingham ME, et al. Infantile histiocytoid cardiomyopathy--myocardial or conduction system hamartoma: what is the cell type involved? Hum Pathol. 1993 Nov;24(11):1226-31. PMID: 8244322; X-1

817. Geronemus RG. Pulsed dye laser treatment of vascular lesions in children. J Dermatol Surg Oncol. 1993 Apr;19(4):303-10. PMID: 8478469; X-1, X-2

818. Goh WH, Lo R. A new 3C syndrome: cerebellar hypoplasia, cavernous haemangioma and coarctation of the aorta. Dev Med Child Neurol. 1993 Jul;35(7):637-41. PMID: 9435781; X-1

819. Goldman MP, Fitzpatrick RE, Ruiz-Esparza J. Treatment of port-wine stains (capillary malformation) with the flashlamp-pumped pulsed dye laser. J Pediatr. 1993 Jan;122(1):71-7. PMID: 8419617; X-1

820. Hatley RM, Sabio H, Howell CG, et al. Successful management of an infant with a giant hemangioma of the retroperitoneum and Kasabach-Merritt syndrome with alpha-interferon. J Pediatr Surg. 1993 Oct;28(10):1356-7; discussion 8-9. PMID: 8263701; X-1, X-2

821. Henley JD, Danielson CF, Rothenberger SS, et al. Kasabach-Merritt syndrome with profound platelet support. Am J Clin Pathol. 1993 May;99(5):628-30. PMID: 8493954; X-1, X-2

822. Huang JF, Li GS, Chen BX. An improved technique for bloodless hepatic resection on in situ cold perfused liver. Chin Med J (Engl). 1993 May;106(5):385-9. PMID: 8404283; X-1

823. Jabra AA, Taylor GA. MRI evaluation of superficial soft tissue lesions in children. Pediatr Radiol. 1993;23(6):425-8. PMID: 8255642; X-1

824. Jackson IT, Carreno R, Potparic Z, et al. Hemangiomas, vascular malformations, and lymphovenous malformations: classification and methods of treatment. Plast Reconstr Surg. 1993 Jun;91(7):1216-30. PMID: 8497521; X-3, X-4

825. Jarrett F. Cavernous hemangioma of the cephalic vein. Cardiovasc Surg. 1993 Aug;1(4):386-8. PMID: 8076066; X-1

826. Jimenez-Cruz JF, Osca JM. Laser treatment of glans penis hemangioma. Eur Urol. 1993;24(1):81-3. PMID: 8365446; X-1, X-2

827. Kawagishi J, Suzuki M, Kayama T, et al. Huge multilobular cavernous angioma in an infant: case report. Neurosurgery. 1993 Jun;32(6):1028-30; discussion 30-1. PMID: 8327078; X-1

828. Kennedy WA, 2nd, Hensle TW, Giella J, et al. Potassium thiophosphate laser treatment of genitourinary hemangioma in the pediatric population. J Urol. 1993 Sep;150(3):950-2. PMID: 8345617; X-1, X-2

829. Kojima Y, Kuwana N. Progressive diffuse arteriovenous malformation--case report. Neurol Med Chir (Tokyo). 1993 Apr;33(4):242-5. PMID: 7685857; X-1

830. Kulkarni ML, Kumar CS, George VG, et al. Oral steroids in the treatment of periorbital hemangioma. Indian Pediatr. 1993 Mar;30(3):379-82. PMID: 8365795; X-2

831. Kumar A, Aggarwal S, Willinsky R, et al. Posterior fossa surgery: an unusual cause of superficial siderosis. Neurosurgery. 1993 Mar;32(3):455-7; discussion 7. PMID: 8455772; X-1

832. Kurtz SN, Melamed S, Blumenthal M. Cataract and intraocular lens implantation after remote trabeculectomy for Sturge-Weber syndrome. J Cataract Refract Surg. 1993 Jul;19(4):539-41. PMID: 8355162; X-1

833. Lee C, Dineen TE, Brack M, et al. The mucopolysaccharidoses: characterization by cranial MR imaging. AJNR Am J Neuroradiol. 1993 Nov-Dec;14(6):1285-92. PMID: 8279321; X-1

834. Levine MR, Kellis A, Lash R. Nasal glioma masquerading as a capillary hemangioma. Ophthal Plast Reconstr Surg. 1993 Jun;9(2):132-4. PMID: 8323905; X-1

835. Lim RY. Nd:YAG laser surgery of venous malformations. W V Med J. 1993 Mar;89(3):109-10. PMID: 8475623; X-1

836. Lindquist C, Guo WY, Karlsson B, et al. Radiosurgery for venous angiomas. J Neurosurg. 1993 Apr;78(4):531-6. PMID: 8110208; X-1

837. Lupret V, Negovetic L, Smiljanic D, et al. Cerebral venous angiomas: surgery as a mode of treatment for selected cases. Acta Neurochir (Wien). 1993;120(1-2):33-9. PMID: 8434514; X-1

838. MacArthur CJ, Gliklich R, McGill TJ, et al. Sinus complications in mucopolysaccharidosis IH/S (Hurler-Scheie syndrome). Int J Pediatr Otorhinolaryngol. 1993 Feb;26(1):79-87. PMID: 8444549; X-1

839. Mantravadi J, Roth LM, Kafrawy AH. Vascular neoplasms of the parotid gland. Parotid vascular tumors. Oral Surg Oral Med Oral Pathol. 1993 Jan;75(1):70-5. PMID: 8419878; X-1, X-2

840. Matsumoto T, Okano R, Sakura N, et al. Hypergalactosaemia in a patient with portal-hepatic venous and hepatic arterio-venous shunts detected by neonatal screening. Eur J Pediatr. 1993 Dec;152(12):990-2. PMID: 8131818; X-1

841. Mazzocchi A, Foschini MP, Marconi F, et al. Kasabach-Merritt syndrome associated to angiosarcoma of the breast. A case report and review of the literature. Tumori. 1993 Apr 30;79(2):137-40. PMID: 8346567; X-1

842. McCarthy RE, Lytle JO, Van Devanter S. The use of total circulatory arrest in the surgery of giant hemangioma and Klippel-Trenaunay syndrome in neonates. Clin Orthop Relat Res. 1993 Apr(289):237-42. PMID: 8386070; X-1, X-2

843. McDaniel DH. Clinical usefulness of the Hexascan. Treatment of cutaneous vascular and melanocytic disorders. J Dermatol Surg Oncol. 1993 Apr;19(4):312-9. PMID: 8478470; X-1

844. Miyagi Y, Mannoji H, Akaboshi K, et al. Intraventricular cavernous malformation associated with medullary venous malformation. Neurosurgery. 1993 Mar;32(3):461-4; discussion 4. PMID: 8455774; X-1

845. Mizuguchi M, Kano H, Narita M, et al. Weber syndrome caused by intracerebral hemorrhage in a hemophiliac boy. Brain Dev. 1993 Nov-Dec;15(6):446-7. PMID: 8147504; X-1

846. Mordon S, Rotteleur G, Brunetaud JM, et al. Rationale for automatic scanners in laser treatment of port wine stains. Lasers Surg Med. 1993;13(1):113-23. PMID: 8426518; X-1

847. Morelli JG, Huff JC, Weston WL. Treatment of congenital telangiectatic vascular malformations with the pulsed-dye laser (585 nm). Pediatrics. 1993 Oct;92(4):603-6. PMID: 8414835; X-1

848. Nakada K, Kawada T, Fujioka T, et al. Hemangioma of the upper arm associated with massive hemorrhage in a neonate. Surg Today. 1993;23(3):273-6. PMID: 8467182; X-1, X-2

849. Neumann RA, Leonhartsberger H, Bohler-Sommeregger K, et al. Results and tissue healing after copper-vapour laser (at 578 nm) treatment of port wine stains and facial telangiectasias. Br J Dermatol. 1993 Mar;128(3):306-12. PMID: 8471515; X-1

850. Niechajev IA, Clodius L. Diagnostic criteria of vascular lesions in the face. Ann Plast Surg. 1993 Jul;31(1):32-41. PMID: 8357218; X-1, X-2

851. Pascual-Castroviejo I, Diaz-Gonzalez C, Garcia-Melian RM, et al. Sturge-Weber syndrome: study of 40 patients. Pediatr Neurol. 1993 Jul-Aug;9(4):283-8. PMID: 8216540; X-1

852. Phillips WG, Marsden JR. Kasabach-Merritt syndrome exacerbated by platelet transfusion. J R Soc Med. 1993 Apr;86(4):231-2. PMID: 8505736; X-1

853. Radke M, Waldschmidt J, Stolpe HJ, et al. Blue rubber-bleb-nevus syndrome with predominant urinary bladder hemangiomatosis. Eur J Pediatr Surg. 1993 Oct;3(5):313-6. PMID: 8292588; X-1

854. Ramadwar RH, Deshmukh SS, Oak SN, et al. Infantile hemangioendothelioma of the liver in a neonate. Indian Pediatr. 1993 Dec;30(12):1441-4. PMID: 8077034; X-1, X-2

855. Ramon F, Degryse H, De Schepper A. Intramuscular haemangioma. J Belge Radiol. 1993 Dec;76(6):406. PMID: 8163449; X-1

856. Reese V, Frieden IJ, Paller AS, et al. Association of facial hemangiomas with Dandy-Walker and other posterior fossa malformations. J Pediatr. 1993 Mar;122(3):379-84. PMID: 8441091; X-2

857. Renfro L, Geronemus RG. Anatomical differences of port-wine stains in response to treatment with the pulsed dye laser. Arch Dermatol. 1993 Feb;129(2):182-8. PMID: 8434975; X-1

858. Robinson JR, Jr., Awad IA, Masaryk TJ, et al. Pathological heterogeneity of angiographically occult vascular malformations of the brain. Neurosurgery. 1993 Oct;33(4):547-54; discussion 54-5. PMID: 8232794; X-1

859. Rogalski R, Hensinger R, Loder R. Vascular abnormalities of the extremities: clinical findings and management. J Pediatr Orthop. 1993 Jan-Feb;13(1):9-14. PMID: 8416363; X-1

860. Rossiter JL, Hendrix RA, Tom LW, et al. Intramuscular hemangioma of the head and neck. Otolaryngol Head Neck Surg. 1993 Jan;108(1):18-26. PMID: 8437870; X-2

861. Ruttum MS, Abrams GW, Harris GJ, et al. Bilateral retinal embolization associated with intralesional corticosteroid injection for capillary hemangioma of infancy. J Pediatr Ophthalmol Strabismus. 1993 Jan-Feb;30(1):4-7. PMID: 8455125; X-2

862. Schulman A. Intrahepatic biliary stones: imaging features and a possible relationship with ascaris lumbricoides. Clin Radiol. 1993 May;47(5):325-32. PMID: 8508594; X-1

863. Schulman SR, Jones BR, Slotnick N, et al. Fetal tracheal intubation with intact uteroplacental circulation. Anesth Analg. 1993 Jan;76(1):197-9. PMID: 8418725; X-1

864. Schwartz MZ, Silver H, Schulman S. Maintenance of the placental circulation to evaluate and treat an infant with massive head and neck hemangioma. J Pediatr Surg. 1993 Apr;28(4):520-2. PMID: 8483063; X-1, X-2

865. Seo W, Kishimoto M, Minato T, et al. Submandibular hemangioma as the initial manifestation of Kasabach-Merritt syndrome. Int J Pediatr Otorhinolaryngol. 1993 Jan;25(1-3):269-76. PMID: 8436476; X-2

866. Serna MJ, Vazquez-Doval J, Vanaclocha V, et al. Occult spinal dysraphism: a neurosurgical problem with a dermatologic hallmark. Pediatr Dermatol. 1993 Jun;10(2):149-52. PMID: 8346109; X-1

867. Sexton J, O'Hare D. Simplified treatment of vascular lesions using the argon laser. J Oral Maxillofac Surg. 1993 Jan;51(1):12-6. PMID: 8419567; X-1

868. Smith TP, Koci T, Mehringer CM, et al. Transarterial embolization of vertebral hemangioma. J Vasc Interv Radiol. 1993 Sep-Oct;4(5):681-5. PMID: 8219564; X-1

869. Stenninger E, Schollin J. Diffuse neonatal haemangiomatosis in a newborn child. Acta Paediatr. 1993 Jan;82(1):102-4. PMID: 8453203; X-1

870. Stoltenberg L, Rootwelt T, Oyasaeter S, et al. Hypoxanthine, xanthine, and uric acid concentrations in plasma, cerebrospinal fluid, vitreous humor, and urine in piglets subjected to intermittent versus continuous hypoxemia. Pediatr Res. 1993 Dec;34(6):767-71. PMID: 8108190; X-1

871. Taccone A, Tortori Donati P, Marzoli A, et al. Mucopolysaccharidosis: thickening of dura mater at the craniocervical junction and other CT/MRI findings. Pediatr Radiol. 1993;23(5):349-52. PMID: 8233683; X-1

872. Takato T, Komuro Y, Yonehara Y. Giant hemangioma of the parotid gland associated with Kasabach-Merritt syndrome: a case report. J Oral Maxillofac Surg. 1993 Apr;51(4):425-8. PMID: 8450364; X-1

873. Tawfik OW, Moral LA, Richardson WP, et al. Multicentric bilateral renal cell carcinomas and a vascular leiomyoma in a child. Pediatr Pathol. 1993 May-Jun;13(3):289-98. PMID: 8516223; X-1

874. Taylor MB. Can early therapy make a difference in treatment of strawberry hemangiomas? Clin Laser Mon. 1993 Jun;11(6):87-90. PMID: 10148820; X-4

875. Teillac-Hamel D, De Prost Y, Bodemer C, et al. Serious childhood angiomas: unsuccessful alpha-2b interferon treatment. A report of four cases. Br J Dermatol. 1993 Oct;129(4):473-6. PMID: 8217766; X-1

876. Telander RL, Ahlquist D, Blaufuss MC. Rectal mucosectomy: a definitive approach to extensive hemangiomas of the rectum. J Pediatr Surg. 1993 Mar;28(3):379-81. PMID: 8468650; X-1

877. Terada S, Suzuki N, Uchide K, et al. Vulvar angioleiomyoma. Arch Gynecol Obstet. 1993;253(1):51-8. PMID: 8392314; X-1

878. Tiacci C, D'Alessandro P, Cantisani TA, et al. Epilepsy with bilateral occipital calcifications: Sturge-Weber variant or a different encephalopathy? Epilepsia. 1993 May-Jun;34(3):528-39. PMID: 8504785; X-1

879. Tsao CY, Sommer A, Hamoudi AB. Aicardi syndrome, metastatic angiosarcoma of the leg, and scalp lipoma. Am J Med Genet. 1993 Mar 1;45(5):594-6. PMID: 8456830; X-1

880. Velez A, Herrera M, Del Rio E, et al. Gorham's syndrome. Int J Dermatol. 1993 Dec;32(12):884-7. PMID: 8125692; X-1

881. Vitale MK, Willwerth-Fortin J, Robbins K. Management of children on interferon therapy. Pediatr Nurs. 1993 May-Jun;19(3):230-4. PMID: 8511002; X-1, X-2

882. Walton JM, Rubin SZ, Soucy P, et al. Fetal tumors associated with hydrops: the role of the pediatric surgeon. J Pediatr Surg. 1993 Sep;28(9):1151-3. PMID: 8308682; X-1

883. Wheeland RG. Treatment of port-wine stains for the 1990s. J Dermatol Surg Oncol. 1993 Apr;19(4):348-56. PMID: 8478474; X-1

884. Wolf M, Engelberg S. Recurrent oral bleeding in Maffucci's syndrome: report of a case. J Oral Maxillofac Surg. 1993 May;51(5):596-7. PMID: 8478771; X-1

885. Yamamoto K, Tanaka T, Fujita T, et al. Intractable temporal lobe epilepsy with calcified mass in the temporal lobe. Jpn J Psychiatry Neurol. 1993 Jun;47(2):262-3. PMID: 8271558; X-1

886. Yang MT, Chen CH, Mak SC, et al. Arthrogryposis multiplex congenita: report of a case of amyoplasia. Zhonghua Min Guo Xiao Er Ke Yi Xue Hui Za Zhi. 1993 Mar-Apr;34(2):132-6. PMID: 8372669; X-1

887. Zukerberg LR, Nickoloff BJ, Weiss SW. Kaposiform hemangioendothelioma of infancy and childhood. An aggressive neoplasm associated with Kasabach-Merritt syndrome and lymphangiomatosis. Am J Surg Pathol. 1993 Apr;17(4):321-8. PMID: 8494101; X-1

888. Alster TS, Wilson F. Treatment of port-wine stains with the flashlamp-pumped pulsed dye laser: extended clinical experience in children and adults. Ann Plast Surg. 1994 May;32(5):478-84. PMID: 8060071; X-1

889. Apfelberg DB. Argon-pumped tunable dye laser. Ann Plast Surg. 1994 Apr;32(4):394-400. PMID: 8210159; X-1

890. Arisoy AE, Tunnessen WW, Jr. Pictures of the month. Case 2. Sturge-Weber syndrome. Arch Pediatr Adolesc Med. 1994 Sep;148(9):955-6. PMID: 8075741; X-1

891. Batra RK, Gulaya V, Madan R, et al. Anaesthesia and the Sturge-Weber syndrome. Can J Anaesth. 1994 Feb;41(2):133-6. PMID: 7907531; X-1

892. Berger TM, Berger MF, Hoffman AD, et al. Imaging diagnosis and follow-up of infantile hepatic haemangioendothelioma: a case report. Eur J Pediatr. 1994 Feb;153(2):100-2. PMID: 8157013; X-1

893. Besnard M, Pariente D, Hadchouel M, et al. Portal cavernoma in congenital hepatic fibrosis. Angiographic reports of 10 pediatric cases. Pediatr Radiol. 1994;24(1):61-5. PMID: 8008502; X-1

894. Bromley B, Benacerraf BR. Solid masses on the fetal surface of the placenta: differential diagnosis and clinical outcome. J Ultrasound Med. 1994 Nov;13(11):883-6. PMID: 7837336; X-1

895. Bruns J, Eggers-Stroeder G, von Torklus D. Synovial hemangioma--a rare benign synovial tumor. Report of four cases. Knee Surg Sports Traumatol Arthrosc. 1994;2(3):186-9. PMID: 7584204; X-1

896. Castiglia PT. Hemangiomas. J Pediatr Health Care. 1994 May-Jun;8(3):130-1. PMID: 7799178; X-1, X-2

897. Cerda J, Luque Mialdea R, Soleto J, et al. Segmentary splenectomy of the lower tip because of spontaneous rupture of a splenic hemangioendothelioma in a new-born child--a case report. Eur J Pediatr Surg. 1994 Apr;4(2):113-5. PMID: 8025093; X-1

898. Damiano TR, Truwit CL, Dowd CF, et al. Posterior fossa venous angiomas with drainage through the brain stem. AJNR Am J Neuroradiol. 1994 Apr;15(4):643-52. PMID: 8010264; X-1

899. Day W. Topical anesthesia for birthmark removal. J Tenn Med Assoc. 1994 Mar;87(3):95-6. PMID: 8035599; X-1, X-2

900. Depierraz B, Ravussin P, Brossard E, et al. Percutaneous transtracheal jet ventilation for paediatric endoscopic laser treatment of laryngeal and subglottic lesions. Can J Anaesth. 1994 Dec;41(12):1200-7. PMID: 7867117; X-4

901. Devaney K, Vinh TN, Sweet DE. Skeletal-extraskeletal angiomatosis. A clinicopathological study of fourteen patients and nosologic considerations. J Bone Joint Surg Am. 1994 Jun;76(6):878-91. PMID: 8200895; X-1, X-3

902. Devaney K, Vinh TN, Sweet DE. Surface-based hemangiomas of bone. A review of 11 cases. Clin Orthop Relat Res. 1994 Mar(300):233-40. PMID: 8131341; X-1

903. Drigo P, Mammi I, Battistella PA, et al. Familial cerebral, hepatic, and retinal cavernous angiomas: a new syndrome. Childs Nerv Syst. 1994 May;10(4):205-9. PMID: 7923228; X-1

904. Dyall-Smith D, Ramsden A, Laurie S. Adams-Oliver syndrome: aplasia cutis congenita, terminal transverse limb defects and cutis marmorata telangiectatica congenita. Australas J Dermatol. 1994;35(1):19-22. PMID: 7998895; X-1

905. Egawa H, Berquist W, Garcia-Kennedy R, et al. Respiratory distress from benign liver tumors: a report of two unusual cases treated with hepatic transplantation. J Pediatr Gastroenterol Nutr. 1994 Jul;19(1):114-7. PMID: 7965461; X-1

906. Elsas FJ, Lewis AR. Topical treatment of periocular capillary hemangioma. J Pediatr Ophthalmol Strabismus. 1994 May-Jun;31(3):153-6. PMID: 7931948; X-2

907. Epstein RH, Halmi BH. Oxygen leakage around the laryngeal mask airway during laser treatment of port-wine stains in children. Anesth Analg. 1994 Mar;78(3):486-9. PMID: 8109765; X-1

908. Giulioni M, Acciarri N, Padovani R, et al. Surgical management of cavernous angiomas in children. Surg Neurol. 1994 Sep;42(3):194-9. PMID: 7940104; X-1

909. Harries RW. A rational approach to radiological screening in von Hippel-Lindau disease. J Med Screen. 1994 Apr;1(2):88-95. PMID: 8790493; X-1

910. Hochberg J, Ardenghy M, Pait TG. Scalp tourniquet. Br J Plast Surg. 1994 Apr;47(3):194-8. PMID: 8193859; X-1

911. Ito M, Kumamoto T, Yamamoto H, et al. A case report of placental hemangioma resulting in severe fetal distress. Acta Paediatr Jpn. 1994 Apr;36(2):207-11. PMID: 8203269; X-1

912. Iwanaka T, Tsuchida Y, Hashizume K, et al. Intralesional corticosteroid injection with short-term oral prednisolone for infantile hemangiomas of the eyelid and orbit. J Pediatr Surg. 1994 Apr;29(4):482-6. PMID: 8014798; X-2

913. Jamjoom ZA, Abdul-Aziz S, Jamjoom AH, et al. Subtentorial diverticulum of the third ventricle associated with a mural cavernous angioma in a child. Surg Neurol. 1994 Sep;42(3):211-7. PMID: 7940106; X-1

914. Jarzab G, Rozylo TK. The efficiency of cryosurgery in the treatment of maxillo-facial haemangiomata. Ann Univ Mariae Curie Sklodowska Med. 1994;49:151-3. PMID: 8771847; X-2

915. Julow J, Balint K, Gortvai P, et al. Posterior fossa haemangioblastomas. Acta Neurochir (Wien). 1994;128(1-4):109-14. PMID: 7847125; X-1

916. Klapper J. Headache in Sturge-Weber syndrome. Headache. 1994 Oct;34(9):521-2. PMID: 8002325; X-1

917. Klemme WR, James P, Skinner SR. Latent onset unilateral toe-walking secondary to hemangioma of the gastrocnemius. J Pediatr Orthop. 1994 Nov-Dec;14(6):773-5. PMID: 7814593; X-1

918. Kunkel EJ, Zager RP, Hausman CL, et al. An interdisciplinary group for parents of children with hemangiomas. Psychosomatics. 1994 Nov-Dec;35(6):524-32. PMID: 7809355; X-3

919. Kushner MS, Jampol LM, Haller JA. Cavernous hemangioma of the optic nerve. Retina. 1994;14(4):359-61. PMID: 7817031; X-1

920. Langmann A, Lindner S. Normalisation of asymmetric astigmatism after intralesional steroid injection for upper eye lid hemangioma in childhood. Doc Ophthalmol. 1994;87(3):283-90. PMID: 7835197; X-3, X-4

921. Latifi HR, Siegel MJ. Color Doppler flow imaging of pediatric soft tissue masses. J Ultrasound Med. 1994 Mar;13(3):165-9. PMID: 7932971; X-1

922. Laufer L, Cohen A. Sturge-Weber syndrome associated with a large left hemispheric arteriovenous malformation. Pediatr Radiol. 1994;24(4):272-3. PMID: 7800450; X-1

923. Lo LJ, Noordhoff MS, Chen YR. Cleft lip and hemangioma: a patient with Wolf-Hirschhorn syndrome. Ann Plast Surg. 1994 May;32(5):539-41. PMID: 8060081; X-2

924. Lundell M. Estimates of absorbed dose in different organs in children treated with radium for skin hemangiomas. Radiat Res. 1994 Dec;140(3):327-33. PMID: 7972684; X-3

925. Lundell M, Hakulinen T, Holm LE. Thyroid cancer after radiotherapy for skin hemangioma in infancy. Radiat Res. 1994 Dec;140(3):334-9. PMID: 7972685; X-3

926. Mancini J, de Schonen S, Deruelle C, et al. Face recognition in children with early right or left brain damage. Dev Med Child Neurol. 1994 Feb;36(2):156-66. PMID: 8132126; X-1

927. Manglani M, Chari G, Sharma U, et al. Successful treatment with cyclophosphamide in a large hepatic hemangioendothelioma. Indian Pediatr. 1994 Jul;31(7):875-7. PMID: 7890363; X-1

928. Misra D, Hewitt G, Potts SR, et al. Inguinal herniotomy in young infants, with emphasis on premature neonates. J Pediatr Surg. 1994 Nov;29(11):1496-8. PMID: 7844731; X-1

929. Norbash AM, Marks MP, Lane B. Correlation of pressure measurements with angiographic characteristics predisposing to hemorrhage and steal in cerebral arteriovenous malformations. AJNR Am J Neuroradiol. 1994 May;15(5):809-13. PMID: 8059646; X-1

930. Ohlms LA, Jones DT, McGill TJ, et al. Interferon alfa-2a therapy for airway hemangiomas. Ann Otol Rhinol Laryngol. 1994 Jan;103(1):1-8. PMID: 8291854; X-4

931. Pfeiffer N. Guidelines for treating different stages of hemangioma. J Clin Laser Med Surg. 1994 Aug;12(4):239-40. PMID: 10147487; X-1, X-2

932. Reyes AT, Kantrowitz AB, Issenberg HJ, et al. Use of neurosurgical techniques for removal of a cardiac tumor. Ann Thorac Surg. 1994 Mar;57(3):741-3. PMID: 8147651; X-2

933. Ricketts RR, Hatley RM, Corden BJ, et al. Interferon-alpha-2a for the treatment of complex hemangiomas of infancy and childhood. Ann Surg. 1994 Jun;219(6):605-12; discussion 12-4. PMID: 8203969; X-2

934. Roach ES, Riela AR, Chugani HT, et al. Sturge-Weber syndrome: recommendations for surgery. J Child Neurol. 1994 Apr;9(2):190-2. PMID: 8006373; X-1

935. Samii M, Klekamp J. Surgical results of 100 intramedullary tumors in relation to accompanying syringomyelia. Neurosurgery. 1994 Nov;35(5):865-73; discussion 73. PMID: 7838335; X-1

936. Seikaly H, Cuyler JP. Infantile subglottic hemangioma. J Otolaryngol. 1994 Apr;23(2):135-7. PMID: 8028072; X-3, X-4

937. Sheehan-Dare RA, Cotterill JA. Copper vapour laser (578 nm) and flashlamp-pumped pulsed tunable dye laser (585 nm) treatment of port wine stains: results of a comparative study using test sites. Br J Dermatol. 1994 Apr;130(4):478-82. PMID: 8186113; X-1

938. Sheu BC, Shyu MK, Lin YF, et al. Prenatal diagnosis and corticosteroid treatment of diffuse neonatal hemangiomatosis: case report. J Ultrasound Med. 1994 Jun;13(6):495-9. PMID: 8083954; X-1

939. Sie KC, McGill T, Healy GB. Subglottic hemangioma: ten years' experience with the carbon dioxide laser. Ann Otol Rhinol Laryngol. 1994 Mar;103(3):167-72. PMID: 8122831; X-3, X-4

940. Simonati A, Colamaria V, Bricolo A, et al. Microgyria associated with Sturge-Weber angiomatosis. Childs Nerv Syst. 1994 Aug;10(6):392-5. PMID: 7842427; X-1

941. Stefanova P, Chatalbashev N, Anastasov V. On combination treatment of hemangiomas in childhood. Folia Med (Plovdiv). 1994;36(3):41-7. PMID: 8566902; X-3, X-4

942. Suchet IB. Colour-flow Doppler artifacts in anechoic soft-tissue masses of infants. Can Assoc Radiol J. 1994 Jun;45(3):201-3. PMID: 8193966; X-1, X-2

943. Takahashi K, Mulliken JB, Kozakewich HP, et al. Cellular markers that distinguish the phases of hemangioma during infancy and childhood. J Clin Invest. 1994 Jun;93(6):2357-64. PMID: 7911127; X-1

944. Teske S, Ohlrich SJ, Gole G, et al. Treatment of orbital capillary haemangioma with interferon. Aust N Z J Ophthalmol. 1994 Feb;22(1):13-7. PMID: 7986264; X-2

945. Thompson DN, Taylor WF, Hayward RD. Silastic dural substitute: experience of its use in spinal and foramen magnum surgery. Br J Neurosurg. 1994;8(2):157-67. PMID: 7917087; X-1

946. Tomlinson FH, Houser OW, Scheithauer BW, et al. Angiographically occult vascular malformations: a correlative study of features on magnetic resonance imaging and histological examination. Neurosurgery. 1994 May;34(5):792-9; discussion 9-800. PMID: 8052376; X-1

947. Vachuanichsanong P, Malagon M, Moore ES. Childhood idiopathic hypercalciuria. International Pediatrics. 1994;9(1):40-8. PMID: 1994140095; X-1

948. van der Meulen JC, Gilbert M, Roddi R. Early excision of nasal hemangiomas: the L-approach. Plast Reconstr Surg. 1994 Sep;94(3):465-73; discussion 74-5. PMID: 8047598; X-2

949. Vaughn RY, Lesher JL, Jr., Chandler FW, et al. Histogenesis of vascular tumors in the Proteus syndrome. South Med J. 1994 Feb;87(2):228-32. PMID: 8115889; X-1

950. Verheggen R, Finkenstaedt M, Rittmeyer K, et al. Intra- and paraventricular arteriovenous malformations: symptomatology, neuroradiological diagnosis, surgical approach and postoperative results. Acta Neurochir (Wien). 1994;131(3-4):176-83. PMID: 7754817; X-1

951. Walker RS, Custer PL, Nerad JA. Surgical excision of periorbital capillary hemangiomas. Ophthalmology. 1994 Aug;101(8):1333-40. PMID: 8058277; X-3, X-4

952. Waner M, Suen JY, Dinehart S, et al. Laser photocoagulation of superficial proliferating hemangiomas. J Dermatol Surg Oncol. 1994 Jan;20(1):43-6. PMID: 8288807; X-4

953. Wong YC, Li YW, Chang MH. Gastrointestinal bleeding and paraparesis in blue rubber bleb nevus syndrome. Pediatr Radiol. 1994;24(8):600-1. PMID: 7724289; X-1

954. Wortsman J, Kumar V. Case report: idiopathic hypoparathyroidism co-existing with celiac disease: immunologic studies. Am J Med Sci. 1994 Jun;307(6):420-7. PMID: 8198149; X-1

955. Wu TJ, Teng RJ. Diffuse neonatal haemangiomatosis with intra-uterine haemorrhage and hydrops fetalis: a case report. Eur J Pediatr. 1994 Oct;153(10):759-61. PMID: 7813536; X-1

956. Zabramski JM, Wascher TM, Spetzler RF, et al. The natural history of familial cavernous malformations: results of an ongoing study. J Neurosurg. 1994 Mar;80(3):422-32. PMID: 8113854; X-1

957. Acciarri N, Giulioni M, Padovani R, et al. Surgical management of cerebral cavernous angiomas causing epilepsy. J Neurosurg Sci. 1995 Mar;39(1):13-20. PMID: 8568551; X-1

958. Aiba T, Koike T, Takeda N, et al. Intracranial cavernous malformations and skin angiomas associated with middle fossa arachnoid cyst: a report of three cases. Surg Neurol. 1995 Jan;43(1):31-3; discussion 4. PMID: 7701419; X-1

959. Aiba T, Tanaka R, Koike T, et al. Natural history of intracranial cavernous malformations. J Neurosurg. 1995 Jul;83(1):56-9. PMID: 7782850; X-1

960. Akagi S, Saito T, Ogawa R. Maffucci's syndrome involving hemangioma in the cervical spine. Spine. 1995 Jul 1;20(13):1510-4. PMID: 8623072; X-1

961. Apfelberg DB. Argon and YAG laser photocoagulation and excision of hemangiomas and vascular malformations of the nose. West J Med. 1995 Aug;163(2):122-7. PMID: 7571558; X-3, X-4

962. Apfelberg DB. Intralesional laser photocoagulation-steroids as an adjunct to surgery for massive hemangiomas and vascular malformations. Ann Plast Surg. 1995 Aug;35(2):144-8; discussion 9. PMID: 7486735; X-1

963. Azzena A, Vasoin F, Braghetto M, et al. High risk pregnancy in a patient with angioma of the corpus callosum. Clin Exp Obstet Gynecol. 1995;22(2):165-8. PMID: 7781185; X-1

964. Boothroyd AE, Carty H. The painless soft tissue mass in childhood--tumour or not? Postgrad Med J. 1995 Jan;71(831):10-6. PMID: 7708584; X-2

965. Bruce S, Downe L, Devonald K, et al. Noninvasive investigation of infantile hepatic hemangioma: a case study. Pediatrics. 1995 Apr;95(4):595-7. PMID: 7700764; X-1, X-2

966. Burton BK, Schulz CJ, Angle B, et al. An increased incidence of haemangiomas in infants born following chorionic villus sampling (CVS). Prenat Diagn. 1995 Mar;15(3):209-14. PMID: 7784377; X-1, X-2

967. Casey AT, Thomas DG, Harkness WF. Stereotactically-guided craniotomy for cavernous angiomas presenting wit epilepsy. Acta Neurochir (Wien). 1995;137(1-2):34-7. PMID: 8748865; X-1

968. Cervoni L, Artico M, Delfini R. Intraosseous cavernous hemangioma of the skull. Neurosurg Rev. 1995;18(1):61-4. PMID: 7566532; X-1

969. Chiu HH, Chen RL, Lin KH, et al. Recombinant alpha-interferon treatment of intracranial hemangioma and Kasabach-Merritt syndrome in an infant with cytomegalovirus. J Formos Med Assoc. 1995 May;94(5):261-6. PMID: 7613260; X-1, X-2

970. Cleary MA, Wraith JE. The presenting features of mucopolysaccharidosis type IH (Hurler syndrome). Acta Paediatr. 1995 Mar;84(3):337-9. PMID: 7780260; X-1

971. Cohen DS, Zubay GP, Goodman RR. Seizure outcome after lesionectomy for cavernous malformations. J Neurosurg. 1995 Aug;83(2):237-42. PMID: 7616268; X-1

972. Colon F, Upton J. Pediatric hand tumors. A review of 349 cases. Hand Clin. 1995 May;11(2):223-43. PMID: 7635884; X-1

973. Crecco M, Floris R, Vidiri A, et al. Venous angiomas: plain and contrast-enhanced MRI and MR angiography. Neuroradiology. 1995 Jan;37(1):20-4. PMID: 7708182; X-1

974. Cruz OA, Zarnegar SR, Myers SE. Treatment of periocular capillary hemangioma with topical clobetasol propionate. Ophthalmology. 1995 Dec;102(12):2012-5. PMID: 9098309; X-2

975. De Lorenzo RA, Fisher R. Infant with crying and fever. Ann Emerg Med. 1995 May;25(5):699-705. PMID: 7741353; X-1

976. de Lorimier AA. Sclerotherapy for venous malformations. J Pediatr Surg. 1995 Feb;30(2):188-93; discussion 94. PMID: 7738736; X-1

977. Fernandez GR, Munoz FJ, Padron C, et al. Microphthalmos, facial capillary hemangioma and Dandy-Walker malformation. Acta Ophthalmol Scand. 1995 Apr;73(2):173-5. PMID: 7656150; X-1, X-2

978. Ferrer FA, McKenna PH. Cavernous hemangioma of the scrotum: a rare benign genital tumor of childhood. J Urol. 1995 Apr;153(4):1262-4. PMID: 7869525; X-1

979. Frim DM, Ogilvy CS. Mutism and cerebellar dysarthria after brain stem surgery: case report. Neurosurgery. 1995 Apr;36(4):854-7. PMID: 7596521; X-1

980. Froehlich P, Stamm D, Floret D, et al. Management of subglottic haemangioma. Clin Otolaryngol Allied Sci. 1995 Aug;20(4):336-9. PMID: 8548966; X-4

981. Furman GI, Sills J, Zeltzer P, et al. Visual diagnosis casebook. Kasabach-Merritt syndrome. J Perinatol. 1995 May-Jun;15(3):242-5. PMID: 7666277; X-1

982. Geeze MA. Advanced practice case study: congenital hemangiomas. Semin Perioper Nurs. 1995 Apr;4(2):132-9. PMID: 7780418; X-1, X-2

983. Gil-Nagel A, Wilcox KJ, Stewart JM, et al. Familial cerebral cavernous angioma: clinical analysis of a family and phenotypic classification. Epilepsy Res. 1995 May;21(1):27-36. PMID: 7641673; X-1

984. Ginsbach G. Periorbital aesthetic surgery with the KTP laser. Aesthetic Plast Surg. 1995 Nov-Dec;19(6):505-9. PMID: 8638485; X-1

985. Giulioni M, Acciarri N, Padovani R, et al. Results of surgery in children with cerebral cavernous angiomas causing epilepsy. Br J Neurosurg. 1995 Apr;9(2):135-41. PMID: 7632358; X-1

986. Gregg CM, Wiatrak BJ, Koopmann CF, Jr. Management options for infantile subglottic hemangioma. Am J Otolaryngol. 1995 Nov-Dec;16(6):409-14. PMID: 8572258; X-2

987. Gunalp I, Gunduz K. Vascular tumors of the orbit. Doc Ophthalmol. 1995;89(4):337-45. PMID: 7493535; X-3, X-4

988. Hase T, Kodama M, Kishida A, et al. Successful management of infantile hepatic hilar hemangioendothelioma with obstructive jaundice and consumption coagulopathy. J Pediatr Surg. 1995 Oct;30(10):1485-7. PMID: 8786496; X-1

989. Hoeger PH, Helmke K, Winkler K. Chronic consumption coagulopathy due to an occult splenic haemangioma: Kasabach-Merritt syndrome. Eur J Pediatr. 1995 May;154(5):365-8. PMID: 7641767; X-1, X-2

990. Ichimura K, Nibu K, Tanaka T. Essentials of surgical treatment for intramasseteric hemangioma. Eur Arch Otorhinolaryngol. 1995;252(3):125-9. PMID: 7662343; X-1

991. Illum N, Karlsmark T, Svejgaard E, et al. Ulcerated haemangioma successfully treated with interferon alfa-2b and topical granulocyte-macrophage colony-stimulating factor. Dermatology. 1995;191(4):315-7. PMID: 8573929; X-1, X-2

992. Kane WJ, Morris S, Jackson IT, et al. Significant hemangiomas and vascular malformations of the head and neck: clinical management and treatment outcomes. Ann Plast Surg. 1995 Aug;35(2):133-43. PMID: 7486734; X-3, X-4

993. Kaplan M, Paller AS. Clinical pearl: use of self-adhesive, compressive wraps in the treatment of limb hemangiomas. J Am Acad Dermatol. 1995 Jan;32(1):117-8. PMID: 7822500; X-1, X-2

994. Kasantikul V, Trivijitsilp P. Intrathoracic lymphangiohemangioma associated with hemothorax: a cause of intrauterine fetal death. J Med Assoc Thai. 1995 Feb;78(2):99-102. PMID: 7629452; X-1

995. Kattapong VJ, Hart BL, Davis LE. Familial cerebral cavernous angiomas: clinical and radiologic studies. Neurology. 1995 Mar;45(3 Pt 1):492-7. PMID: 7898703; X-1

996. Kida Y, Kobayashi T, Tanaka T. Treatment of symptomatic AOVMs with radiosurgery. Acta Neurochir Suppl. 1995;63:68-72. PMID: 7502732; X-1

997. Kondziolka D, Lunsford LD, Kestle JR. The natural history of cerebral cavernous malformations. J Neurosurg. 1995 Nov;83(5):820-4. PMID: 7472549; X-1

998. Lam CH, Farmer JP, Meagher-Villemure K, et al. Masson's vegetant haemangio-endothelioma. Pediatr Neurosurg. 1995;23(2):93-6. PMID: 8555102; X-1

999. Levine VJ, Geronemus RG. Adverse effects associated with the 577- and 585-nanometer pulsed dye laser in the treatment of cutaneous vascular lesions: a study of 500 patients. J Am Acad Dermatol. 1995 Apr;32(4):613-7. PMID: 7896952; X-1

1000. Lindberg S, Karlsson P, Arvidsson B, et al. Cancer incidence after radiotherapy for skin haemangioma during infancy. Acta Oncol. 1995;34(6):735-40. PMID: 7576739; X-3

1001. Lundell M, Holm LE. Risk of solid tumors after irradiation in infancy. Acta Oncol. 1995;34(6):727-34. PMID: 7576738; X-3

1002. MacArthur CJ, Senders CW, Katz J. The use of interferon alfa-2a for life-threatening hemangiomas. Arch Otolaryngol Head Neck Surg. 1995 Jun;121(6):690-3. PMID: 7772325; X-4

1003. Malozowski S, Tanner LA, Wysowski DK, et al. Benign intracranial hypertension in children with growth hormone deficiency treated with growth hormone. J Pediatr. 1995 Jun;126(6):996-9. PMID: 7776116; X-1

1004. Marks DS, Thomas AM, Thompson AG, et al. Surgical management of haemangioendothelioma of the spine. Eur Spine J. 1995;4(3):186-90. PMID: 7552654; X-1

1005. Martinez-Perez D, Fein NA, Boon LM, et al. Not all hemangiomas look like strawberries: uncommon presentations of the most common tumor of infancy. Pediatr Dermatol. 1995 Mar;12(1):1-6. PMID: 7792211; X-2

1006. Matschke RG. Experiences with laser surgery in benign and malignant findings of the oro- and hypopharynx. Adv Otorhinolaryngol. 1995;49:153-7. PMID: 7653353; X-1, X-2

1007. Matz P, McDermott M, Gutin P, et al. Cavernous malformations: results of image-guided resection. J Image Guid Surg. 1995;1(5):273-9. PMID: 9080347; X-1

1008. McNamara T, Trotman CA, Hewson A, et al. Facial developmental vascular anomalies. Spec Care Dentist. 1995 May-Jun;15(3):107-12. PMID: 8619171; X-1

1009. Mejides AA, Adra AM, O'Sullivan MJ, et al. Prenatal diagnosis and therapy for a fetal hepatic vascular malformation. Obstet Gynecol. 1995 May;85(5 Pt 2):850-3. PMID: 7724135; X-1

1010. Mikola E, Yang Z, Merkel K, et al. A 7-year-old girl with a growth disturbance in the extremities. Am J Orthop (Belle Mead NJ). 1995 Apr;24(4):360-3. PMID: 7788317; X-1

1011. Misra D, Hewitt G, Potts SR, et al. Transperitoneal closure of the internal ring in incarcerated infantile inguinal hernias. J Pediatr Surg. 1995 Jan;30(1):95-6. PMID: 7722840; X-1

1012. Montes JL, Rosenblatt B, Farmer JP, et al. Lesionectomy of MRI detected lesions in children with epilepsy. Pediatr Neurosurg. 1995;22(4):167-73. PMID: 7619716; X-1

1013. Moran CA, Suster S. Mediastinal hemangiomas: a study of 18 cases with emphasis on the spectrum of morphological features. Hum Pathol. 1995 Apr;26(4):416-21. PMID: 7705821; X-3

1014. Motwani MV, Simon JW, Pickering JD, et al. Steroid injection versus conservative treatment of anisometropia amblyopia in juvenile adnexal hemangioma. J Pediatr Ophthalmol Strabismus. 1995 Jan-Feb;32(1):26-8. PMID: 7752030; X-4

1015. Mysore J, Roth LM, Kafrawy AH. Turner's syndrome in association with hemangioma of the parotid gland: report of case. ASDC J Dent Child. 1995 Jan-Feb;62(1):67-9. PMID: 7775687; X-1

1016. Neubert AG, Golden MA, Rose NC. Kasabach-Merritt coagulopathy complicating Klippel-Trenaunay-Weber syndrome in pregnancy. Obstet Gynecol. 1995 May;85(5 Pt 2):831-3. PMID: 7724128; X-1

1017. Ogasawara KK, Ogasawara EM, Hirata G. Pregnancy complicated by von Hippel-Lindau disease. Obstet Gynecol. 1995 May;85(5 Pt 2):829-31. PMID: 7724127; X-1

1018. Onizuka K, Tsuneda K, Shibata Y, et al. Efficacy of flashlamp-pumped pulsed dye laser therapy for port wine stains: clinical assessment and histopathological characteristics. Br J Plast Surg. 1995 Jul;48(5):271-9. PMID: 7633763; X-1

1019. Park KC, Ahn PS, Lee YS, et al. Treatment of angioblastoma with recombinant interferon-alpha 2. Pediatr Dermatol. 1995 Jun;12(2):184-6. PMID: 7659649; X-1

1020. Rampini P, Occella C, Bleidl D, et al. Interferon alfa-2b therapy for extensive vision-threatening facial hemangioma. Nouvelles Dermatologiques. 1995;14(8):502-4. PMID: 1995333191; X-2

1021. Rehan VK, Greenberg H, Fajardo C. Radiological case of the month. Hepatic hemangioendothelioma. Arch Pediatr Adolesc Med. 1995 Dec;149(12):1389-90. PMID: 7489079; X-1

1022. Reich DS, Wiatrak BJ. Upper airway obstruction in Sturge-Weber and Klippel-Trenaunay-Weber syndromes. Ann Otol Rhinol Laryngol. 1995 May;104(5):364-8. PMID: 7747906; X-1

1023. Reutens DC, Dubeau F, Melanson D, et al. Intractable partial epilepsy following low-dose scalp irradiation in infancy. Ann Neurol. 1995 Dec;38(6):951-4. PMID: 8526469; X-1, X-2

1024. Riss JM, Girard NJ, Proust H, et al. Diffuse choroidal hemangioma: report of a clinicopathological study in a 4-year-old boy. Ophthalmologica. 1995;209(5):284-8. PMID: 8570155; X-1

1025. Robbins RC, Chin C, Yun KL, et al. Arterial switch and resection of hepatic hemangioendothelioma. Ann Thorac Surg. 1995 Jun;59(6):1575-7. PMID: 7771849; X-1

1026. Rosenthal G, Snir M, Biedner B. Corticosteroid resistant orbital hemangioma with proptosis treated with interferon alfa-2-a and partial tarsorrhaphy. J Pediatr Ophthalmol Strabismus. 1995 Jan-Feb;32(1):50-1. PMID: 7752034; X-1, X-2

1027. Rozylo TK, Krupski W, Galkowska E. Ultrasonographic diagnostics of maxillo-facial haemangiomas. Ann Univ Mariae Curie Sklodowska Med. 1995;50:179-81. PMID: 9263504; X-1

1028. Rudy C. Newborn with port wine stain. J Pediatr Health Care. 1995 Sep-Oct;9(5):229, 37-8. PMID: 7562314; X-1

1029. Samuel M, Spitz L. Infantile hepatic hemangioendothelioma: the role of surgery. J Pediatr Surg. 1995 Oct;30(10):1425-9. PMID: 8786479; X-1

1030. Scheepers JH, Quaba AA. Does the pulsed tunable dye laser have a role in the management of infantile hemangiomas? Observations based on 3 years' experience. Plast Reconstr Surg. 1995 Feb;95(2):305-12. PMID: 7824610; X-3

1031. Schwager K, Waner M, Hohmann D. Hemangioma: differential diagnosis and necessary early laser treatment. Adv Otorhinolaryngol. 1995;49:70-4. PMID: 7653390; X-1, X-2

1032. Shields CL, Shields JA, Barrett J, et al. Vasoproliferative tumors of the ocular fundus. Classification and clinical manifestations in 103 patients. Arch Ophthalmol. 1995 May;113(5):615-23. PMID: 7748132; X-1

1033. Soma H, Watanabe Y, Hata T. Chorangiosis and chorangioma in three cohorts of placentas from Nepal, Tibet, and Japan. Reprod Fertil Dev. 1995;7(6):1533-8. PMID: 8743160; X-1

1034. Squires LA, Constantini S, Miller DC, et al. Hypothalamic hamartoma and the Pallister-Hall syndrome. Pediatr Neurosurg. 1995;22(6):303-8. PMID: 7577664; X-1

1035. Stover B, Laubenberger J, Niemeyer C, et al. Haemangiomatosis in children: value of MRI during therapy. Pediatr Radiol. 1995;25(2):123-6. PMID: 7541125; X-1

1036. Suarez SM, Pensler JM, Paller AS. Response of deep tufted angioma to interferon alfa. J Am Acad Dermatol. 1995 Jul;33(1):124-6. PMID: 7601929; X-1

1037. Sujansky E, Conradi S. Sturge-Weber syndrome: age of onset of seizures and glaucoma and the prognosis for affected children. J Child Neurol. 1995 Jan;10(1):49-58. PMID: 7769179; X-1

1038. Sung MW, Chang SO, Choi JH, et al. Bleomycin sclerotherapy in patients with congenital lymphatic malformation in the head and neck. Am J Otolaryngol. 1995 Jul-Aug;16(4):236-41. PMID: 7573743; X-1

1039. Tai PT, Jewell LD. Case report: mesenteric mixed haemangioma and lymphangioma; report of a case with 10 year follow-up after radiation treatment. Br J Radiol. 1995 Jun;68(810):657-61. PMID: 7627491; X-1

1040. Tepetes K, Selby R, Webb M, et al. Orthotopic liver transplantation for benign hepatic neoplasms. Arch Surg. 1995 Feb;130(2):153-6. PMID: 7848084; X-1

1041. Tew JM, Jr., Lewis AI, Reichert KW. Management strategies and surgical techniques for deep-seated supratentorial arteriovenous malformations. Neurosurgery. 1995 Jun;36(6):1065-72. PMID: 7643983; X-1

1042. Troilius A, Ljunggren B. Reflectance spectrophotometry in the objective assessment of dye laser-treated port-wine stains. Br J Dermatol. 1995 Feb;132(2):245-50. PMID: 7888361; X-1

1043. van Kasteren ME, van der Wurff AA, Palmen FM, et al. Epithelioid haemangioendothelioma of the lung: clinical and pathological pitfalls. Eur Respir J. 1995 Sep;8(9):1616-9. PMID: 8575593; X-1

1044. von Schweinitz D, Gluer S, Mildenberger H. Liver tumors in neonates and very young infants: diagnostic pitfalls and therapeutic problems. Eur J Pediatr Surg. 1995 Apr;5(2):72-6. PMID: 7542025; X-1

1045. West KW, Rescorla FJ, Scherer LR, 3rd, et al. Diagnosis and treatment of symptomatic breast masses in the pediatric population. J Pediatr Surg. 1995 Feb;30(2):182-6; discussion 6-7. PMID: 7738735; X-1

1046. Wong DC, Masel JP. Infantile hepatic haemangioendothelioma. Australas Radiol. 1995 May;39(2):140-4. PMID: 7605318; X-1

1047. Yeh KW, Jiang TH, Hung IJ. Interferon therapy in an infant with Kasabach-Merritt syndrome. Zhonghua Min Guo Xiao Er Ke Yi Xue Hui Za Zhi. 1995 Sep-Oct;36(5):368-72. PMID: 8607364; X-1

1048. Achilleos OA, Buist LJ, Kelly DA, et al. Unresectable hepatic tumors in childhood and the role of liver transplantation. J Pediatr Surg. 1996 Nov;31(11):1563-7. PMID: 8943124; X-1

1049. Adamsbaum C, Pinton F, Rolland Y, et al. Accelerated myelination in early Sturge-Weber syndrome: MRI-SPECT correlations. Pediatr Radiol. 1996 Nov;26(11):759-62. PMID: 8929371; X-1

1050. Albregts AE, Hebert AA, Aboul-Nasr RA, et al. Malignant rhabdoid tumor presenting as a hemangioma. Pediatr Dermatol. 1996 Nov-Dec;13(6):468-71. PMID: 8987055; X-1

1051. Awan S, Davenport M, Portmann B, et al. Angiosarcoma of the liver in children. J Pediatr Surg. 1996 Dec;31(12):1729-32. PMID: 8987004; X-1

1052. Barlow RJ, Walker NP, Markey AC. Treatment of proliferative haemangiomas with the 585 nm pulsed dye laser. Br J Dermatol. 1996 Apr;134(4):700-4. PMID: 8733375; X-4

1053. Boon LM, Enjolras O, Mulliken JB. Congenital hemangioma: evidence of accelerated involution. J Pediatr. 1996 Mar;128(3):329-35. PMID: 8774499; X-1

1054. Botash RJ, Oliphant M, Capaldo G. Imaging of congenital kaposiform retroperitoneal hemangioendothelioma associated with Kasabach-Merritt syndrome. Clin Imaging. 1996 Jan-Mar;20(1):17-20. PMID: 8846303; X-1

1055. Boulot P, Deschamps F, Montoya F, et al. Prenatal aspects of giant fetal cranial haemangio-endothelioma. Prenat Diagn. 1996 Apr;16(4):357-9. PMID: 8734813; X-1

1056. Calder CI, Raafat F, Buckels JA, et al. Orthotopic liver transplantation for type 2 hepatic infantile haemangioendothelioma. Histopathology. 1996 Mar;28(3):271-3. PMID: 8729050; X-1

1057. Canavese F, Cortese MG, Proietti L, et al. Bulky-pedunculated hemolymphangioma of the esophagus: rare case in a two-years old girl. Eur J Pediatr Surg. 1996 Jun;6(3):170-2. PMID: 8817212; X-1

1058. Ceballos-Quintal JM, Pinto-Escalante D, Castillo-Zapata I. A new case of Klippel-Trenaunay-Weber (KTW) syndrome: evidence of autosomal dominant inheritance. Am J Med Genet. 1996 Jun 14;63(3):426-7. PMID: 8737646; X-1, X-2

1059. Chang CJ, Achauer BM, Vander Kam VM. Laser treatment of complicated head and neck hemangiomas in infancy. Changgeng Yi Xue Za Zhi. 1996 Jun;19(2):135-41. PMID: 8828255; X-3

1060. Chung T, Hoffer FA, Burrows PE, et al. MR imaging of hepatic hemangiomas of infancy and changes seen with interferon alpha-2a treatment. Pediatr Radiol. 1996;26(5):341-8. PMID: 8657464; X-3, X-4

1061. Davis MM, Bugaieski EM, Heifetz SA. Pathological case of the month. Capillary hemangioma of the lung. Arch Pediatr Adolesc Med. 1996 Dec;150(12):1309-10. PMID: 8954007; X-1, X-2

1062. DeFilippo JL, Yu JS, Weis L, et al. Soft tissue hemangioma with adjacent periosteal reaction simulating a primary bone tumor. Skeletal Radiol. 1996 Feb;25(2):174-7. PMID: 8848750; X-1

1063. D'Ercole C, Cravello L, Boubli L, et al. Large chorioangioma associated with hydrops fetalis: prenatal diagnosis and management. Fetal Diagn Ther. 1996 Sep-Oct;11(5):357-60. PMID: 8894632; X-1

1064. Egbert JE, Schwartz GS, Walsh AW. Diagnosis and treatment of an ophthalmic artery occlusion during an intralesional injection of corticosteroid into an eyelid capillary hemangioma. Am J Ophthalmol. 1996 Jun;121(6):638-42. PMID: 8644806; X-1, X-2

1065. Ettlinger JJ, Fleming PJ, Joffe HS, et al. Cavernous haemangioma with Kasabach-Merritt syndrome: treatment with alpha-interferon. J R Soc Med. 1996 Jan;89(1):55p-6p. PMID: 8709089; X-1

1066. Fernandes ET, Manivel JC, Reinberg Y. Hematuria in a newborn infant caused by bladder hemangioma. Urology. 1996 Mar;47(3):412-5. PMID: 8633412; X-1, X-2

1067. Fok TF, Chan MS, Metreweli C, et al. Hepatic haemangioendothelioma presenting with early heart failure in a newborn: treatment with hepatic artery embolization and interferon. Acta Paediatr. 1996 Nov;85(11):1373-5. PMID: 8955471; X-1

1068. Foster TD, Gold MH. The successful use of the Photoderm VL in the treatment of a cavernous hemangioma in a dark-skinned infant. Minim Invasive Surg Nurs. 1996 Fall;10(3):102-4. PMID: 9025485; X-1

1069. Fremont S, Kanny G, Bieber S, et al. Identification of a masked allergen, alpha-lactalbumin, in baby-food cereal flour guaranteed free of cow's milk protein. Allergy. 1996 Oct;51(10):749-54. PMID: 8905005; X-1

1070. Frieden IJ, Reese V, Cohen D. PHACE syndrome. The association of posterior fossa brain malformations, hemangiomas, arterial anomalies, coarctation of the aorta and cardiac defects, and eye abnormalities. Arch Dermatol. 1996 Mar;132(3):307-11. PMID: 8607636; X-2

1071. Frim DM, Zec N, Golden J, et al. Immunohistochemically identifiable tissue plasminogen activator in cavernous angioma: mechanism for re-hemorrhage and lesion growth. Pediatr Neurosurg. 1996 Sep;25(3):137-41; discussion 41-2. PMID: 9144712; X-1

1072. Fujii M, Arisawa M, Morimoto M, et al. Supra- and infratentorial multiple cavernous angiomas in an infant: report with MR evaluation of an unusual case. Childs Nerv Syst. 1996 Sep;12(9):564-7. PMID: 8906376; X-1

1073. Griffiths PD, Boodram MB, Blaser S, et al. Abnormal ocular enhancement in Sturge-Weber syndrome: correlation of ocular MR and CT findings with clinical and intracranial imaging findings. AJNR Am J Neuroradiol. 1996 Apr;17(4):749-54. PMID: 8730196; X-1

1074. Hande AM, Nagpal RD. Cerebellar haemangioblastoma with extensive dissemination. Br J Neurosurg. 1996 Oct;10(5):507-11. PMID: 8922714; X-1

1075. Hijii T, Fukushige J, Tasaki K, et al. Interferon-alpha therapy for multiple hemangiomas associated with coarctation of the aorta. Heart Vessels. 1996;11(4):211-4. PMID: 9119811; X-1, X-2

1076. Hovius SE, Borg DH, Paans PR, et al. The diagnostic value of magnetic resonance imaging in combination with angiography in patients with vascular malformations: a prospective study. Ann Plast Surg. 1996 Sep;37(3):278-85. PMID: 8883726; X-1

1077. Hsiang JN, Ng HK, Tsang RK, et al. Dural cavernous angiomas in a child. Pediatr Neurosurg. 1996 Aug;25(2):105-8. PMID: 9075255; X-1

1078. Huber G, Henkes H, Hermes M, et al. Regional association of developmental venous anomalies with angiographically occult vascular malformations. Eur Radiol. 1996;6(1):30-7. PMID: 8797947; X-1

1079. Ishii H, Iwabuchi K, Kameya T, et al. Pulmonary capillary haemangiomatosis. Histopathology. 1996 Sep;29(3):275-8. PMID: 8884358; X-1, X-2

1080. Iyer CP, Stanley P, Mahour GH. Hepatic hemangiomas in infants and children: a review of 30 cases. Am Surg. 1996 May;62(5):356-60. PMID: 8615561; X-3, X-4

1081. Jenner G, Soderlund V, Bauer HF, et al. MR imaging of skeletal muscle hemangiomas. A report of 16 cases. Acta Radiol. 1996 Mar;37(2):140-4. PMID: 8600950; X-3, X-4

1082. Kasantikul V, Shuangshoti S, Panichabhongse V, et al. Combined angioma and glioma (angioglioma). J Surg Oncol. 1996 May;62(1):15-21. PMID: 8618395; X-1

1083. Kiff KM, Mok Q, Dunne J, et al. Steroids for intubated croup masking airway haemangioma. Arch Dis Child. 1996 Jan;74(1):66-7. PMID: 8660054; X-2

1084. Kleer CG, Unni KK, McLeod RA. Epithelioid hemangioendothelioma of bone. Am J Surg Pathol. 1996 Nov;20(11):1301-11. PMID: 8898834; X-1

1085. Koukkari MW, Vanefsky MA, Steinberg GK, et al. Phenytoin-related chorea in children with deep hemispheric vascular malformations. J Child Neurol. 1996 Nov;11(6):490-1. PMID: 9120230; X-1

1086. Lacour M, Syed S, Linward J, et al. Role of the pulsed dye laser in the management of ulcerated capillary haemangiomas. Arch Dis Child. 1996 Feb;74(2):161-3. PMID: 8660082; X-4

1087. Lauvetz RW, Malek RS, Husmann DA. Treatment of extensive urethral hemangioma with KTP/532 laser. Lasers Surg Med. 1996;18(1):92-5. PMID: 8850471; X-1

1088. Lawton MT, Golfinos JG, Spetzler RF. The contralateral transcallosal approach: experience with 32 patients. Neurosurgery. 1996 Oct;39(4):729-34; discussion 34-5. PMID: 8880765; X-1

1089. Leblanc R, Melanson D, Wilkinson RD. Hereditary neurocutaneous angiomatosis. Report of four cases. J Neurosurg. 1996 Dec;85(6):1135-42. PMID: 8929507; X-1

1090. Lundell M, Holm LE. Mortality from leukemia after irradiation in infancy for skin hemangioma. Radiat Res. 1996 May;145(5):595-601. PMID: 8619025; X-1, X-3

1091. Lundell M, Mattsson A, Hakulinen T, et al. Breast cancer after radiotherapy for skin hemangioma in infancy. Radiat Res. 1996 Feb;145(2):225-30. PMID: 8606933; X-3

1092. Mathiesen T, Lindquist C, Kihlstrom L. Microsurgery with the Steiner-Lindquist stereotaxic guide. Br J Neurosurg. 1996 Apr;10(2):155-60. PMID: 8861306; X-2

1093. McCannel CA, Hoenig J, Umlas J, et al. Orbital lesions in the blue rubber bleb nevus syndrome. Ophthalmology. 1996 Jun;103(6):933-6. PMID: 8643250; X-1

1094. Montan S, Anandakumar C, Joseph R, et al. Fetal and neonatal haemodilution associated with multiple placental chorioangioma: case report. J Obstet Gynaecol Res. 1996 Feb;22(1):43-6. PMID: 8624891; X-1

1095. Ohlms LA, Forsen J, Burrows PE. Venous malformation of the pediatric airway. Int J Pediatr Otorhinolaryngol. 1996 Oct;37(2):99-114. PMID: 8894808; X-1

1096. Pascual-Castroviejo I, Viano J, Moreno F, et al. Hemangiomas of the head, neck, and chest with associated vascular and brain anomalies: a complex neurocutaneous syndrome. AJNR Am J Neuroradiol. 1996 Mar;17(3):461-71. PMID: 8881240; X-1

1097. Perrone HC, Toporovski J, Schor N. Urinary inhibitors of crystallization in hypercalciuric children with hematuria and nephrolithiasis. Pediatr Nephrol. 1996 Aug;10(4):435-7. PMID: 8865237; X-1

1098. Pitanguy I, Machado BH, Radwanski HN, et al. Surgical treatment of hemangiomas of the nose. Ann Plast Surg. 1996 Jun;36(6):586-92; discussion 92-3. PMID: 8792967; X-1

1099. Pozzati E, Acciarri N, Tognetti F, et al. Growth, subsequent bleeding, and de novo appearance of cerebral cavernous angiomas. Neurosurgery. 1996 Apr;38(4):662-9; discussion 9-70. PMID: 8692382; X-1

1100. Pozzati E, Giangaspero F, Marliani F, et al. Occult cerebrovascular malformations after irradiation. Neurosurgery. 1996 Oct;39(4):677-82; discussion 82-4. PMID: 8880758; X-1

1101. Prayson RA, Grewal ID, McMahon JT, et al. Leukocyte adhesion molecules and x-ray energy dispersive spectroscopy in Sturge-Weber disease. Pediatr Neurol. 1996 Nov;15(4):332-6. PMID: 8972534; X-1

1102. Sabhikhi AK, Chaudhury MC, Singh D, et al. Chorangioma of the placenta with hydrops fetalis. Indian Pediatr. 1996 Jun;33(6):520-1. PMID: 8979617; X-1

1103. Sawin PD, Follett KA, Wen BC, et al. Symptomatic intrasellar hemangioblastoma in a child treated with subtotal resection and adjuvant radiosurgery. Case report. J Neurosurg. 1996 Jun;84(6):1046-50. PMID: 8847570; X-1

1104. Seawright AA, Sullivan TJ, Pelekanos JT, et al. Coexistent orbital and cerebellar venous anomalies in linear sebaceous naevus syndrome. Aust N Z J Ophthalmol. 1996 Nov;24(4):373-6. PMID: 8985552; X-1

1105. Serrano M, Iglesias A, San Millan J. Long-term response to radiotherapy of vertebral hemangioma resulting in paraplegia. Acta Oncol. 1996;35(4):498-9. PMID: 8695171; X-1, X-2

1106. Shevell MI, Rosenblatt B, Watters GV, et al. "Pseudo-BECRS": intracranial focal lesions suggestive of a primary partial epilepsy syndrome. Pediatr Neurol. 1996 Jan;14(1):31-5. PMID: 8652012; X-1

1107. Soumekh B, Adams GL, Shapiro RS. Treatment of head and neck hemangiomas with recombinant interferon alpha 2B. Ann Otol Rhinol Laryngol. 1996 Mar;105(3):201-6. PMID: 8615583; X-4

1108. Sreeram N, Miller P, John P. Detachable balloon occlusion of vascular malformations in young patients. Int J Cardiol. 1996 Oct 11;56(2):119-24. PMID: 8894781; X-1, X-2

1109. Stokes RB, Saunders CJ, Thaller SR. Bregmatic masses in children. J Craniofac Surg. 1996 May;7(3):204-6. PMID: 9086886; X-1

1110. Uchino A, Hasuo K, Matsumoto S, et al. Cerebral venous angiomas associated with hemorrhagic lesions. Their MRI manifestations. Clin Imaging. 1996 Jul-Sep;20(3):157-63. PMID: 8877166; X-1

1111. Urgelles E, Pascual-Castroviejo I, Roche C, et al. Arteriovenous malformation in hypomelanosis of Ito. Brain Dev. 1996 Jan-Feb;18(1):78-80. PMID: 8907350; X-1

1112. Ward DG, Wang W, Fesmire W, et al. A deep-tissue hemangioma presenting as a rapidly progressive expanding mass and thrombocytopenia in an infant. Pediatr Emerg Care. 1996 Dec;12(6):422-4. PMID: 8989790; X-2

1113. Wiatrak BJ, Reilly JS, Seid AB, et al. Open surgical excision of subglottic hemangioma in children. Int J Pediatr Otorhinolaryngol. 1996 Jan;34(1-2):191-206. PMID: 8770689; X-2

1114. Wiener ES, Touloukian RJ, Rodgers BM, et al. Hernia survey of the Section on Surgery of the American Academy of Pediatrics. J Pediatr Surg. 1996 Aug;31(8):1166-9. PMID: 8863257; X-1

1115. Wu JM, Lin CS, Wang JN, et al. Pulmonary cavernous hemangiomatosis treated with interferon alfa-2a. Pediatr Cardiol. 1996 Sep-Oct;17(5):332-4. PMID: 8660452; X-1

1116. Wu TJ, Teng RJ, Tsou Yau KI. Hepatic hemangioendothelioma: successful treatment with steroid in a very-low-birth-weight infant. Zhonghua Min Guo Xiao Er Ke Yi Xue Hui Za Zhi. 1996 Jan-Feb;37(1):56-8. PMID: 8936013; X-1

1117. Wyllie E, Comair YG, Kotagal P, et al. Epilepsy surgery in infants. Epilepsia. 1996 Jul;37(7):625-37. PMID: 8681894; X-1

1118. Zevgaridis D, van Velthoven V, Ebeling U, et al. Seizure control following surgery in supratentorial cavernous malformations: a retrospective study in 77 patients. Acta Neurochir (Wien). 1996;138(6):672-7. PMID: 8836281; X-1

1119. Zimmermann A, Baer HU. Fibrous tumor-liver interface in large hepatic neoplasms: its significance for tumor resection and enucleation. Liver Transpl Surg. 1996 May;2(3):192-9. PMID: 9346648; X-1

1120. . Management of hemangiomas. Pediatr Dermatol. 1997 Jan-Feb;14(1):57-83. PMID: 9050768; X-1, X-2

1121. . Double take. A collage of nevi. Consultant. 1997;37(7):1924--5, 8, 33-4 passim. PMID: X-1

1122. Achauer BM, Chang CJ, Vander Kam VM. Management of hemangioma of infancy: review of 245 patients. Plast Reconstr Surg. 1997 Apr;99(5):1301-8. PMID: 9105356; X-3

1123. Bajpai M, Kataria R, Gupta DK, et al. Occult spinal dysraphism. Indian J Pediatr. 1997 Nov-Dec;64(6 Suppl):62-7. PMID: 11129883; X-1

1124. Bauman NM, Burke DK, Smith RJ. Treatment of massive or life-threatening hemangiomas with recombinant alpha(2a)-interferon. Otolaryngol Head Neck Surg. 1997 Jul;117(1):99-110. PMID: 9230332; X-4

1125. Behnke J, Christen HJ, Mursch K, et al. Intra-axial endophytic tumors in the pons and/or medulla oblongata. II. Intraoperative findings, postoperative results, and 2-year follow up in 25 children. Childs Nerv Syst. 1997 Mar;13(3):135-46. PMID: 9137855; X-1

1126. Berard M, Sordello S, Ortega N, et al. Vascular endothelial growth factor confers a growth advantage in vitro and in vivo to stromal cells cultured from neonatal hemangiomas. Am J Pathol. 1997 Apr;150(4):1315-26. PMID: 9094988; X-1

1127. Bhatoe HS. Mutism, oropharyngeal apraxia and dysarthria after posterior fossa tumour excision. Br J Neurosurg. 1997 Aug;11(4):341-3. PMID: 9337934; X-1

1128. Blei F, Isakoff M, Deb G. The response of parotid hemangiomas to the use of systemic interferon alfa-2a or corticosteroids. Arch Otolaryngol Head Neck Surg. 1997 Aug;123(8):841-4. PMID: 9260550; X-3, X-4

1129. Brennan TD, Miller AS, Chen SY. Lymphangiomas of the oral cavity: a clinicopathologic, immunohistochemical, and electron-microscopic study. J Oral Maxillofac Surg. 1997 Sep;55(9):932-5. PMID: 9294501; X-1

1130. Brouwers MA, Peeters PM, de Jong KP, et al. Surgical treatment of giant haemangioma of the liver. Br J Surg. 1997 Mar;84(3):314-6. PMID: 9117293; X-1

1131. Capin DM, Gottlieb SM, Rosman NP. Central nervous system hemangiomatosis in early childhood. Pediatr Neurol. 1997 Nov;17(4):365-70. PMID: 9436805; X-1, X-2

1132. Cappabianca P, Alfieri A, Maiuri F, et al. Supratentorial cavernous malformations and epilepsy: seizure outcome after lesionectomy on a series of 35 patients. Clin Neurol Neurosurg. 1997 Aug;99(3):179-83. PMID: 9350398; X-1

1133. Castello MA, Ragni G, Antimi A, et al. Successful management with interferon alpha-2a after prednisone therapy failure in an infant with a giant cavernous hemangioma. Med Pediatr Oncol. 1997 Mar;28(3):213-5. PMID: 9024520; X-1

1134. Cattini Perrone H, Bruder Stapleton F, Toporovski J, et al. Hematuria due to hyperuricosuria in children: 36-month follow-up. Clin Nephrol. 1997 Nov;48(5):288-91. PMID: 9403212; X-1

1135. Chang B, Gu H, Qian H, et al. Treatment of cutaneous hemangiomas with low-dose soft x-ray. Chin Med J (Engl). 1997 Nov;110(11):893-4. PMID: 9772427; X-1

1136. Chang CJ, Achauer BM, VanderKam VM. Reconstruction of head and neck hemangiomas with tissue expansion in the pediatric population. Ann Plast Surg. 1997 Jan;38(1):15-8. PMID: 9015533; X-3, X-4

1137. Chang E, Boyd A, Nelson CC, et al. Successful treatment of infantile hemangiomas with interferon-alpha-2b. J Pediatr Hematol Oncol. 1997 May-Jun;19(3):237-44. PMID: 9201147; X-2

1138. Cheung DS, Warman ML, Mulliken JB. Hemangioma in twins. Ann Plast Surg. 1997 Mar;38(3):269-74. PMID: 9088466; X-2, X-3

1139. Chia J, Teh M, Pho RW. Haemangioendothelioma in an infant's wrist. J Hand Surg Br. 1997 Feb;22(1):119-21. PMID: 9061545; X-1

1140. Chiron C, Jambaque I, Nabbout R, et al. The right brain hemisphere is dominant in human infants. Brain. 1997 Jun;120 (Pt 6):1057-65. PMID: 9217688; X-1

1141. Cunha e Sa M, Barroso CP, Caldas MC, et al. Innervation pattern of malformative cortical vessels in Sturge-Weber disease: an histochemical, immunohistochemical, and ultrastructural study. Neurosurgery. 1997 Oct;41(4):872-6; discussion 6-7. PMID: 9316049; X-1

1142. Deb G, Jenkner A, De Sio L, et al. Spindle cell (Kaposiform) hemangioendothelioma with Kasabach-Merritt syndrome in an infant: successful treatment with alpha-2A interferon. Med Pediatr Oncol. 1997 May;28(5):358-61. PMID: 9121401; X-1

1143. Demiriz M, Tunca Y, Ozcan A, et al. Placental chorioangioma associated with fetal cardiac complication. Acta Obstet Gynecol Scand. 1997 Aug;76(7):708-9. PMID: 9292650; X-1

1144. Di Rocco C, Iannelli A, Tamburrini G. Surgical management of paediatric cerebral cavernomas. J Neurosurg Sci. 1997 Dec;41(4):343-7. PMID: 9555641; X-1

1145. Dixon JJ, James D, Fleming PJ, et al. A novel method for estimating the volume of capillary haemangioma to determine response to treatment. Clin Exp Dermatol. 1997 Jan;22(1):20-2. PMID: 9330047; X-2

1146. Eliashar R, Saah D, Osin P, et al. Hemangioendothelioma of the temporal bone in a child. Int J Pediatr Otorhinolaryngol. 1997 May 4;40(1):67-71. PMID: 9184980; X-1

1147. Elsner P, Dummer R. Signs of methaemoglobinaemia after topical application of EMLA cream in an infant with haemangioma. Dermatology. 1997;195(2):153-4. PMID: 9310724; X-1, X-2

1148. Emoto M, Tamura R, Izumi H, et al. Sonodynamic changes after transcatheter arterial embolization in a vaginal hemangioma: case report. Ultrasound Obstet Gynecol. 1997 Jul;10(1):66-7. PMID: 9263427; X-1

1149. Enjolras O, Gelbert F. Superficial hemangiomas: associations and management. Pediatr Dermatol. 1997 May-Jun;14(3):173-9. PMID: 9192407; X-3, X-4

1150. Enjolras O, Wassef M, Mazoyer E, et al. Infants with Kasabach-Merritt syndrome do not have "true" hemangiomas. J Pediatr. 1997 Apr;130(4):631-40. PMID: 9108863; X-1

1151. Esassolak M, Yalman D, Aras AB, et al. Radiotherapy in Kasabach-Merritt syndrome. Radiography. 1997;3(2):149-53. PMID: X-1

1152. Evole-Buselli M, Hernandez-Marti MJ, Gasco-Lacalle B, et al. Neonatal dermal hematopoiesis associated with diffuse neonatal hemangiomatosis. Pediatr Dermatol. 1997 Sep-Oct;14(5):383-6. PMID: 9336812; X-1

1153. Fan J, Yang P. Versatility of expanded forehead flaps for facial reconstruction. Case report. Scand J Plast Reconstr Surg Hand Surg. 1997 Dec;31(4):357-63. PMID: 9444714; X-1

1154. Gangopadhyay AN, Sinha CK, Gopal SC, et al. Role of steroid in childhood haemangioma: a 10 years review. Int Surg. 1997 Jan-Mar;82(1):49-51. PMID: 9189802; X-3, X-4

1155. Gdal-On M, Gelfand YA. Cryoextraction of orbital capillary hemangioma diagnosed by technetium-99m-labeled red blood cell scintigraphy. Ophthalmic Surg Lasers. 1997 Nov;28(11):954-6. PMID: 9387184; X-2

1156. Griffiths PD, Boodram MB, Blaser S, et al. 99mTechnetium HMPAO imaging in children with the Sturge-Weber syndrome: a study of nine cases with CT and MRI correlation. Neuroradiology. 1997 Mar;39(3):219-24. PMID: 9106299; X-1

1157. Hastings MM, Milot J, Barsoum-Homsy M, et al. Recombinant interferon alfa-2b in the treatment of vision-threatening capillary hemangiomas in childhood. J aapos. 1997 Dec;1(4):226-30. PMID: 10532768; X-4

1158. Herman TE, McAlister PW, Dehner LP, et al. Beckwith-Wiedemann syndrome and splenic hemangioma: report of a case. Pediatr Radiol. 1997 Apr;27(4):350-2. PMID: 9094248; X-1

1159. Higano S, Takahashi S, Kurihara N, et al. Supratentorial primary intra-axial tumors in children. MR and CT evaluation. Acta Radiol. 1997 Nov;38(6):945-52. PMID: 9394647; X-1

1160. Hoeve LJ, Kuppers GL, Verwoerd CD. Management of infantile subglottic hemangioma: laser vaporization, submucous resection, intubation, or intralesional steroids? Int J Pediatr Otorhinolaryngol. 1997 Dec 10;42(2):179-86. PMID: 9692627; X-3, X-4

1161. Horigome H, Hamada H, Sohda S, et al. Large placental chorioangiomas as a cause of cardiac failure in two fetuses. Fetal Diagn Ther. 1997 Jul-Aug;12(4):241-3. PMID: 9354885; X-1

1162. Huang JS, Chen CC, Wu YM, et al. Periodontal manifestations and treatment of Sturge-Weber syndrome--report of two cases. Kaohsiung J Med Sci. 1997 Feb;13(2):127-35. PMID: 9099052; X-1

1163. Huang MH, Cohen SR, Burstein FD, et al. Endoscopic pediatric plastic surgery. Ann Plast Surg. 1997 Jan;38(1):1-8. PMID: 9015531; X-1

1164. Humpl T, Bruhl K, Bohl J, et al. Cerebral haemorrhage in long-term survivors of childhood acute lymphoblastic leukaemia. Eur J Pediatr. 1997 May;156(5):367-70. PMID: 9177978; X-1

1165. Hundt C, Auberger K, Munch G, et al. Brain hemangiomas of infancy. Sonographic detection and follow-up. J Neuroimaging. 1997 Apr;7(2):81-5. PMID: 9128444; X-2

1166. Inoue Y, Ohtake T, Wakita S, et al. Flow characteristics of soft-tissue vascular anomalies evaluated by direct puncture scintigraphy. Eur J Nucl Med. 1997 May;24(5):505-10. PMID: 9142730; X-1

1167. Iplikcioglu AC, Yaradanakul V, Trakya U. Supratentorial haemangioblastoma: appearances on MR imaging. Br J Neurosurg. 1997 Dec;11(6):576-8. PMID: 11013633; X-1

1168. Itosaka H, Tada M, Sawamura Y, et al. Vanishing tumor of the temporalis muscle: repeated hemorrhage in an intramuscular venous hemangioma. AJNR Am J Neuroradiol. 1997 May;18(5):983-5. PMID: 9159382; X-1

1169. Jayakumar PN, Vasudev MK, Srikanth SG. Symptomatic vertebral haemangioma: endovascular treatment of 12 patients. Spinal Cord. 1997 Sep;35(9):624-8. PMID: 9300972; X-1

1170. Kai Y, Kuratsu J, Suginohara K, et al. Cerebellar mutism after posterior fossa surgery--two case reports. Neurol Med Chir (Tokyo). 1997 Dec;37(12):929-33. PMID: 9465594; X-1

1171. Kakkar N, Vasishta RK, Banerjee AK, et al. Pulmonary capillary haemangiomatosis as a cause of pulmonary hypertension in Takayasu's aortoarteritis. Respiration. 1997;64(5):381-3. PMID: 9311057; X-1

1172. Kane JW, Page-Salyards W, Perry CR. Congenital hepatic hemangioma in the neonate. MCN Am J Matern Child Nurs. 1997 Jul-Aug;22(4):187-93. PMID: 9234606; X-2

1173. Kaplan DL. Dermclinic. Cutaneous conundrums, dermatologic disguises. Consultant. 1997;37(5):1206--8, 18, 20 passim. PMID: X-1

1174. Karasawa H, Furuya H, Naito H, et al. Acute hydrocephalus in posterior fossa injury. J Neurosurg. 1997 Apr;86(4):629-32. PMID: 9120626; X-1

1175. Karlsson P, Holmberg E, Lundberg LM, et al. Intracranial tumors after radium treatment for skin hemangioma during infancy--a cohort and case-control study. Radiat Res. 1997 Aug;148(2):161-7. PMID: 9254735; X-1

1176. Kempinaire A, De Raeve L, Roseeuw D, et al. Capillary-venous malformation in the labia majora in a 12-year-old girl. Dermatology. 1997;194(4):405-7. PMID: 9252777; X-1

1177. Kullendorff CM. Efficacy of bleomycin treatment for symptomatic hemangiomas in children. Pediatr Surg Int. 1997 Sep;12(7):526-8. PMID: 9238123; X-1, X-2

1178. Liang MG, Frieden IJ. Perineal and lip ulcerations as the presenting manifestation of hemangioma of infancy. Pediatrics. 1997 Feb;99(2):256-9. PMID: 9024458; X-2

1179. Maggi G, Aliberti F, Ruggiero C, et al. Cerebral cavernous angiomas in critical areas. Reports of three cases in children. J Neurosurg Sci. 1997 Dec;41(4):353-7. PMID: 9555643; X-1

1180. Matsui T, Ono T, Kito M, et al. Extensive facial strawberry mark associated with cerebellar hypoplasia and vascular abnormalities. J Dermatol. 1997 Feb;24(2):113-6. PMID: 9065707; X-1, X-2

1181. Mendel T, Louis DS. Major vascular malformations of the upper extremity: long-term observation. J Hand Surg Am. 1997 Mar;22(2):302-6. PMID: 9195430; X-1

1182. Mendivil A, Cuartero V. Radiological case of the month. Choroidal hemangioma. Arch Pediatr Adolesc Med. 1997 Dec;151(12):1261-2. PMID: 9412605; X-1

1183. Mitsuhashi N, Furuta M, Sakurai H, et al. Outcome of radiation therapy for patients with Kasabach-Merritt syndrome. Int J Radiat Oncol Biol Phys. 1997 Sep 1;39(2):467-73. PMID: 9308952; X-1

1184. Mor Y, Hitchcock RJ, Zaidi SZ, et al. Bladder hemangioma as a cause of massive hematuria in a child. A case report and literature review. Scand J Urol Nephrol. 1997 Jun;31(3):305-7. PMID: 9249900; X-1

1185. Nako Y, Fukushima N, Igarashi T, et al. Successful interferon therapy in a neonate with life-threatening Kasabach-Merritt syndrome. J Perinatol. 1997 May-Jun;17(3):244-7. PMID: 9210084; X-1

1186. Neumann D, Isenberg SJ, Rosenbaum AL, et al. Ultrasonographically guided injection of corticosteroids for the treatment of retroseptal capillary hemangiomas in infants. J aapos. 1997 Mar;1(1):34-40. PMID: 10530983; X-2

1187. Novelli PM, Reigel DH, Langham Gleason P, et al. Multiple cavernous angiomas after high-dose whole-brain radiation therapy. Pediatr Neurosurg. 1997 Jun;26(6):322-5. PMID: 9485161; X-1

1188. O'Donovan JC, Donaldson JS, Morello FP, et al. Symptomatic hemangiomas and venous malformations in infants, children, and young adults: treatment with percutaneous injection of sodium tetradecyl sulfate. AJR Am J Roentgenol. 1997 Sep;169(3):723-9. PMID: 9275886; X-1

1189. Ogata N, Yonekawa Y. Paramedian supracerebellar approach to the upper brain stem and peduncular lesions. Neurosurgery. 1997 Jan;40(1):101-4; discussion 4-5. PMID: 8971831; X-1

1190. Okudaira Y, Arai H, Sato K. Hemodynamic compromise as a factor in clinical progression of Sturge-Weber syndrome. Childs Nerv Syst. 1997 Apr;13(4):214-9. PMID: 9202857; X-1

1191. Orlow SJ, Isakoff MS, Blei F. Increased risk of symptomatic hemangiomas of the airway in association with cutaneous hemangiomas in a "beard" distribution. J Pediatr. 1997 Oct;131(4):643-6. PMID: 9386676; X-3, X-4

1192. Paley MR, Farrant P, Kane P, et al. Developmental intrahepatic shunts of childhood: radiological features and management. Eur Radiol. 1997;7(9):1377-82. PMID: 9369502; X-1

1193. Pant B, Sumida M, Kurisu K, et al. Usefulness of two-dimensional time-of-flight MR angiography combined with surface anatomy scanning for convexity lesions. Neurosurg Rev. 1997;20(2):108-13. PMID: 9226669; X-1, X-2

1194. Patel SD, Cohen BA, Kan JS. Extensive facial hemangioma associated with cardiac and abdominal anomalies. J Am Acad Dermatol. 1997 Apr;36(4):636-8. PMID: 9092757; X-2

1195. Plager DA, Snyder SK. Resolution of astigmatism after surgical resection of capillary hemangiomas in infants. Ophthalmology. 1997 Jul;104(7):1102-6. PMID: 9224460; X-2

1196. Polymeropoulos MH, Hurko O, Hsu F, et al. Linkage of the locus for cerebral cavernous hemangiomas to human chromosome 7q in four families of Mexican-American descent. Neurology. 1997 Mar;48(3):752-7. PMID: 9065560; X-1

1197. Sarihan H, Mocan H, Yildiz K, et al. A new treatment with bleomycin for complicated cutaneous hemangioma in children. Eur J Pediatr Surg. 1997 Jun;7(3):158-62. PMID: 9241503; X-4

1198. Sarkar M, Mulliken JB, Kozakewich HP, et al. Thrombocytopenic coagulopathy (Kasabach-Merritt phenomenon) is associated with Kaposiform hemangioendothelioma and not with common infantile hemangioma. Plast Reconstr Surg. 1997 Nov;100(6):1377-86. PMID: 9385948; X-1

1199. Sato M, Tanaka N, Sato T, et al. Oral and maxillofacial tumours in children: a review. Br J Oral Maxillofac Surg. 1997 Apr;35(2):92-5. PMID: 9146865; X-3, X-4

1200. Schiebe ME, Hoffmann W, Rebmann H, et al. Radiotherapy in the management of large childhood hemangiomas. European Journal of Pediatric Dermatology. 1997;7(3):159-62. PMID: 1998257779; X-2

1201. Sherrington CA, Sim DK, Freezer NJ, et al. Subglottic haemangioma. Arch Dis Child. 1997 May;76(5):458-9. PMID: 9196368; X-3, X-4

1202. Slaughenhoupt BL, Van Savage J. The evaluation and treatment of prolonged hematuria in adolescents. J Ky Med Assoc. 1997 Aug;95(8):315-7. PMID: 9291736; X-1

1203. Smit LM, Halbertsma FJ. Cerebral cavernous hemangiomas in childhood. Clinical presentation and therapeutic considerations. Childs Nerv Syst. 1997 Oct;13(10):522-5. PMID: 9403199; X-1

1204. Sweet C, Silbergleit R, Mehta B. Primary intraosseous hemangioma of the orbit: CT and MR appearance. AJNR Am J Neuroradiol. 1997 Feb;18(2):379-81. PMID: 9111679; X-1

1205. Tam WH, Fung HY, Fung TY, et al. Intra-uterine growth retardation and transverse lie due to massive subchorionic thrombohematoma and overlying large subchorionic cyst. Acta Obstet Gynecol Scand. 1997 Apr;76(4):381-3. PMID: 9174438; X-1

1206. Tammam AG, Lewis PD, Crockard HA. Cerebello-pontine angle epithelioid haemangioendothelioma in a 4-year-old boy. Childs Nerv Syst. 1997 Nov-Dec;13(11-12):648-50. PMID: 9454988; X-1

1207. Tanaka H, Patel U, Coniglio JU, et al. Solitary subglottic neurofibroma: MR findings. AJNR Am J Neuroradiol. 1997 Oct;18(9):1726-8. PMID: 9367323; X-1

1208. Uchida K, Takahashi A, Miyao N, et al. Juvenile hemangioma of the testis: analysis of expression of angiogenic factors. Urology. 1997 Feb;49(2):285-6. PMID: 9037300; X-2

1209. Uzzo RG, Bilsky M, Mininberg DT, et al. Laparoscopic surgery in children with ventriculoperitoneal shunts: effect of pneumoperitoneum on intracranial pressure--preliminary experience. Urology. 1997 May;49(5):753-7. PMID: 9145983; X-1

1210. Vanhooteghem O, Andre J, Bruderer P, et al. Tufted angioma, a particular form of angioma. Dermatology. 1997;194(4):402-4. PMID: 9252776; X-1

1211. Vargha-Khadem F, Carr LJ, Isaacs E, et al. Onset of speech after left hemispherectomy in a nine-year-old boy. Brain. 1997 Jan;120 (Pt 1):159-82. PMID: 9055805; X-1

1212. Vining EP, Freeman JM, Pillas DJ, et al. Why would you remove half a brain? The outcome of 58 children after hemispherectomy-the Johns Hopkins experience: 1968 to 1996. Pediatrics. 1997 Aug;100(2 Pt 1):163-71. PMID: 9240794; X-1

1213. Wang LH, Tang JR, Teng RJ, et al. Hydrops fetalis due to placental chorioangioma: report of one case. Zhonghua Min Guo Xiao Er Ke Yi Xue Hui Za Zhi. 1997 Mar-Apr;38(2):155-8. PMID: 9151471; X-1

1214. Wheeler HMD. Clinical issues in midwifery. Birthmarks, body image and their implications... this article is the first in a series of three. Br J Midwifery. 1997;5(5):272-6. PMID: X-1

1215. Wilde G, Sjostrand J. A clinical study of radiation cataract formation in adult life following gamma irradiation of the lens in early childhood. Br J Ophthalmol. 1997 Apr;81(4):261-6. PMID: 9215051; X-3, X-4

1216. Williams JK, Hitner JB, Wood RJ. Unilateral cleft lip repair in the presence of a vermilion hemangioma. Plast Reconstr Surg. 1997 Jan;99(1):230-3. PMID: 8982210; X-2

1217. Woltering MC, Robben S, Egeler RM. Hepatic hemangioendothelioma of infancy: treatment with interferon alpha. J Pediatr Gastroenterol Nutr. 1997 Mar;24(3):348-51. PMID: 9138183; X-1

1218. Yanai S, Tsutsumi H, Hotsubo T, et al. Development of a testicular haemangioma after interferon therapy for hepatic haemangiomas: a case report. Eur J Pediatr. 1997 Oct;156(10):784-6. PMID: 9365068; X-2

1219. Zamorano L, Matter A, Saenz A, et al. Interactive image-guided resection of cerebral cavernous malformations. Comput Aided Surg. 1997;2(6):327-32. PMID: 9587694; X-1

1220. . Photoclinic. Consultant. 1998;38(10):2544--7, 51-2, 54-5 passim. PMID: X-1

1221. Achauer BM, Celikoz B, VanderKam VM. Intralesional bare fiber laser treatment of hemangioma of infancy. Plast Reconstr Surg. 1998 Apr;101(5):1212-7. PMID: 9529203; X-4

1222. Albano G, Pugliese A, Stabile M, et al. Hydrops foetalis caused by hepatic haemangioma. Acta Paediatr. 1998 Dec;87(12):1307-9. PMID: 9894836; X-1

1223. Anger J, Carneiro RG, Pinus J, et al. The rebound effect in the treatment of complex hemangioma with interferon alpha 2A. Sao Paulo Med J. 1998 Sep-Oct;116(5):1826-8. PMID: 10030110; X-1, X-2

1224. Ankrett V. Picture quiz: skin lesion. Practice Nurse. 1998;15(2):106-. PMID: X-1

1225. Arnaout MK, Pappo AS. Kaposiform hemangioendothelioma with associated Kasabach-Merritt phenomenon. J Pediatr. 1998 Dec;133(6):788. PMID: 9842045; X-1

1226. Atuk NO, Stolle C, Owen JA, Jr., et al. Pheochromocytoma in von Hippel-Lindau disease: clinical presentation and mutation analysis in a large, multigenerational kindred. J Clin Endocrinol Metab. 1998 Jan;83(1):117-20. PMID: 9435426; X-1

1227. Bailey CM, Froehlich P, Hoeve HL. Management of subglottic haemangioma. J Laryngol Otol. 1998 Aug;112(8):765-8. PMID: 9850319; X-2

1228. Barlow CF, Priebe CJ, Mulliken JB, et al. Spastic diplegia as a complication of interferon Alfa-2a treatment of hemangiomas of infancy. J Pediatr. 1998 Mar;132(3 Pt 1):527-30. PMID: 9544915; X-2

1229. Beaubien ER, Ball NJ, Storwick GS. Kaposiform hemangioendothelioma: a locally aggressive vascular tumor. J Am Acad Dermatol. 1998 May;38(5 Pt 2):799-802. PMID: 9591789; X-1

1230. Bidzinski J, Marchel A. Lesionectomy in surgical treatment of epilepsy. Neurol Neurochir Pol. 1998;32 Suppl 2:69-79. PMID: 9757433; X-1

1231. Bonduel M, Sciuccati G, Torres AF, et al. Familial idiopathic myelofibrosis and multiple hemangiomas. Am J Hematol. 1998 Oct;59(2):175-7. PMID: 9766805; X-1

1232. Boriani S, Biagini R, De Iure F, et al. Resection surgery in the treatment of vertebral tumors. Chir Organi Mov. 1998 Jan-Jun;83(1-2):53-64. PMID: 9718815; X-1

1233. Brodwater BK, Queiroz R. Young male patient with atypical chest pain and cardiac mass on chest radiograph: case from A3CR2 film panel. Acad Radiol. 1998 Jan;5(1):69-71. PMID: 9442211; X-1

1234. Burrows PE, Robertson RL, Mulliken JB, et al. Cerebral vasculopathy and neurologic sequelae in infants with cervicofacial hemangioma: report of eight patients. Radiology. 1998 Jun;207(3):601-7. PMID: 9609880; X-1, X-2

1235. Carruthers J, Jevon G, Prendiville J. Localized dystrophic periocular calcification: a complication of intralesional corticosteroid therapy for infantile periocular hemangiomas. Pediatr Dermatol. 1998 Jan-Feb;15(1):23-6. PMID: 9496798; X-2

1236. Chang CJ, Anvari B, Nelson JS. Cryogen spray cooling for spatially selective photocoagulation of hemangiomas: a new methodology with preliminary clinical reports. Plast Reconstr Surg. 1998 Aug;102(2):459-63. PMID: 9703086; X-2

1237. Chaskis C, Brotchi J. The surgical management of cerebral cavernous angiomas. Neurol Res. 1998 Oct;20(7):597-606. PMID: 9785587; X-1

1238. Chatrath P, Pfleiderer AG, Blundell JW. A rare case of intramuscular haemangioma in a six-year-old boy--a diagnostic dilemma. J Laryngol Otol. 1998 Dec;112(12):1181-2. PMID: 10209617; X-1, X-2

1239. Cholewa D, Waldschmidt J. Laser treatment of hemangiomas of the larynx and trachea. Lasers Surg Med. 1998;23(4):221-32. PMID: 9829433; X-1

1240. Clymer MA, Fortune DS, Reinisch L, et al. Interstitial Nd:YAG photocoagulation for vascular malformations and hemangiomas in childhood. Arch Otolaryngol Head Neck Surg. 1998 Apr;124(4):431-6. PMID: 9559692; X-1

1241. Coley SC, Britton J, Clarke A. Status epilepticus and venous infarction in Sturge-Weber syndrome. Childs Nerv Syst. 1998 Dec;14(12):693-6. PMID: 9881620; X-1

1242. de-Medeiros BC, Strapasson E, Pasquini R, et al. Effect of all-trans retinoic acid on newly diagnosed acute promyelocytic leukemia patients: results of a Brazilian center. Braz J Med Biol Res. 1998 Dec;31(12):1537-43. PMID: 9951549; X-1

1243. Dubois J, Garel L, Grignon A, et al. Imaging of hemangiomas and vascular malformations in children. Acad Radiol. 1998 May;5(5):390-400. PMID: 9597107; X-1, X-2

1244. Dummer R, Graf P, Greif C, et al. Treatment of vascular lesions using the VersaPulse variable pulse width frequency doubled neodymium:YAG laser. Dermatology. 1998;197(2):158-61. PMID: 9732166; X-1

1245. Eggert P, Muller D, Schroter T. Nephrocalcinosis in three siblings with idiopathic hypercalciuria. Pediatr Nephrol. 1998 Feb;12(2):144-6. PMID: 9543376; X-1

1246. Fard AK, Traboulsi EI. Coloboma of the lens, optic nerve hypoplasia, and orbital hemangioma--a possible developmental field defect. Ophthalmic Genet. 1998 Dec;19(4):209-12. PMID: 9895246; X-1

1247. Fishman SJ, Burrows PE, Leichtner AM, et al. Gastrointestinal manifestations of vascular anomalies in childhood: varied etiologies require multiple therapeutic modalities. J Pediatr Surg. 1998 Jul;33(7):1163-7. PMID: 9694115; X-2

1248. Fitzgerald JF, Troncone R, Caprai S, et al. Clinical quiz. Infantile haemangioendothelioma. J Pediatr Gastroenterol Nutr. 1998 Jul;27(1):85, 113. PMID: 9669731; X-1

1249. Forte V, Triglia JM, Zalzal G. Hemangioma. Head Neck. 1998 Jan;20(1):69-72. PMID: 9464955; X-2

1250. Fukui M, Matsushima T, Ikezaki K, et al. Surgery of angiomas in the brainstem with a stress on the presence of telangiectasia. Neurol Med Chir (Tokyo). 1998;38 Suppl:250-4. PMID: 10235014; X-1

1251. Gaab MR, Schroeder HW. Neuroendoscopic approach to intraventricular lesions. J Neurosurg. 1998 Mar;88(3):496-505. PMID: 9488304; X-1

1252. Giannini C, Scheithauer BW, Hellbusch LC, et al. Peripheral nerve hemangioblastoma. Mod Pathol. 1998 Oct;11(10):999-1004. PMID: 9796730; X-1

1253. Grieve JP, Wilkins PR, Marsh HT. Neurenteric sinus dorsal to the thoracic spine with an associated cutaneous haemangioma: case report. Br J Neurosurg. 1998 Jun;12(3):259-63. PMID: 11013691; X-1, X-2

1254. Haga N, Nakamura K, Taniguchi K, et al. Enchondromatosis with features of dysspondyloenchondromatosis and Maffucci syndrome. Clin Dysmorphol. 1998 Jan;7(1):65-8. PMID: 9546836; X-1

1255. Han SJ, Tsai CC, Tsai HM, et al. Infantile hemangioendothelioma with a highly elevated serum alpha-fetoprotein level. Hepatogastroenterology. 1998 Mar-Apr;45(20):459-61. PMID: 9638427; X-1

1256. Haramoto U, Yamada A, Kobayashi S, et al. Quarter vermillion flap: a method for symmetrical lower vermillion reconstruction. Plast Reconstr Surg. 1998 Apr;101(5):1334-7. PMID: 9529221; X-1

1257. Hart YM, Andermann F, Robitaille Y, et al. Double pathology in Rasmussen's syndrome: a window on the etiology? Neurology. 1998 Mar;50(3):731-5. PMID: 9521265; X-1

1258. Hassan E, Giannakopoulou C, Stefanaki K, et al. Congenital capillary hemangioma and its therapeutic approach in infants: a case report. J Dermatol. 1998 Oct;25(10):673-6. PMID: 9830268; X-1

1259. Hata D, Isu T, Nakanishi M, et al. Intraoperative electrocorticography and successful focus resection in a case of Sturge-Weber syndrome. Seizure. 1998 Dec;7(6):505-8. PMID: 9888497; X-1

1260. Hiraiwa H, Hamazaki M, Tsuruta S, et al. Infantile hemangioendothelioma of the thymus with massive pleural effusion and Kasabach--Merritt syndrome: histopathological, flow cytometrical analysis of the tumor. Acta Paediatr Jpn. 1998 Dec;40(6):604-7. PMID: 9893299; X-1

1261. Holmstrom G, Taylor D. Capillary haemangiomas in association with morning glory disc anomaly. Acta Ophthalmol Scand. 1998 Oct;76(5):613-6. PMID: 9826051; X-1, X-3

1262. Hu B, Lachman R, Phillips J, et al. Kasabach-Merritt syndrome-associated kaposiform hemangioendothelioma successfully treated with cyclophosphamide, vincristine, and actinomycin D. J Pediatr Hematol Oncol. 1998 Nov-Dec;20(6):567-9. PMID: 9856681; X-1

1263. Inskip PD, Mellemkjaer L, Gridley G, et al. Incidence of intracranial tumors following hospitalization for head injuries (Denmark). Cancer Causes Control. 1998 Jan;9(1):109-16. PMID: 9486470; X-1

1264. Jackson IT, Sosa J. Excision of nasal tip hemangioma via open rhinoplasty - A skin sparing technique. Eur J Plast Surg. 1998 June;21(5):265-8. PMID: 1998246141; X-2

1265. Kallen B, Karlsson P, Lundell M, et al. Outcome of reproduction in women irradiated for skin hemangioma in infancy. Radiat Res. 1998 Feb;149(2):202-8. PMID: 9457901; X-1, X-3

1266. Kanai N, Saito K, Homma Y, et al. Infantile hemangioendothelioma of the liver associated with anomalous dilated and tortuous vessels on the placental surface. Pediatr Surg Int. 1998 Mar;13(2-3):175-6. PMID: 9563039; X-1

1267. Kaplan I, Mass E, Littner M. A study of small superficial capillary hemangiomas on the lips in children. Pediatr Dent. 1998 May-Jun;20(3):188-91. PMID: 9635315; X-1

1268. Karlsson P, Holmberg E, Lundell M, et al. Intracranial tumors after exposure to ionizing radiation during infancy: a pooled analysis of two Swedish cohorts of 28,008 infants with skin hemangioma. Radiat Res. 1998 Sep;150(3):357-64. PMID: 9728664; X-1, X-3

1269. Katz SE, Rootman J, Vangveeravong S, et al. Combined venous lymphatic malformations of the orbit (so-called lymphangiomas). Association with noncontiguous intracranial vascular anomalies. Ophthalmology. 1998 Jan;105(1):176-84. PMID: 9442796; X-1

1270. Koscick RL, Petersilge CA, Makley JT, et al. CT-guided fine needle aspiration and needle core biopsy of skeletal lesions. Complementary diagnostic techniques. Acta Cytol. 1998 May-Jun;42(3):697-702. PMID: 9622690; X-1

1271. Lawton MT, Raudzens PA, Zabramski JM, et al. Hypothermic circulatory arrest in neurovascular surgery: evolving indications and predictors of patient outcome. Neurosurgery. 1998 Jul;43(1):10-20; discussion -1. PMID: 9657183; X-1

1272. Lezama-del Valle P, Gerald WL, Tsai J, et al. Malignant vascular tumors in young patients. Cancer. 1998 Oct 15;83(8):1634-9. PMID: 9781959; X-1

1273. Ligot L, Diallo I, Shamsaldin A, et al. Individualized phantom based on CT slices and auxological data (ICTA) for dose estimations following radiotherapy for skin haemangioma in childhood. Radiother Oncol. 1998 Dec;49(3):279-85. PMID: 10075261; X-1

1274. Maria BL, Neufeld JA, Rosainz LC, et al. High prevalence of bihemispheric structural and functional defects in Sturge-Weber syndrome. J Child Neurol. 1998 Dec;13(12):595-605. PMID: 9881530; X-1

1275. Maria BL, Neufeld JA, Rosainz LC, et al. Central nervous system structure and function in Sturge-Weber syndrome: evidence of neurologic and radiologic progression. J Child Neurol. 1998 Dec;13(12):606-18. PMID: 9881531; X-1

1276. Mariotti P, Iuvone L, Torrioli MG, et al. Linguistic and non-linguistic abilities in a patient with early left hemispherectomy. Neuropsychologia. 1998 Dec;36(12):1303-12. PMID: 9863684; X-1

1277. McLaughlin MR, Kondziolka D, Flickinger JC, et al. The prospective natural history of cerebral venous malformations. Neurosurgery. 1998 Aug;43(2):195-200; discussion -1. PMID: 9696070; X-1

1278. Mehdorn HM, Barth H, Buhl R, et al. Intracranial cavernomas: indications for and results of surgery. Neurol Med Chir (Tokyo). 1998;38 Suppl:245-9. PMID: 10235013; X-1

1279. Meis-Kindblom JM, Kindblom LG. Angiosarcoma of soft tissue: a study of 80 cases. Am J Surg Pathol. 1998 Jun;22(6):683-97. PMID: 9630175; X-1

1280. Miyazoe Y, Sawairi T, Ito K, et al. Development of the small caliber centrifugal blood pump. Artif Organs. 1998 Jun;22(6):461-5. PMID: 9650666; X-1

1281. Naidoo K, Bhigjee AI. Multiple cerebellar haemangioblastomas symptomatic during pregnancy. Br J Neurosurg. 1998 Jun;12(3):281-4. PMID: 11013697; X-1

1282. Norouzi BB, Shanberg AM. Laser treatment of large cavernous hemangiomas of the penis. J Urol. 1998 Jul;160(1):60-2. PMID: 9628605; X-1

1283. Olsen KE, Huang AS, Wright MM. The efficacy of goniotomy/trabeculotomy in early-onset glaucoma associated with the Sturge-Weber syndrome. J aapos. 1998 Dec;2(6):365-8. PMID: 10532726; X-1

1284. Ono H, Mawatari H, Mizoguchi N, et al. Clinical features and outcome of eight infants with intrahepatic porto-venous shunts detected in neonatal screening for galactosaemia. Acta Paediatr. 1998 Jun;87(6):631-4. PMID: 9686654; X-1

1285. Orr RJ, Elwood T. Special challenging problems in the difficult pediatric airway: lymphangioma, laryngeal papillomatosis, and subglottic hemangioma. Anesthesiol Clin North America. 1998;16(4):869-83. PMID: X-1, X-2

1286. Patrizi A, Neri I, Marzaduri S, et al. Tumor of the right shoulder in a newborn. Bossed hemangioma with telangiectasia and peripheral pallor. Arch Dermatol. 1998 Sep;134(9):1146, 8-9. PMID: 9762030; X-1

1287. Pittet B, Montandon D. Nasal reconstruction in children: a review of 29 patients. J Craniofac Surg. 1998 Nov;9(6):522-8. PMID: 10029764; X-1

1288. Platokouki H, Aronis S, Mitsika A, et al. Diffuse splenic and visceral hemangiomas complicated by chronic consumption coagulopathy. Acta Paediatr Jpn. 1998 Aug;40(4):381-4. PMID: 9745787; X-1

1289. Ricci RM, Finley EM, Grimwood RE. Treatment of cutaneous hemangiomas in preterm neonatal twins with the flashlamp-pumped pulsed dye laser. Lasers Surg Med. 1998;22(1):10-3. PMID: 9443144; X-2

1290. Rodriguez CD. What is your assessment? Capillary hemangioma. Pediatr Nurs. 1998 Mar-Apr;24(2):174-5. PMID: 9697572; X-1, X-2

1291. Rokitansky AM, Jakl RJ, Gopfrich H, et al. Special compression sutures: a new surgical technique to achieve a quick decrease in shunt volume caused by diffuse hemangiomatosis of the liver. Pediatr Surg Int. 1998 Nov;14(1-2):119-21. PMID: 9880718; X-1, X-2

1292. Sakaguchi M, Sue K, Etoh G, et al. A case of solitary cavernous hemangioma of the small intestine with recurrent clinical anemic attacks in childhood. J Pediatr Gastroenterol Nutr. 1998 Sep;27(3):342-3. PMID: 9740209; X-1

1293. Salman MS. Is the prophylactic use of antiepileptic drugs in Sturge-Weber syndrome justified? Med Hypotheses. 1998 Oct;51(4):293-6. PMID: 9824833; X-1

1294. Sarihan H, Mocan H, Abeys M, et al. Kasabach-Merrit syndrome in infants. Panminerva Med. 1998 Jun;40(2):128-31. PMID: 9689834; X-1

1295. Scafidi DE, McLeary MS, Young LW. Diffuse neonatal gastrointestinal hemangiomatosis: CT findings. Pediatr Radiol. 1998 Jul;28(7):512-4. PMID: 9662569; X-1, X-2

1296. Sgonc R, Fuerhapter C, Boeck G, et al. Induction of apoptosis in human dermal microvascular endothelial cells and infantile hemangiomas by interferon-alpha. Int Arch Allergy Immunol. 1998 Nov;117(3):209-14. PMID: 9831809; X-1, X-2

1297. Sung MS, Kang HS, Lee HG. Regional bone changes in deep soft tissue hemangiomas: radiographic and MR features. Skeletal Radiol. 1998 Apr;27(4):205-10. PMID: 9592903; X-1

1298. Svatek M, Stevens S, Ment LR. Caudal appendage in a full-term infant. Curr Opin Pediatr. 1998 Dec;10(6):635-9. PMID: 9848025; X-1

1299. Tryfonas GI, Tsikopoulos G, Liasidou E, et al. Conservative treatment of hemangiomas in infancy and childhood with interferon-alpha 2a. Pediatr Surg Int. 1998 Oct;13(8):590-3. PMID: 9799383; X-3, X-4

1300. Vanderhooft SL, Doidge WW, Maughan T. Flashlamp-pumped pulsed dye laser treatment of vascular birthmarks. Aorn j. 1998 Jun;67(6):1214-23; quiz 24, 26, 29-30. PMID: 9629455; X-1, X-2

1301. Wacker FK, Cholewa D, Roggan A, et al. Vascular lesions in children: percutaneous MR imaging-guided interstitial Nd:YAG laser therapy--preliminary experience. Radiology. 1998 Sep;208(3):789-94. PMID: 9722861; X-1

1302. Webster AR, Richards FM, MacRonald FE, et al. An analysis of phenotypic variation in the familial cancer syndrome von Hippel-Lindau disease: evidence for modifier effects. Am J Hum Genet. 1998 Oct;63(4):1025-35. PMID: 9758595; X-1

1303. Werner JA, Lippert BM, Gottschlich S, et al. Ultrasound-guided interstitial Nd: YAG laser treatment of voluminous hemangiomas and vascular malformations in 92 patients. Laryngoscope. 1998 Apr;108(4 Pt 1):463-70. PMID: 9546253; X-3

1304. Yang CB, Freedman SF, Myers JS, et al. Use of latanoprost in the treatment of glaucoma associated with Sturge-Weber syndrome. Am J Ophthalmol. 1998 Oct;126(4):600-2. PMID: 9780111; X-1

1305. Yang YH, Lee PI, Lin KH, et al. Absolute ethanol embolotherapy for hemangioma with Kasabach-Merritt syndrome. Zhonghua Min Guo Xiao Er Ke Yi Xue Hui Za Zhi. 1998 Jan-Feb;39(1):51-4. PMID: 9553294; X-1, X-2

1306. Yoon PH, Kim DI, Jeon P, et al. Cerebral cavernous malformations: serial magnetic resonance imaging findings in patients with and without gamma knife surgery. Neurol Med Chir (Tokyo). 1998;38 Suppl:255-61. PMID: 10235015; X-1

1307. . Case records of the Massachusetts General Hospital. Weekly clinicopathological exercises. Case 35-1999. A five-month-old girl with coffee-grounds vomitus. N Engl J Med. 1999 Nov 18;341(21):1597-603. PMID: 10564691; X-1

1308. Abdulrauf SI, Kaynar MY, Awad IA. A comparison of the clinical profile of cavernous malformations with and without associated venous malformations. Neurosurgery. 1999 Jan;44(1):41-6; discussion 6-7. PMID: 9894962; X-1

1309. Achauer BM, Chang CJ, VanderKam VM, et al. Intralesional photocoagulation of periorbital hemangiomas. Plast Reconstr Surg. 1999 Jan;103(1):11-6; discussion 7-9. PMID: 9915158; X-4

1310. Aldave AJ, Shields CL, Shields JA. Surgical excision of selected amblyogenic periorbital capillary hemangiomas. Ophthalmic Surg Lasers. 1999 Nov-Dec;30(9):754-7. PMID: 10574498; X-2

1311. Altuna JC, Greenfield DS, Wand M, et al. Latanoprost in glaucoma associated with Sturge-Weber syndrome: benefits and side-effects. J Glaucoma. 1999 Jun;8(3):199-203. PMID: 10376261; X-1

1312. Altunay IK, Gokdemir G, Koken R, et al. An infant with multiple hemangiomas showing favorable prognosis. Int J Dermatol. 1999 Mar;38(3):211-3. PMID: 10208620; X-1, X-2

1313. Angermeier MC. Treatment of facial vascular lesions with intense pulsed light. J Cutan Laser Ther. 1999 Apr;1(2):95-100. PMID: 11357295; X-1

1314. Auriemma A, Bellan C, Poggiani C, et al. Imaging of neonatal hemangiomas, two cases. Eur J Ultrasound. 1999 May;9(2):161-5. PMID: 10413752; X-1, X-2

1315. Awad AH, Mullaney PB, Al-Mesfer S, et al. Glaucoma in Sturge-Weber syndrome. J aapos. 1999 Feb;3(1):40-5. PMID: 10071900; X-1

1316. Aylett SE, Neville BG, Cross JH, et al. Sturge-Weber syndrome: cerebral haemodynamics during seizure activity. Dev Med Child Neurol. 1999 Jul;41(7):480-5. PMID: 10454232; X-1

1317. Basu S, Singhal U, Mohan H. Fine needle aspiration of angiomatoid malignant fibrous histiocytoma. A case report. Acta Cytol. 1999 Sep-Oct;43(5):859-61. PMID: 10518144; X-1

1318. Bemporad JA, Sze G, Chaloupka JC, et al. Pseudohemangioma of the vertebra: an unusual radiographic manifestation of primary Ewing's sarcoma. AJNR Am J Neuroradiol. 1999 Nov-Dec;20(10):1809-13. PMID: 10588101; X-1

1319. Bhandarkar PV, Sreenivasa D, Mistry FP, et al. Profile of extrahepatic portal venous obstruction in Mumbai. J Assoc Physicians India. 1999 Aug;47(8):791-4. PMID: 10778624; X-1

1320. Bouchard S, Yazbeck S, Lallier M. Perineal hemangioma, anorectal malformation, and genital anomaly: a new association? J Pediatr Surg. 1999 Jul;34(7):1133-5. PMID: 10442608; X-2

1321. Brant AJ, James HE, Tung H. Cutaneomeningospinal angiomatosis (Cobb syndrome) with tethered cord. Pediatr Neurosurg. 1999 Feb;30(2):93-5. PMID: 10325565; X-1, X-2

1322. Castellote A, Vazquez E, Vera J, et al. Cervicothoracic lesions in infants and children. Radiographics. 1999 May-Jun;19(3):583-600. PMID: 10336190; X-1

1323. Catsman-Berrevoets CE, Van Dongen HR, Mulder PG, et al. Tumour type and size are high risk factors for the syndrome of "cerebellar" mutism and subsequent dysarthria. J Neurol Neurosurg Psychiatry. 1999 Dec;67(6):755-7. PMID: 10567492; X-1

1324. Ceyhan A, Cakan T, Basar H, et al. Anaesthesia for Sturge-Weber syndrome. Eur J Anaesthesiol. 1999 May;16(5):339-41. PMID: 10390670; X-1

1325. Chang CJ, Fisher DM, Chen YR. Intralesional photocoagulation of vascular anomalies of the tongue. Br J Plast Surg. 1999 Apr;52(3):178-81. PMID: 10474467; X-2

1326. Chang J, Most D, Bresnick S, et al. Proliferative hemangiomas: analysis of cytokine gene expression and angiogenesis. Plast Reconstr Surg. 1999 Jan;103(1):1-9; discussion 10. PMID: 9915157; X-1, X-3

1327. Chien HY, Sung TC. Aneurysm of the ascending aorta in a neonate. Acta Paediatr Taiwan. 1999 Mar-Apr;40(2):121-3. PMID: 10910601; X-1

1328. Daller JA, Bueno J, Gutierrez J, et al. Hepatic hemangioendothelioma: clinical experience and management strategy. J Pediatr Surg. 1999 Jan;34(1):98-105; discussion -6. PMID: 10022152; X-1

1329. Devulapalli CS. Index of suspicion. Case 1. Chronic autoimmune hepatitis. Pediatr Rev. 1999 Aug;20(8):273; discussion 4. PMID: 10429147; X-1

1330. Di Landro A, Tadini GL, Marchesi L, et al. Phakomatosis pigmentovascularis: A new case with renal angiomas and some considerations about the classification. Pediatr Dermatol. 1999 Jan-Feb;16(1):25-30. PMID: 10027995; X-1

1331. Drolet BA, Esterly NB, Frieden IJ. Hemangiomas in children. N Engl J Med. 1999 Jul 15;341(3):173-81. PMID: 10403856; X-1, X-2

1332. Dubois J, Hershon L, Carmant L, et al. Toxicity profile of interferon alfa-2b in children: A prospective evaluation. J Pediatr. 1999 Dec;135(6):782-5. PMID: 10586188; X-3

1333. Eckstein FS, Heinemann MK, Mielke GJ, et al. Resection of a large right atrial hemangioma in a neonate after prenatal diagnosis. Ann Thorac Surg. 1999 Sep;68(3):1074-5. PMID: 10510016; X-1

1334. Eisenberg MB, Al-Mefty O, DeMonte F, et al. Benign nonmeningeal tumors of the cavernous sinus. Neurosurgery. 1999 May;44(5):949-54; discussion 54-5. PMID: 10232527; X-1

1335. El-Hakim IE, El-Khashab MM. Cavernous haemangioma of the submandibular salivary gland. Int J Oral Maxillofac Surg. 1999 Feb;28(1):58-9. PMID: 10065653; X-1

1336. Fisher MD, Bridges M, Lin KY. The use of ultrasound-assisted liposuction in the treatment of an involuted hemangioma. J Craniofac Surg. 1999 Nov;10(6):500-2. PMID: 10726503; X-1, X-2

1337. Fong M, Clarke K, Cron C. Clinical applications of the holmium:YAG laser in disorders of the paediatric airway. J Otolaryngol. 1999 Dec;28(6):337-43. PMID: 10604163; X-1, X-2

1338. Freeman AI, Lossos A, Gomori JM, et al. Interferon in the treatment of base of the skull hemangioendothelioma. Otolaryngol Head Neck Surg. 1999 Dec;121(6):842-3. PMID: 10580254; X-1

1339. Frim DM, Scott RM. Management of cavernous malformations in the pediatric population. Neurosurg Clin N Am. 1999 Jul;10(3):513-8. PMID: 10419575; X-1

1340. Glasker S, Bender BU, Apel TW, et al. The impact of molecular genetic analysis of the VHL gene in patients with haemangioblastomas of the central nervous system. J Neurol Neurosurg Psychiatry. 1999 Dec;67(6):758-62. PMID: 10567493; X-1

1341. Greinwald JH, Jr., Burke DK, Bonthius DJ, et al. An update on the treatment of hemangiomas in children with interferon alfa-2a. Arch Otolaryngol Head Neck Surg. 1999 Jan;125(1):21-7. PMID: 9932582; X-4

1342. Guillou L, Calonje E, Speight P, et al. Hobnail hemangioma: a pseudomalignant vascular lesion with a reappraisal of targetoid hemosiderotic hemangioma. Am J Surg Pathol. 1999 Jan;23(1):97-105. PMID: 9888709; X-1, X-2

1343. Haak MC, Oosterhof H, Mouw RJ, et al. Pathophysiology and treatment of fetal anemia due to placental chorioangioma. Ultrasound Obstet Gynecol. 1999 Jul;14(1):68-70. PMID: 10461342; X-1

1344. Haasbeek JF, Alvillar RE. Childhood lipoma arborescens presenting as bilateral suprapatellar masses. J Rheumatol. 1999 Mar;26(3):683-6. PMID: 10090182; X-1

1345. Hamush NG, Coleman AL, Wilson MR. Ahmed glaucoma valve implant for management of glaucoma in Sturge-Weber syndrome. Am J Ophthalmol. 1999 Dec;128(6):758-60. PMID: 10612515; X-1

1346. Herman TE, McAlister WH, Dehner LP. Posterior mediastinal capillary hemangioma with extradural extension resembling neuroblastoma. Pediatr Radiol. 1999 Jul;29(7):517-9. PMID: 10398787; X-2

1347. Horie Y, Kato M. Juvenile hemangioma (infantile hemangioendothelioma) of the parotid gland associated with cytomegalovirus infection. Pathol Int. 1999 Jul;49(7):668-71. PMID: 10504531; X-1, X-2

1348. Hosono S, Ohno T, Kimoto H, et al. Successful transcutaneous arterial embolization of a giant hemangioma associated with high-output cardiac failure and Kasabach-Merritt syndrome in a neonate: a case report. J Perinat Med. 1999;27(5):399-403. PMID: 10642962; X-1

1349. Hughes CA, Rezaee A, Ludemann JP, et al. Management of congenital subglottic hemangioma. J Otolaryngol. 1999 Aug;28(4):223-8. PMID: 10461260; X-4

1350. Irkec M, Kiratli H, Bilgic S. Results of trabeculotomy and guarded filtration procedure for glaucoma associated with Sturge-Weber syndrome. Eur J Ophthalmol. 1999 Apr-Jun;9(2):99-102. PMID: 10435421; X-1

1351. Kaban LB, Mulliken JB, Ezekowitz RA, et al. Antiangiogenic therapy of a recurrent giant cell tumor of the mandible with interferon alfa-2a. Pediatrics. 1999 Jun;103(6 Pt 1):1145-9. PMID: 10353921; X-1

1352. Kim MS, Lee SI, Sim SH. Brain tumors with cysts treated with Gamma Knife radiosurgery: is microsurgery indicated? Stereotact Funct Neurosurg. 1999;72 Suppl 1:38-44. PMID: 10681689; X-1

1353. Kiristioglu I, Kilic N, Gurpinar AN, et al. Aicardi syndrome associated with palatal hemangioma. Eur J Pediatr Surg. 1999 Oct;9(5):325-6. PMID: 10584193; X-1

1354. Kuo KT, Tsai TF, Hsiao CH. Diffuse neonatal hemangiomatosis complicated with cardiac tamponade: A case report. Tzu Chi Medical Journal. 1999;11(1):103-8. PMID: 1999133802; X-1

1355. Lafaut BA, Meire FM, Leys AM, et al. Vasoproliferative retinal tumors associated with peripheral chorioretinal scars in presumed congenital toxoplasmosis. Graefes Arch Clin Exp Ophthalmol. 1999 Dec;237(12):1033-8. PMID: 10654174; X-1

1356. Leung AC, Kao CP. Photo essay: focus on signs and symptoms. Pediatric vascular lesions. Consultant. 1999;39(11):3110. PMID: X-1

1357. Leung AKC, Kao CP. Pediatric vascular lesions. Consultant. 1999;39(11):3110. PMID: 1999422907; X-2

1358. Liekens S, Verbeken E, Vandeputte M, et al. A novel animal model for hemangiomas: inhibition of hemangioma development by the angiogenesis inhibitor TNP-470. Cancer Res. 1999 May 15;59(10):2376-83. PMID: 10344747; X-1

1359. Lopriore E, Markhorst DG. Diffuse neonatal haemangiomatosis: new views on diagnostic criteria and prognosis. Acta Paediatr. 1999 Jan;88(1):93-7. PMID: 10090556; X-1

1360. Lundell M, Mattsson A, Karlsson P, et al. Breast cancer risk after radiotherapy in infancy: a pooled analysis of two Swedish cohorts of 17,202 infants. Radiat Res. 1999 May;151(5):626-32. PMID: 10319736; X-1, X-3

1361. Makhlouf HR, Ishak KG, Goodman ZD. Epithelioid hemangioendothelioma of the liver: a clinicopathologic study of 137 cases. Cancer. 1999 Feb 1;85(3):562-82. PMID: 10091730; X-1

1362. Makino Y, Horiuchi S, Sonoda M, et al. A case of large placental chorioangioma with non-immunological hydrops fetalis. J Perinat Med. 1999;27(2):128-31. PMID: 10379503; X-1

1363. Mandal AK. Primary combined trabeculotomy-trabeculectomy for early-onset glaucoma in Sturge-Weber syndrome. Ophthalmology. 1999 Aug;106(8):1621-7. PMID: 10442913; X-1

1364. Mandal AK. Sturge-Weber syndrome with bilateral congenital syndactyly: a previously undescribed association. Ophthalmic Surg Lasers. 1999 Mar;30(3):221-2. PMID: 10100258; X-1

1365. Matsumoto K, Hukuda S, Ishizawa M, et al. Partial rupture of the quadriceps tendon (jumper's knee) in a ten-year-old boy. A case report. Am J Sports Med. 1999 Jul-Aug;27(4):521-5. PMID: 10424225; X-1

1366. Matturri L, Ottaviani G, Rossi L. Sudden and unexpected infant death due to an hemangioendothelioma located in the medulla oblongata. Adv Clin Path. 1999 Jan-Apr;3(1-2):29-33. PMID: 10655571; X-1

1367. McCarthy EF, Lietman S, Argani P, et al. Endovascular papillary angioendothelioma (Dabska tumor) of bone. Skeletal Radiol. 1999 Feb;28(2):100-3. PMID: 10197456; X-1

1368. Mohanty R, Gondal, Dash, et al. Diffuse cavernous haemangioma of the rectosigmoid with bladder involvement--a case report. Indian J Pathol Microbiol. 1999 Oct;42(4):487-9. PMID: 11127383; X-1

1369. Morris J, Abbott J, Burrows P, et al. Antenatal diagnosis of fetal hepatic hemangioma treated with maternal corticosteroids. Obstet Gynecol. 1999 Nov;94(5 Pt 2):813-5. PMID: 10546738; X-1

1370. Oda D. Case challenge. Pathological condition of a newborn child. J Contemp Dent Pract. 1999 Nov 15;1(1):50-4. PMID: 12167901; X-1

1371. Paterson A, Frush DP, Donnelly LF, et al. A pattern-oriented approach to splenic imaging in infants and children. Radiographics. 1999 Nov-Dec;19(6):1465-85. PMID: 10555669; X-1

1372. Pohlen U, Kroesen AJ, Berger G, et al. Diagnostics and surgical treatment strategy for rectal cavernous hemangiomas based on three case examples. Int J Colorectal Dis. 1999 Dec;14(6):300-3. PMID: 10663899; X-1

1373. Pumberger W, Gindl K, Amann G, et al. Polypoid fibro-haemangioma of the kidney in a child with gross haematuria. Scand J Urol Nephrol. 1999 Oct;33(5):344-6. PMID: 10573003; X-1

1374. Ratan S, Bhatnagar V, Gupta SD, et al. Epithelioid hemangioendothelioma of the greater omentum: report of a case. Surg Today. 1999;29(9):919-21. PMID: 10489137; X-1

1375. Robinson HA, Keeton BR, Moore IE. Critical obstruction of the right ventricular outflow tract by a primary hemangioendothelioma in a seven month old. Cardiol Young. 1999 Mar;9(2):185-8. PMID: 10323517; X-1

1376. Sallee D, Spector ML, van Heeckeren DW, et al. Primary pediatric cardiac tumors: a 17 year experience. Cardiol Young. 1999 Mar;9(2):155-62. PMID: 10323513; X-1

1377. Schemmer DC, Goh RH, Maguire JA. Cavernous angioma: a cryptic CT and MRI presentation. Pediatr Radiol. 1999 Feb;29(2):146. PMID: 9933338; X-1

1378. Schlecht I, Hierholzer J, Maurer J, et al. Gastric haemangioma: a rare cause of gastrointestinal bleeding. Pediatr Radiol. 1999 Jan;29(1):63. PMID: 9880621; X-1, X-2

1379. Schulz AS, Urban J, Gessler P, et al. Anaemia, thrombocytopenia and coagulopathy due to occult diffuse infantile haemangiomatosis of spleen and pancreas. Eur J Pediatr. 1999 May;158(5):379-83. PMID: 10333119; X-1

1380. Schwobel MG, Schramm H, Gitzelmann CA. The infantile inguinal hernia - a bilateral disease? Pediatr Surg Int. 1999;15(2):115-8. PMID: 10079343; X-1

1381. Scott IU, Alexandrakis G, Cordahi GJ, et al. Diffuse and circumscribed choroidal hemangiomas in a patient with Sturge-Weber syndrome. Arch Ophthalmol. 1999 Mar;117(3):406-7. PMID: 10088826; X-1

1382. Seo SK, Suh JC, Na GY, et al. Kasabach-Merritt syndrome: identification of platelet trapping in a tufted angioma by immunohistochemistry technique using monoclonal antibody to CD61. Pediatr Dermatol. 1999 Sep-Oct;16(5):392-4. PMID: 10571842; X-1

1383. Sharma S, Bandhu S, Gulati MS, et al. Gastric hemangioma associated with phleboliths: CT appearance. AJR Am J Roentgenol. 1999 Sep;173(3):859-60. PMID: 10470966; X-1

1384. Sibbald B. Calgary home to country's first comprehensive vascular birthmark clinic. Cmaj. 1999 Mar 23;160(6):898. PMID: 10189445; X-1

1385. Stegersjo G, Kahnberg KE. Prosthetic restoration following maxillary resection without an oroantral defect: a case report. Int J Prosthodont. 1999 Sep-Oct;12(5):391-4. PMID: 10709518; X-1

1386. Thirlwall AS, Bailey CM, Ramsay AD, et al. Laryngeal paraganglioma in a five-year-old child--the youngest case ever recorded. J Laryngol Otol. 1999 Jan;113(1):62-4. PMID: 10341923; X-1

1387. Tortori-Donati P, Fondelli MP, Rossi A, et al. Intracranial contrast-enhancing masses in infants with capillary haemangioma of the head and neck: intracranial capillary haemangioma? Neuroradiology. 1999 May;41(5):369-75. PMID: 10379597; X-1, X-3

1388. Uemura S, Woodward AA, Amerena R, et al. Early repair of inguinal hernia in premature babies. Pediatr Surg Int. 1999;15(1):36-9. PMID: 9914352; X-1

1389. Van Den Abbeele T, Triglia JM, Lescanne E, et al. Surgical removal of subglottic hemangiomas in children. Laryngoscope. 1999 Aug;109(8):1281-6. PMID: 10443834; X-4

1390. Verheul HM, Panigrahy D, Flynn E, et al. Treatment of the Kasabach-Merritt syndrome with pegylated recombinant human megakaryocyte growth and development factor in mice: elevated platelet counts, prolonged survival, and tumor growth inhibition. Pediatr Res. 1999 Nov;46(5):562-5. PMID: 10541319; X-1

1391. Walker MB, Hilbert GA, Rinehart J. Face to face with Sturge-Weber syndrome. J Soc Pediatr Nurs. 1999 Apr-Jun;4(2):74-82. PMID: 10410356; X-1

1392. Walker P, Cooper D, MacDonald D. Subglottic haemangioma: controversies in management. J Paediatr Child Health. 1999 Aug;35(4):392-5. PMID: 10457300; X-2

1393. Webster AR, Maher ER, Bird AC, et al. A clinical and molecular genetic analysis of solitary ocular angioma. Ophthalmology. 1999 Mar;106(3):623-9. PMID: 10080225; X-1

1394. Webster AR, Maher ER, Moore AT. Clinical characteristics of ocular angiomatosis in von Hippel-Lindau disease and correlation with germline mutation. Arch Ophthalmol. 1999 Mar;117(3):371-8. PMID: 10088816; X-1

1395. Woydt M, Horowski A, Krone A, et al. Localization and characterization of intracerebral cavernous angiomas by intra-operative high-resolution colour-duplex-sonography. Acta Neurochir (Wien). 1999;141(2):143-51; discussion 52. PMID: 10189495; X-1

1396. Yoshida D, Sugisaki Y, Shimura T, et al. Cavernous hemangioma of the skull in a neonate. Childs Nerv Syst. 1999 Jul;15(6-7):351-3. PMID: 10461786; X-1

1397. Zeevi B, Berant M. Unusual malformation of the aortic arch in a patient with a large facial hemangioma. Cardiol Young. 1999 Sep;9(5):539-40. PMID: 10535840; X-1, X-2

1398. Achauer BM, VanderKam VM. Treating vascular birthmarks with laser surgery. Contemp Pediatr. 2000;17(3):91--2, 5-6, 8 passim. PMID: X-1, X-2

1399. Akiyoshi K, Mizote H, Tanaka Y, et al. Capillary hemangioma of the liver with Kasabach-Merritt syndrome in a neonate: report of a case. Surg Today. 2000;30(1):86-8. PMID: 10648092; X-1

1400. Al-Sebeih K, Manoukian J. Systemic steroids for the management of obstructive subglottic hemangioma. J Otolaryngol. 2000 Dec;29(6):361-6. PMID: 11770144; X-4

1401. Amirikia A, Scott IU, Murray TG. Bilateral diffuse choroidal hemangiomas with unilateral facial nevus flammeus in Sturge-Weber syndrome. Am J Ophthalmol. 2000 Sep;130(3):362-4. PMID: 11020422; X-1

1402. Andiran F, Tanyel FC. Hemangioma of the cecum: an overlooked cause of rectal bleeding. J Pediatr Gastroenterol Nutr. 2000 Mar;30(3):330-1. PMID: 10749422; X-1, X-2

1403. Arzimanoglou AA, Andermann F, Aicardi J, et al. Sturge-Weber syndrome: indications and results of surgery in 20 patients. Neurology. 2000 Nov 28;55(10):1472-9. PMID: 11094100; X-1

1404. Avery JK. Loss prevention case of the month. Physician + nurse = expensive clash. Tenn Med. 2000 Mar;93(3):86-7. PMID: 10714183; X-2

1405. Bakaeen G, Winkler S, Bakaeen L, et al. Congenital macroglossal angiodysplasia ("Lymphangioendotheliomatosis"). Arch Pathol Lab Med. 2000 Sep;124(9):1349-51. PMID: 10975936; X-1

1406. Bentz BG, Hughes CA, Ludemann JP, et al. Masses of the salivary gland region in children. Arch Otolaryngol Head Neck Surg. 2000 Dec;126(12):1435-9. PMID: 11115277; X-1, X-3

1407. Bigot JL, Iacona C, Lepreux A, et al. Sinus pericranii: advantages of MR imaging. Pediatr Radiol. 2000 Oct;30(10):710-2. PMID: 11075608; X-1

1408. Bornet G, Claudet I, Fries F, et al. Cervicofacial angioma and the Kasabach-Merritt syndrome. Neuroradiology. 2000 Sep;42(9):703-6. PMID: 11071448; X-1, X-2

1409. Budenz DL, Sakamoto D, Eliezer R, et al. Two-staged Baerveldt glaucoma implant for childhood glaucoma associated with Sturge-Weber syndrome. Ophthalmology. 2000 Nov;107(11):2105-10. PMID: 11054342; X-1

1410. Burstein FD, Simms C, Cohen SR, et al. Intralesional laser therapy of extensive hemangiomas in 100 consecutive pediatric patients. Ann Plast Surg. 2000 Feb;44(2):188-94. PMID: 10696047; X-1

1411. Ceyhan A, Gulhan Y, Cakan T, et al. Anaesthesia for Proteus syndrome. Eur J Anaesthesiol. 2000 Oct;17(10):645-7. PMID: 11050524; X-1

1412. Chang MW, Orlow SJ. Pyogenic granuloma: what to do when a child presents with this problem. Consultant. 2000;40(1):137. PMID: X-1

1413. Chen LE, Minkes RK, Langer JC. Pediatric surgery on the Internet: is the truth out there? J Pediatr Surg. 2000 Aug;35(8):1179-82. PMID: 10945690; X-1

1414. Cota N, Chandna A, Abernethy LJ. Orbital abscess masquerading as a rhabdomyosarcoma. J aapos. 2000 Oct;4(5):318-20. PMID: 11040485; X-1

1415. DeCou JM, Gauderer MW. Inguinal hernia in infants with very low birth weight. Semin Pediatr Surg. 2000 May;9(2):84-7. PMID: 10807229; X-1

1416. Deutsch H, Jallo GI, Faktorovich A, et al. Spinal intramedullary cavernoma: clinical presentation and surgical outcome. J Neurosurg. 2000 Jul;93(1 Suppl):65-70. PMID: 10879760; X-1

1417. Donnelly LF, Adams DM, Bisset GS, 3rd. Vascular malformations and hemangiomas: a practical approach in a multidisciplinary clinic. AJR Am J Roentgenol. 2000 Mar;174(3):597-608. PMID: 10701595; X-1, X-2

1418. Eloubeidi MA, Branch MS, Treem WR. Image of the month. Gastroenterology. 2000 Mar;118(3):462, 643. PMID: 10755867; X-1

1419. Enjolras O, Mulliken JB, Wassef M, et al. Residual lesions after Kasabach-Merritt phenomenon in 41 patients. J Am Acad Dermatol. 2000 Feb;42(2 Pt 1):225-35. PMID: 10642677; X-1

1420. Fan HC, Hung CH, Juan CJ, et al. Subglottic hemangioma associated with cutaneous and cerebellar hemangiomas detected by MRI: report of one case. Acta Paediatr Taiwan. 2000 Jul-Aug;41(4):214-7. PMID: 11021008; X-2

1421. Fender LJ, Lenthall RK, Jaspan T. De novo development of presumed cavernomas following resolution of E. Coli subdural empyemas. Neuroradiology. 2000 Oct;42(10):778-80. PMID: 11110086; X-1

1422. Gupta G, Bilsland D. A prospective study of the impact of laser treatment on vascular lesions. Br J Dermatol. 2000 Aug;143(2):356-9. PMID: 10951145; X-1

1423. Halperin EC. Neonatal neoplasms. Int J Radiat Oncol Biol Phys. 2000 Apr 1;47(1):171-8. PMID: 10758320; X-1

1424. Hasan Q, Ruger BM, Tan ST, et al. Clusterin/apoJ expression during the development of hemangioma. Hum Pathol. 2000 Jun;31(6):691-7. PMID: 10872662; X-2

1425. Hasan Q, Tan ST, Gush J, et al. Steroid therapy of a proliferating hemangioma: histochemical and molecular changes. Pediatrics. 2000 Jan;105(1 Pt 1):117-20. PMID: 10617714; X-1, X-2

1426. Haywood RM, Monk BE, Mahaffey PJ. The treatment of early cutaneous capillary haemangiomata (strawberry naevi) with the tunable dye laser. Br J Plast Surg. 2000 Jun;53(4):302-7. PMID: 10876254; X-1

1427. Ho V, Krol A, Bhargava R, et al. Diffuse neonatal haemangiomatosis. J Paediatr Child Health. 2000 Jun;36(3):286-9. PMID: 10849236; X-1

1428. Huang SA, Tu HM, Harney JW, et al. Severe hypothyroidism caused by type 3 iodothyronine deiodinase in infantile hemangiomas. N Engl J Med. 2000 Jul 20;343(3):185-9. PMID: 10900278; X-2

1429. Ingram JD, Yerushalmi B, Connell J, et al. Hepatoblastoma in a neonate: a hypervascular presentation mimicking hemangioendothelioma. Pediatr Radiol. 2000 Nov;30(11):794-7. PMID: 11100498; X-1

1430. Kaniklides C, Dimopoulos PA, Bajic D. Infantile hemangioendothelioma. A case report. Acta Radiol. 2000 Mar;41(2):161-4. PMID: 10741790; X-1

1431. Kato M, Chiba Y, Sakai K, et al. Endoscopic neodymium:yttrium aluminium garnet (Nd:YAG) laser irradiation of a bladder hemangioma associated with Klippel-Weber syndrome. Int J Urol. 2000 Apr;7(4):145-8. PMID: 10810971; X-1

1432. Kestle J, Connolly M, Cochrane D. Pediatric peri-insular hemispherotomy. Pediatr Neurosurg. 2000 Jan;32(1):44-7. PMID: 10765138; X-1

1433. Kiely PD, Tierney S, Barry M, et al. Infantile hypertrophic pyloric stenosis in a regional centre. Ir J Med Sci. 2000 Apr-Jun;169(2):100-2. PMID: 11006662; X-1

1434. Kogler A, Talan-Hranilovic J, Bozic B, et al. Concomitant bihemispheric cerebral ganglioglioma and hemangioma in an 18-month-old child: case report. J Child Neurol. 2000 Apr;15(4):244-8. PMID: 10805191; X-1, X-2

1435. Komiyama M, Nakajima H, Kitano S, et al. Endovascular treatment of huge cervicofacial hemangioma complicated by Kasabach-Merritt syndrome. Pediatr Neurosurg. 2000 Jul;33(1):26-30. PMID: 11025419; X-2

1436. Kothari SS, Karthikeyan G, Sharma S, et al. Infantile hepatic hemangio-endothelioma: treatment by coil embolization of the hepatic artery. Indian Pediatr. 2000 Jul;37(7):780-4. PMID: 10906813; X-1

1437. Kouri JG, Chen MY, Watson JC, et al. Resection of suprasellar tumors by using a modified transsphenoidal approach. Report of four cases. J Neurosurg. 2000 Jun;92(6):1028-35. PMID: 10839266; X-1

1438. Kramer U, Kahana E, Shorer Z, et al. Outcome of infants with unilateral Sturge-Weber syndrome and early onset seizures. Dev Med Child Neurol. 2000 Nov;42(11):756-9. PMID: 11104348; X-1

1439. Kreusel KM, Bechrakis NE, Heinichen T, et al. Retinal angiomatosis and von Hippel-Lindau disease. Graefes Arch Clin Exp Ophthalmol. 2000 Nov;238(11):916-21. PMID: 11148816; X-1

1440. Labauge P, Brunereau L, Levy C, et al. The natural history of familial cerebral cavernomas: a retrospective MRI study of 40 patients. Neuroradiology. 2000 May;42(5):327-32. PMID: 10872151; X-1

1441. Lathbuty K. No need to be marked for life: a case study using endoscopy to remove birthmarks. Inside Case Management. 2000;6(10):6-8. PMID: X-2

1442. Licun W, Gongjia S. Treatment of hemangioma with an angiogenesis inhibitor pingyangmycin. Indian Pediatr. 2000 Jun;37(6):636-9. PMID: 10869144; X-3, X-4

1443. Linward J. Care and treatment of haemangioma. Nurs Times. 2000 Aug 3-9;96(31):37. PMID: 11962854; X-1, X-2

1444. Lynch HT, McComb RD, Osborn NK, et al. Predominance of brain tumors in an extended Li-Fraumeni (SBLA) kindred, including a case of Sturge-Weber syndrome. Cancer. 2000 Jan 15;88(2):433-9. PMID: 10640978; X-1

1445. Mankani MH, Dufresne CR. Verrucous malformations: their presentation and management. Ann Plast Surg. 2000 Jul;45(1):31-6. PMID: 10917095; X-1

1446. Maxwell-Jones A. Haemangioma: Hannah's story. Nurs Times. 2000 Aug 3-9;96(31):38-9. PMID: 11962855; X-2

1447. McCabe CM, Flynn HW, Jr., Shields CL, et al. Juxtapapillary capillary hemangiomas. Clinical features and visual acuity outcomes. Ophthalmology. 2000 Dec;107(12):2240-8. PMID: 11097604; X-1

1448. Metry DW, Hebert AA. Benign cutaneous vascular tumors of infancy: when to worry, what to do. Arch Dermatol. 2000 Jul;136(7):905-14. PMID: 10890993; X-1, X-2

1449. Miyagami M, Katayama Y, Nakamura S. Clinicopathological study of vascular endothelial growth factor (VEGF), p53, and proliferative potential in familial von Hippel-Lindau disease and sporadic hemangioblastomas. Brain Tumor Pathol. 2000;17(3):111-20. PMID: 11310918; X-1

1450. Naito S, Shimizu K, Nakashima M, et al. Overexpression of Ets-1 transcription factor in angiosarcoma of the skin. Pathol Res Pract. 2000;196(2):103-9. PMID: 10707367; X-1

1451. Nakayama Y, Tanaka A, Ueno Y, et al. Scalp cavernous angioma presenting as sinus pericranii: diagnostic value of cerebral angiography and magnetic resonance imaging. Childs Nerv Syst. 2000 Sep;16(9):598-602. PMID: 11048636; X-1

1452. Navarro O, Dugougeat F, Kornecki A, et al. The impact of imaging in the management of intussusception owing to pathologic lead points in children. A review of 43 cases. Pediatr Radiol. 2000 Sep;30(9):594-603. PMID: 11009295; X-1

1453. Neri I, Patrizi A, Guerrini V, et al. Eruptive pseudoangiomatosis. Br J Dermatol. 2000 Aug;143(2):435-8. PMID: 10951161; X-1

1454. Niemela M, Lemeta S, Sainio M, et al. Hemangioblastomas of the retina: impact of von Hippel-Lindau disease. Invest Ophthalmol Vis Sci. 2000 Jun;41(7):1909-15. PMID: 10845616; X-1

1455. North PE, Waner M, Mizeracki A, et al. GLUT1: a newly discovered immunohistochemical marker for juvenile hemangiomas. Hum Pathol. 2000 Jan;31(1):11-22. PMID: 10665907; X-1, X-3

1456. Obana A, Cho A, Takamine Y, et al. A case of glaucoma with choroidal hemangioma managed by nonpenetrating trabeculectomy. Jpn J Ophthalmol. 2000 Mar-Apr;44(2):174-7. PMID: 10715387; X-1

1457. Ohyama M, Ijiri R, Tanaka Y, et al. Congenital primitive epithelial tumor of the liver showing focal rhabdoid features, placental involvement, and clinical features mimicking multifocal hemangioma or stage 4S neuroblastoma. Hum Pathol. 2000 Feb;31(2):259-63. PMID: 10685646; X-1

1458. Olivero WC, Deshmukh P, Gujrati M. Radiation-induced cavernous angioma mimicking metastatic disease. Br J Neurosurg. 2000 Dec;14(6):575-8. PMID: 11272041; X-1

1459. Oranje AP, de Waard-van der Spek FB, Devillers AC, et al. Treatment and pain relief of ulcerative hemangiomas with a polyurethane film. Dermatology. 2000;200(1):31-4. PMID: 10681610; X-4

1460. Packwood EA, Havertape SA, Cruz OA, et al. Visual rehabilitation in a child with diffuse choroidal hemangioma by using aggressive amblyopia therapy with low-dose external beam irradiation. J aapos. 2000 Oct;4(5):321-2. PMID: 11040486; X-1

1461. Pampin C, Devillers A, Treguier C, et al. Intratumoral consumption of indium-111-labeled platelets in a child with splenic hemangioma and thrombocytopenia. J Pediatr Hematol Oncol. 2000 May-Jun;22(3):256-8. PMID: 10864058; X-1

1462. Panow C, Berger C, Willi U, et al. MRI and CT of a haemangioma of the mandible in Kasabach-Merritt syndrome. Neuroradiology. 2000 Mar;42(3):215-7. PMID: 10772147; X-1

1463. Patel RJ, Appukuttan B, Ott S, et al. DNA-based diagnosis of the von Hippel-Lindau syndrome. Am J Ophthalmol. 2000 Feb;129(2):258-60. PMID: 10682986; X-1

1464. Poetke M, Bultmann O, Berlien HP. Association of large facial hemangiomas with Dandy-Walker syndrome. Case study concerning three infants. Eur J Pediatr Surg. 2000 Apr;10(2):125-9. PMID: 10877082; X-1

1465. Prapas N, Liang RI, Hunter D, et al. Color Doppler imaging of placental masses: differential diagnosis and fetal outcome. Ultrasound Obstet Gynecol. 2000 Nov;16(6):559-63. PMID: 11169351; X-1

1466. Prayson RA. Clinicopathological findings in patients who have undergone epilepsy surgery in the first year of life. Pathol Int. 2000 Aug;50(8):620-5. PMID: 10972860; X-1

1467. Prochazkova L, Machalka M, Prochazka J, et al. Arteriovenous malformations of the orofacial area. Acta Chir Plast. 2000;42(2):55-9. PMID: 10949855; X-1

1468. Reischle S, Schuller-Petrovic S. Treatment of capillary hemangiomas of early childhood with a new method of cryosurgery. J Am Acad Dermatol. 2000 May;42(5 Pt 1):809-13. PMID: 10775859; X-4

1469. Schmidt D, Natt E, Neumann HP. Long-term results of laser treatment for retinal angiomatosis in von Hippel-Lindau disease. Eur J Med Res. 2000 Feb 28;5(2):47-58. PMID: 10720563; X-1

1470. Shamsaldin A, Lundell M, Diallo I, et al. Estimation of the radiation dose from radiotherapy for skin haemangiomas in childhood: the ICTA software for epidemiology. Phys Med Biol. 2000 Dec;45(12):3589-99. PMID: 11131186; X-1

1471. Shields CL, Shields JA, Minzter R, et al. Cutaneous capillary hemangiomas of the eyelid, scalp, and digits in premature triplets. Am J Ophthalmol. 2000 Apr;129(4):528-31. PMID: 10764865; X-2

1472. Shin HY, Ryu KH, Ahn HS. Stepwise multimodal approach in the treatment of Kasabach-Merritt syndrome. Pediatr Int. 2000 Dec;42(6):620-4. PMID: 11192517; X-1

1473. Srivastava DN, Mahajan A, Berry M, et al. Colour Doppler flow imaging of focal hepatic lesions. Australas Radiol. 2000 Aug;44(3):285-9. PMID: 10974721; X-1

1474. Tan ST, Hasan Q, Velickovic M, et al. A novel in vitro human model of hemangioma. Mod Pathol. 2000 Jan;13(1):92-9. PMID: 10658915; X-1, X-3

1475. Uysal G, Guven A, Ozhan B, et al. Phakomatosis pigmentovascularis with Sturge-Weber syndrome: a case report. J Dermatol. 2000 Jul;27(7):467-70. PMID: 10935346; X-1

1476. van Emelen C, Goethals M, Dralands L, et al. Treatment of glaucoma in children with Sturge-Weber syndrome. J Pediatr Ophthalmol Strabismus. 2000 Jan-Feb;37(1):29-34. PMID: 10714693; X-1

1477. Wakabayashi Y, Isono M, Shimomura T, et al. Neurocutaneous vascular hamartomas mimicking Cobb syndrome. Case report. J Neurosurg. 2000 Jul;93(1 Suppl):133-6. PMID: 10879770; X-1

1478. Wild AT, Raab P, Krauspe R. Hemangioma of skeletal muscle. Arch Orthop Trauma Surg. 2000;120(3-4):139-43. PMID: 10738870; X-1

1479. Wilken JJ, Meier FA, Kornstein MJ. Kaposiform hemangioendothelioma of the thymus. Arch Pathol Lab Med. 2000 Oct;124(10):1542-4. PMID: 11035594; X-1

1480. Williams EF, 3rd, Stanislaw P, Dupree M, et al. Hemangiomas in infants and children. An algorithm for intervention. Arch Facial Plast Surg. 2000 Apr-Jun;2(2):103-11. PMID: 10925435; X-3, X-4

1481. Williams JV, Bickel KD, Cunningham BB. Raney clips: excision of vascular lesions on the scalp made (ridiculously) simple. Pediatr Dermatol. 2000 May-Jun;17(3):238-9. PMID: 10886762; X-2

1482. Winter H, Drager E, Sterry W. Sclerotherapy for treatment of hemangiomas. Dermatol Surg. 2000 Feb;26(2):105-8. PMID: 10691936; X-1

1483. Wong JH, Awad IA, Kim JH. Ultrastructural pathological features of cerebrovascular malformations: a preliminary report. Neurosurgery. 2000 Jun;46(6):1454-9. PMID: 10834648; X-1

1484. Woo KI, Kim YD. Vascular hamartoma of the orbit. Korean J Ophthalmol. 2000 Dec;14(2):103-6. PMID: 11213733; X-1

1485. Yamakawa N, Noda M, Ohyama T, et al. A cellular variant of supratentorial hemangioblastoma. Brain Tumor Pathol. 2000;17(1):15-9. PMID: 10982005; X-1

1486. Yoshikawa T, Aoki S, Hori M, et al. Time-resolved two-dimensional thick-slice magnetic resonance digital subtraction angiography in assessing brain tumors. Eur Radiol. 2000;10(5):736-44. PMID: 10823625; X-1

1487. Yung BC, Loke TK, Chan YL. Angiomatosis of the hand demonstrated by contrast-enhanced magnetic resonance angiogram. Australas Radiol. 2000 May;44(2):198-200. PMID: 10849984; X-1

1488. Zhang N, Pan L, Wang BJ, et al. Gamma knife radiosurgery for cavernous hemangiomas. J Neurosurg. 2000 Dec;93 Suppl 3:74-7. PMID: 11143267; X-1

1489. . Index of suspicion. Pediatr Rev. 2001 Oct;22(10):343-8. PMID: 11581487; X-1

1490. . Updates. Severe hypothyroidism and infantile hemangiomas. Contemp Ob Gyn. 2001;46:77. PMID: X-2

1491. Akyol MU, Yalciner EG, Dogan AI. Pyogenic granuloma (lobular capillary hemangioma) of the tongue. Int J Pediatr Otorhinolaryngol. 2001 May 11;58(3):239-41. PMID: 11335013; X-1, X-2

1492. Amirikia A, Scott IU, Capo H, et al. Increasing hyperopia and esotropia as the presenting signs of bilateral diffuse choroidal hemangiomas in a patient with Sturge-Weber syndrome. J Pediatr Ophthalmol Strabismus. 2001 Nov-Dec;38(6):367-8. PMID: 11759777; X-1

1493. Arbiser JL, Weiss SW, Arbiser ZK, et al. Differential expression of active mitogen-activated protein kinase in cutaneous endothelial neoplasms: implications for biologic behavior and response to therapy. J Am Acad Dermatol. 2001 Feb;44(2):193-7. PMID: 11174372; X-1, X-3

1494. Atahan IL, Cengiz M, Ozyar E, et al. Radiotherapy in the management of Kasabach-Merritt syndrome: a case report. Pediatr Hematol Oncol. 2001 Oct-Nov;18(7):471-6. PMID: 11594711; X-1, X-2

1495. Attar A, Ugur HC, Savas A, et al. Surgical treatment of intracranial cavernous angiomas. J Clin Neurosci. 2001 May;8(3):235-9. PMID: 11386797; X-1

1496. Bannister CF, Brosius KK, Sigl JC, et al. The effect of bispectral index monitoring on anesthetic use and recovery in children anesthetized with sevoflurane in nitrous oxide. Anesth Analg. 2001 Apr;92(4):877-81. PMID: 11273918; X-1

1497. Billio A, Pescosta N, Rosanelli C, et al. Treatment of Kasabach-Merritt syndrome by embolisation of a giant liver hemangioma. Am J Hematol. 2001 Feb;66(2):140-1. PMID: 11421294; X-1, X-2

1498. Bree AF, Siegfried E, Sotelo-Avila C, et al. Infantile hemangiomas: speculation on placental trophoblastic origin. Arch Dermatol. 2001 May;137(5):573-7. PMID: 11346335; X-1, X-3

1499. Broome ME. Professional issues... commentary on Krasna IH (2000). Abdominal pain and appendicitis: is there a difference in referrals between HMO prediatricians [sic] and private pediatricians? JOURNAL OF PEDIATRIC SURGERY, 35(7), 1084-1086. J Child Fam Nurs. 2001 2001 Jan-Feb;4(1):59-60. PMID: X-1

1500. Brumblay HG, Khoshyomn S, Tranmer BI, et al. Giant cavernous angioma. Pediatr Neurosurg. 2001 Dec;35(6):336. PMID: 11786705; X-1

1501. Cacciaguerra S, Vasta G, Benedetto AG, et al. Neonatal diaphragmatic hemangioma. J Pediatr Surg. 2001 Sep;36(9):E21. PMID: 11528638; X-1, X-2

1502. Cho S, Lee SY, Choi JH, et al. Treatment of "Cyrano" angioma with pulsed dye laser. Dermatol Surg. 2001 Jul;27(7):670-2. PMID: 11442621; X-1, X-2

1503. Cooke R. Lack of thyroid hormone is linked to retardation in infants. Los Angeles Times -- Southern California Edition (Front Page). 2001:S6-S. PMID: X-1

1504. Curros F, Brunelle F. Prenatal thoracoabdominal tumor mimicking pulmonary sequestration: a diagnosis dilemma. Eur Radiol. 2001;11(1):167-70. PMID: 11194909; X-1

1505. Damiani S, Eusebi V. Gynecomastia in type-1 neurofibromatosis with features of pseudoangiomatous stromal hyperplasia with giant cells. Report of two cases. Virchows Arch. 2001 May;438(5):513-6. PMID: 11407482; X-1

1506. Deda H, Ugur HC, Yorulmaz I, et al. Anteromedial approach to the orbit. Skull Base. 2001;11(4):233-9. PMID: 2001427164; X-1

1507. Deutsch H, Shrivistava R, Epstein F, et al. Pediatric intramedullary spinal cavernous malformations. Spine. 2001 Sep 15;26(18):E427-31. PMID: 11547214; X-1

1508. Diment J, Yurim O, Pappo O. Infantile hemangioendothelioma of the liver in an adult. Arch Pathol Lab Med. 2001 Jul;125(7):931-2. PMID: 11419979; X-1

1509. Drolet BA, Scott LA, Esterly NB, et al. Early surgical intervention in a patient with Kasabach-Merritt phenomenon. J Pediatr. 2001 May;138(5):756-8. PMID: 11343057; X-1

1510. Dunn KJ. Flying home. J Soc Pediatr Nurs. 2001 Apr-Jun;6(2):83-6. PMID: 11326465; X-1

1511. Dunn KJ. Case study. Flying home. J Soc Pediatr Nurs. 2001;6(2):83-6. PMID: X-1

1512. Egbert JE, Paul S, Engel WK, et al. High injection pressure during intralesional injection of corticosteroids into capillary hemangiomas. Arch Ophthalmol. 2001 May;119(5):677-83. PMID: 11346395; X-2

1513. Endo H, Kawada A, Aragane Y, et al. The successful treatment of diffuse neonatal hemangiomatosis with flashlamp pulsed dye laser. Pediatr Dermatol. 2001 Mar-Apr;18(2):146-8. PMID: 11358559; X-1

1514. Enjolras O, Mulliken JB, Boon LM, et al. Noninvoluting congenital hemangioma: a rare cutaneous vascular anomaly. Plast Reconstr Surg. 2001 Jun;107(7):1647-54. PMID: 11391180; X-1

1515. Ertem D, Acar Y, Kotiloglu E, et al. Blue rubber bleb nevus syndrome. Pediatrics. 2001 Feb;107(2):418-20. PMID: 11158481; X-1

1516. Esposito C, Zupi A, Califano L. Surgical therapy of parotid hemangiomas. Pediatr Surg Int. 2001 Jul;17(5-6):335-7. PMID: 11527159; X-4

1517. Fledelius HC, Illum N, Jensen H, et al. Interferon-alfa treatment of facial infantile haemangiomas: with emphasis on the sight-threatening varieties. A clinical series. Acta Ophthalmol Scand. 2001 Aug;79(4):370-3. PMID: 11453856; X-4

1518. Folkersma H, Mooij JJ. Follow-up of 13 patients with surgical treatment of cerebral cavernous malformations: effect on epilepsy and patient disability. Clin Neurol Neurosurg. 2001 Jul;103(2):67-71. PMID: 11516547; X-1

1519. Forest-Lalande L. Helpful hints in neonatology wound care. Primary Intention: The Australian Journal of Wound Management. 2001;9(1):7. PMID: X-1

1520. Fukino K, Umeoka K, Kitamura T, et al. Cortical dysplasia with subcutaneous angioma and dilated dural venous sinuses. J Neuroradiol. 2001 Jun;28(2):127-9. PMID: 11466498; X-1

1521. Gaggero R, Devescovi R, Zaccone A, et al. Epilepsy associated with infantile hemiparesis: predictors of long-term evolution. Brain Dev. 2001 Mar;23(1):12-7. PMID: 11226723; X-1

1522. Garmendia G, Miranda N, Borroso S, et al. Regression of infancy hemangiomas with recombinant IFN-alpha 2b. J Interferon Cytokine Res. 2001 Jan;21(1):31-8. PMID: 11177578; X-3

1523. Geeze MA. Advanced practice case study: congenital hemangiomas. Semin Perioper Nurs. 2001;10(4):188-95. PMID: X-1, X-2

1524. Ghourab S. Ultrasound in the management of Chorioangioma. Saudi Med J. 2001 Jul;22(7):585-9. PMID: 11479638; X-1

1525. Goto T, Kojima T, Iijima T, et al. Soft-tissue haemangioma and periosteal new bone formation on the neighbouring bone. Arch Orthop Trauma Surg. 2001 Nov;121(10):549-53. PMID: 11768633; X-1

1526. Grosz AH, Jacobs IN, Cho C, et al. Use of helium-oxygen mixtures to relieve upper airway obstruction in a pediatric population. Laryngoscope. 2001 Sep;111(9):1512-4. PMID: 11568598; X-2

1527. Hasan Q, Tan ST, Gush J, et al. Altered mitochondrial cytochrome b gene expression during the regression of hemangioma. Plast Reconstr Surg. 2001 Nov;108(6):1471-6; discussion 7-8. PMID: 11711910; X-1, X-3

1528. Hecht DA, Jackson CG, Grundfast KM. Management of middle ear hemangiomas. Am J Otolaryngol. 2001 Sep-Oct;22(5):362-6. PMID: 11562890; X-1

1529. Hodaie M, Becker L, Teshima I, et al. Total resection of an intracerebral hemangioendothelioma in an infant. Case report and review of the literature. Pediatr Neurosurg. 2001 Feb;34(2):104-12. PMID: 11287811; X-1

1530. Hoeger PH, Schaefer H, Ussmueller J, et al. Nasal glioma presenting as capillary haemangioma. Eur J Pediatr. 2001 Feb;160(2):84-7. PMID: 11271395; X-1

1531. Holmberg E, Holm LE, Lundell M, et al. Excess breast cancer risk and the role of parity, age at first childbirth and exposure to radiation in infancy. Br J Cancer. 2001 Aug 3;85(3):362-6. PMID: 11487266; X-1

1532. Ibarra RA, Kesava P, Hallet KK, et al. Hemangioendothelioma of the temporal bone with radiologic findings resembling hemangioma. AJNR Am J Neuroradiol. 2001 Apr;22(4):755-8. PMID: 11290494; X-1

1533. Kacker A, April M, Ward RF. Use of potassium titanyl phosphate (KTP) laser in management of subglottic hemangiomas. Int J Pediatr Otorhinolaryngol. 2001 May 31;59(1):15-21. PMID: 11376814; X-4

1534. Kaminsky RA. Pathologic quiz case: An exceedingly rare cause of sudden cardiac death. Arch Pathol Lab Med. 2001 Apr;125(4):573-4. PMID: 11260643; X-1

1535. Kammula US, Buell JF, Labow DM, et al. Surgical management of benign tumors of the liver. Int J Gastrointest Cancer. 2001;30(3):141-6. PMID: 12540026; X-1

1536. Kaneko R, Tohnai I, Ueda M, et al. Curative treatment of central hemangioma in the mandible by direct puncture and embolisation with n-butyl-cyanoacrylate (NBCA). Oral Oncol. 2001 Oct;37(7):605-8. PMID: 11564583; X-1, X-2

1537. Kapella M, Panosetti E, Rombaux P, et al. Lobular capillary haemangioma of the nasal cavity: observation of three specific cases. Acta Otorhinolaryngol Belg. 2001;55(3):241-6. PMID: 11685962; X-1

1538. Karmazyn B, Michovitz S, Sirota L, et al. Intracranial cavernous hemangioma in a neonate. Pediatr Radiol. 2001 Sep;31(9):610-2. PMID: 11511998; X-1

1539. Kayser K, Zink S, Link B, et al. Endobronchial juvenile hemangioma--a case report of a neonate including immunohistochemical monitoring and nuclear, cellular, and vascular morphometry. Virchows Arch. 2001 Feb;438(2):192-7. PMID: 11253122; X-2

1540. Khurana KK, Mortelliti AJ. The role of fine-needle aspiration biopsy in the diagnosis and management of juvenile hemangioma of the parotid gland and cheek. Arch Pathol Lab Med. 2001 Oct;125(10):1340-3. PMID: 11570911; X-2

1541. Kim HJ, Colombo M, Frieden IJ. Ulcerated hemangiomas: clinical characteristics and response to therapy. J Am Acad Dermatol. 2001 Jun;44(6):962-72. PMID: 11369908; X-3, X-4

1542. Kiratli H, Bozkurt B, Mocan C. Peripapillary staphyloma associated with orofacial capillary hemangioma. Ophthalmic Genet. 2001 Dec;22(4):249-53. PMID: 11803491; X-2

1543. Kollar CD, Johnston IH, Sholler GF. Communicating hydrocephalus secondary to a cardiac tumour compressing the superior vena cava. Childs Nerv Syst. 2001 Feb;17(3):117-20. PMID: 11305763; X-1

1544. Kriplani A, Abbi M, Banerjee N, et al. Indomethacin therapy in the treatment of polyhydramnios due to placental chorioangioma. J Obstet Gynaecol Res. 2001 Oct;27(5):245-8. PMID: 11776505; X-1

1545. Labauge P, Brunereau L, Coubes P, et al. Appearance of new lesions in two nonfamilial cerebral cavernoma patients. Eur Neurol. 2001;45(2):83-8. PMID: 11244270; X-1

1546. Landells I. Treatment of hemangiomas in children. Skin Therapy Lett. 2001 Oct;6(11):3-5. PMID: 11719826; X-1, X-2

1547. Lee H, Choi SS, Kim SS, et al. A case of glaucoma associated with Sturge-Weber syndrome and Nevus of Ota. Korean J Ophthalmol. 2001 Jun;15(1):48-53. PMID: 11530821; X-1

1548. Lee JK, Kim JH, Kim JS, et al. Cervical dermal sinus associated with dermoid cyst. Childs Nerv Syst. 2001 Aug;17(8):491-3. PMID: 11508540; X-1

1549. Leighton SE, Papsin B, Vellodi A, et al. Disordered breathing during sleep in patients with mucopolysaccharidoses. Int J Pediatr Otorhinolaryngol. 2001 Apr 27;58(2):127-38. PMID: 11278021; X-1

1550. Levy AD, Abbott RM, Rohrmann CA, Jr., et al. Gastrointestinal hemangiomas: imaging findings with pathologic correlation in pediatric and adult patients. AJR Am J Roentgenol. 2001 Nov;177(5):1073-81. PMID: 11641173; X-1, X-2

1551. Lindberg S. Radiotherapy of childhood haemangiomas: from active treatment to radiation risk estimates. Radiat Environ Biophys. 2001 Sep;40(3):179-89. PMID: 11783846; X-2

1552. Lukish JR, Gill GG, McCoy TR. Surgical care in the isolated military hospital. Mil Med. 2001 Jan;166(1):90-3. PMID: 11197107; X-1

1553. Madgy D, Ahsan SF, Kest D, et al. The application of the potassium-titanyl-phosphate (KTP) laser in the management of subglottic hemangioma. Arch Otolaryngol Head Neck Surg. 2001 Jan;127(1):47-50. PMID: 11177013; X-4

1554. Mason KP, Koka BV, Eldredge EA, et al. Perioperative considerations in a hypothyroid infant with hepatic haemangioma. Paediatr Anaesth. 2001 Mar;11(2):228-32. PMID: 11240884; X-1, X-2

1555. Matsushima T, Inoue T, Inamura T, et al. Transcerebellomedullary fissure approach with special reference to methods of dissecting the fissure. J Neurosurg. 2001 Feb;94(2):257-64. PMID: 11213963; X-1

1556. McDonald HR. Diagnostic and therapeutic challenges. Retina. 2001;21(1):62-4; discussion 4-5. PMID: 11217932; X-1

1557. Niemela M, Maenpaa H, Salven P, et al. Interferon alpha-2a therapy in 18 hemangioblastomas. Clin Cancer Res. 2001 Mar;7(3):510-6. PMID: 11297241; X-1

1558. North PE, Waner M, James CA, et al. Congenital nonprogressive hemangioma: a distinct clinicopathologic entity unlike infantile hemangioma. Arch Dermatol. 2001 Dec;137(12):1607-20. PMID: 11735711; X-1, X-3

1559. North PE, Waner M, Mizeracki A, et al. A unique microvascular phenotype shared by juvenile hemangiomas and human placenta. Arch Dermatol. 2001 May;137(5):559-70. PMID: 11346333; X-1, X-3

1560. Ogino I, Torikai K, Kobayasi S, et al. Radiation therapy for life- or function-threatening infant hemangioma. Radiology. 2001 Mar;218(3):834-9. PMID: 11230664; X-3, X-4

1561. Orsini M, Rocha RS, Disch J, et al. The role of nutritional status and insulin-like growth factor in reduced physical growth in hepatosplenic Schistosoma mansoni infection. Trans R Soc Trop Med Hyg. 2001 Jul-Aug;95(4):453-6. PMID: 11579895; X-1

1562. Park EA, Seo JW, Lee SW, et al. Infantile hemangioendothelioma treated with high dose methylprednisolone pulse therapy. J Korean Med Sci. 2001 Feb;16(1):127-9. PMID: 11289392; X-1

1563. Parmar RC, Bavdekar SB, Borwankar SS, et al. Infantile hemangioendothelioma. Indian J Pediatr. 2001 May;68(5):459-61. PMID: 11407165; X-1

1564. Pasek T. Abby's gift. J Soc Pediatr Nurs. 2001 Oct-Dec;6(4):196-200. PMID: 11777333; X-1

1565. Pasek T. Role play. Abby's gift. J Soc Pediatr Nurs. 2001;6(4):196-200. PMID: X-1

1566. Ramsey PS, Danilenko DR, Derleth DP. Special feature: radiological case of the month. Arch Pediatr Adolesc Med. 2001 Jun;155(6):733-4. PMID: 11386968; X-2

1567. Rossi A, Bava GL, Biancheri R, et al. Posterior fossa and arterial abnormalities in patients with facial capillary haemangioma: presumed incomplete phenotypic expression of PHACES syndrome. Neuroradiology. 2001 Nov;43(11):934-40. PMID: 11760796; X-3

1568. Samii M, Eghbal R, Carvalho GA, et al. Surgical management of brainstem cavernomas. J Neurosurg. 2001 Nov;95(5):825-32. PMID: 11702873; X-1

1569. Senoh D, Hanaoka U, Tanaka Y, et al. Antenatal ultrasonographic features of fetal giant hemangiolymphangioma. Ultrasound Obstet Gynecol. 2001 Mar;17(3):252-4. PMID: 11309178; X-1

1570. Seto T, Kono K, Morimoto K, et al. Brain magnetic resonance imaging in 23 patients with mucopolysaccharidoses and the effect of bone marrow transplantation. Ann Neurol. 2001 Jul;50(1):79-92. PMID: 11456314; X-1

1571. Sherman JA, Davies HT. Intramuscular hemangioma of the temporalis muscle. J Oral Maxillofac Surg. 2001 Feb;59(2):207-9. PMID: 11213991; X-2

1572. Shields CL, Honavar SG, Shields JA, et al. Circumscribed choroidal hemangioma: clinical manifestations and factors predictive of visual outcome in 200 consecutive cases. Ophthalmology. 2001 Dec;108(12):2237-48. PMID: 11733265; X-1

1573. Simonovsky V, Lisy J, Pipkova R, et al. Benign liver tumours - Tomographic imaging methods. Haemangioma, infantile haemangioendothelioma and angiomyolipoma. Cesk Radiol. 2001;55(1):12-8. PMID: 2001233190; X-6

1574. Singh A, Shields J, Shields C. Solitary retinal capillary hemangioma: hereditary (von Hippel-Lindau disease) or nonhereditary? Arch Ophthalmol. 2001 Feb;119(2):232-4. PMID: 11176984; X-1

1575. Singh AD, Nouri M, Shields CL, et al. Retinal capillary hemangioma: a comparison of sporadic cases and cases associated with von Hippel-Lindau disease. Ophthalmology. 2001 Oct;108(10):1907-11. PMID: 11581072; X-1

1576. Sora S, Ueki K, Saito N, et al. Incidence of von Hippel-Lindau disease in hemangioblastoma patients: the University of Tokyo Hospital experience from 1954-1998. Acta Neurochir (Wien). 2001 Sep;143(9):893-6. PMID: 11685621; X-1

1577. Stiller B, Hetzer R, Meyer R, et al. Primary cardiac tumours: when is surgery necessary? Eur J Cardiothorac Surg. 2001 Nov;20(5):1002-6. PMID: 11675188; X-1

1578. Strouhal P, Bradshaw K. Case 2: assessment. Postural-dependent stridor. Paediatr Respir Rev. 2001 Mar;2(1):85-6. PMID: 16256728; X-2

1579. Sure U, Butz N, Schlegel J, et al. Endothelial proliferation, neoangiogenesis, and potential de novo generation of cerebrovascular malformations. J Neurosurg. 2001 Jun;94(6):972-7. PMID: 11409527; X-1

1580. Tarantal AF, O'Rourke JP, Case SS, et al. Rhesus monkey model for fetal gene transfer: studies with retroviral- based vector systems. Mol Ther. 2001 Feb;3(2):128-38. PMID: 11237669; X-1

1581. Vachvanichsanong P, Malagon M, Moore ES. Recurrent abdominal and flank pain in children with idiopathic hypercalciuria. Acta Paediatr. 2001 Jun;90(6):643-8. PMID: 11440097; X-1

1582. Vachvanichsanong P, Malagon M, Moore ES. Urinary tract infection in children associated with idiopathic hypercalciuria. Scand J Urol Nephrol. 2001 Apr;35(2):112-6. PMID: 11411652; X-1

1583. Vassilyadi M, Jones BV, Ball WS, Jr. Identification of an arteriovenous fistula in a child. Case report and review of the literature. Childs Nerv Syst. 2001 Nov;17(11):685-8. PMID: 11734989; X-1

1584. Verma K, Verma KK. Infantile periocular haemangioma treated with two days in a week betamethasone oral mini pulse therapy. Indian J Pediatr. 2001 Apr;68(4):355-6. PMID: 11370446; X-2

1585. Wang C, Zhang J, Liu A, et al. Surgical management of medullary hemangioblastoma. Report of 47 cases. Surg Neurol. 2001 Oct;56(4):218-26; discussion 26-7. PMID: 11738662; X-1

1586. Wong CH, Wright JG, Silove ED, et al. A new syndrome of multiple hemangiomas, right dominant double aortic arch, and coarctation. J Thorac Cardiovasc Surg. 2001 Jun;121(6):1207-9. PMID: 11385394; X-2

1587. Wong LC, Rogers M, Lammi A. Severe cyclical thrombocytopenia in a patient with a large lymphatic-venous malformation: a potential association? Australas J Dermatol. 2001 Feb;42(1):38-42. PMID: 11233720; X-1

1588. Woydt M, Krone A, Soerensen N, et al. Ultrasound-guided neuronavigation of deep-seated cavernous haemangiomas: clinical results and navigation techniques. Br J Neurosurg. 2001 Dec;15(6):485-95. PMID: 11814000; X-1

1589. Yakinci C, Durmaz Y, Korkut M, et al. Cavernous hemangioma in a child presenting with hemichorea: response to pimozide. J Child Neurol. 2001 Sep;16(9):685-8. PMID: 11575611; X-1

1590. Abe T, Tomatsu T, Tazaki K. Synovial hemangioma of the knee in young children. J Pediatr Orthop B. 2002 Oct;11(4):293-7. PMID: 12370579; X-1

1591. Abrahams NA, Colby TV, Pearl RH, et al. Pulmonary hemangiomas of infancy and childhood: report of two cases and review of the literature. Pediatr Dev Pathol. 2002 May-Jun;5(3):283-92. PMID: 12007021; X-1, X-2

1592. Amirikia A, Scott IU, Capo H, et al. Increasing hyperopia and esotropia as the presenting signs of bilateral diffuse choroidal hemangiomas in a patient with Sturge-Weber syndrome. J Pediatr Ophthalmol Strabismus. 2002 Mar-Apr;39(2):121-2. PMID: 11911543; X-1

1593. Ashoor A, Baker YA. Intraosseus Haemangioma of the nasal bone. Bahrain Med Bull. 2002;24(1):32-3. PMID: 2002130488; X-1, X-2

1594. Bannur U, Korah I, Chandy MJ. Midbrain venous angioma with obstructive hydrocephalus. Neurol India. 2002 Jun;50(2):207-9. PMID: 12134191; X-1

1595. Baron JA, Raines J, Bangert J, et al. Persistent nodule on the nose. Arch Dermatol. 2002 Feb;138(2):259-64. PMID: 11843651; X-1

1596. Bava GL, Dalmonte P, Oddone M, et al. Life-threatening hemorrhage from a vulvar hemangioma. J Pediatr Surg. 2002 Apr;37(4):E6. PMID: 11912541; X-1, X-2

1597. Baxter MA, Wynn RF, Deakin JA, et al. Retrovirally mediated correction of bone marrow-derived mesenchymal stem cells from patients with mucopolysaccharidosis type I. Blood. 2002 Mar 1;99(5):1857-9. PMID: 11861306; X-1

1598. Burge DM, Sugarman IS. Exclusion of androgen insensitivity syndrome in girls with inguinal hernias: current surgical practice. Pediatr Surg Int. 2002 Dec;18(8):701-3. PMID: 12598968; X-1

1599. Chatrath P, Black M, Jani P, et al. A review of the current management of infantile subglottic haemangioma, including a comparison of CO(2) laser therapy versus tracheostomy. Int J Pediatr Otorhinolaryngol. 2002 Jun 17;64(2):143-57. PMID: 12049827; X-4

1600. Chattopadhyay A, Kumar V, Maruliah M, et al. Duodenojejunal obstruction by a hemangioma. Pediatr Surg Int. 2002 Sep;18(5-6):501-2. PMID: 12415392; X-2

1601. Chen DH, Lipe HP, Qin Z, et al. Cerebral cavernous malformation: novel mutation in a Chinese family and evidence for heterogeneity. J Neurol Sci. 2002 Apr 15;196(1-2):91-6. PMID: 11959162; X-1

1602. Childers EL, Furlong MA, Fanburg-Smith JC. Hemangioma of the salivary gland: a study of ten cases of a rarely biopsied/excised lesion. Ann Diagn Pathol. 2002 Dec;6(6):339-44. PMID: 12478482; X-2, X-3

1603. Chiller KG, Passaro D, Frieden IJ. Hemangiomas of infancy: clinical characteristics, morphologic subtypes, and their relationship to race, ethnicity, and sex. Arch Dermatol. 2002 Dec;138(12):1567-76. PMID: 12472344; X-3

1604. Choi SJ, Choi BK, Kim HJ, et al. Lateral decubitus HRCT: a simple technique to replace expiratory CT in children with air trapping. Pediatr Radiol. 2002 Mar;32(3):179-82. PMID: 12164350; X-1, X-2

1605. Coghlan D, Lynch B, Allcutt D. Hereditary cerebral cavernous angiomas: presentation as idiopathic familial epilepsy. Ir Med J. 2002 Feb;95(2):56-8. PMID: 11989951; X-1

1606. Conrad M, Schonauer C, Morel C, et al. Computer-assisted resection of supra-tentorial cavernous malformation. Minim Invasive Neurosurg. 2002 Jun;45(2):87-90. PMID: 12087505; X-1

1607. D'Antonio A, Boscaino A, De Dominicis G, et al. Splenic hemangiomatosis. A report of two cases and review of literature. Adv Clin Path. 2002 Jul-Oct;6(3-4):119-24. PMID: 19757634; X-1

1608. de Kanter K. Ulcerated hemangiomas. Dermatol Nurs. 2002 Oct;14(5):337. PMID: 12430523; X-2

1609. Deb G, Donfrancesco A, Ilari I, et al. Hemangioendothelioma: successful therapy with interferon-alpha: a study in Association with the Italian Pediatric Haematology/Oncology Society (AIEOP). Med Pediatr Oncol. 2002 Feb;38(2):118-9. PMID: 11813178; X-1

1610. Denk MJ, Ajkay N, Yuan X, et al. Surgical treatment of nasal hemangiomas. Ann Plast Surg. 2002 May;48(5):489-94; discussion 94-5. PMID: 11981188; X-3, X-4

1611. Dietrich CF, Ignee A, Gebel M, et al. [Imaging of the abdomen. Z Gastroenterol. 2002 Dec;40(12):965-70. PMID: 12564420; X-1

1612. Dollfus H, Massin P, Taupin P, et al. Retinal hemangioblastoma in von Hippel-Lindau disease: a clinical and molecular study. Invest Ophthalmol Vis Sci. 2002 Sep;43(9):3067-74. PMID: 12202531; X-1

1613. Domini M, Aquino A, Fakhro A, et al. Blue rubber bleb nevus syndrome and gastrointestinal haemorrhage: which treatment? Eur J Pediatr Surg. 2002 Apr;12(2):129-33. PMID: 12015660; X-1

1614. Eliashiv DS, Elsas SM, Squires K, et al. Ictal magnetic source imaging as a localizing tool in partial epilepsy. Neurology. 2002 Nov 26;59(10):1600-10. PMID: 12451204; X-1

1615. El-Kayali AY, Al-Salman MM, Iqbal KI, et al. Vascular anomalies - diagnosis and therapy. Saudi Med J. 2002 Mar;23(3):272-6. PMID: 11938414; X-3, X-4

1616. Erez I, Rathause V, Vacian I, et al. Preoperative ultrasound and intraoperative findings of inguinal hernias in children: A prospective study of 642 children. J Pediatr Surg. 2002 Jun;37(6):865-8. PMID: 12037751; X-1

1617. Faguer K, Dompmartin A, Labbe D, et al. Early surgical treatment of Cyrano-nose haemangiomas with Rethi incision. Br J Plast Surg. 2002 Sep;55(6):498-503. PMID: 12479424; X-4

1618. Ferrari A, Casanova M, Bisogno G, et al. Malignant vascular tumors in children and adolescents: a report from the Italian and German Soft Tissue Sarcoma Cooperative Group. Med Pediatr Oncol. 2002 Aug;39(2):109-14. PMID: 12116058; X-1

1619. Frevel T, Rabe H, Uckert F, et al. Giant cavernous haemangioma with Kasabach-Merritt syndrome: a case report and review. Eur J Pediatr. 2002 May;161(5):243-6. PMID: 12012216; X-2

1620. Gangemi M, Maiuri F, Cappabianca P, et al. Endoscopic fenestration of symptomatic septum pellucidum cysts: three case reports with discussion on the approaches and technique. Minim Invasive Neurosurg. 2002 Jun;45(2):105-8. PMID: 12087509; X-1

1621. Garcia Muret MP, Puig L, Allard C, et al. Hypomelanosis of Ito with Sturge-Weber syndrome-like leptomeningeal angiomatosis. Pediatr Dermatol. 2002 Nov-Dec;19(6):536-40. PMID: 12437559; X-1

1622. Gargiulo G, Pace Napoleone C, Giardini A, et al. Repair of a complex aortic arch anomaly associated with cutaneous hemangioma. Ann Thorac Surg. 2002 Jul;74(1):245-6. PMID: 12118772; X-2

1623. Gasparovic H, Anic D, Saric D, et al. Surgical excision of a hemangioendothelioma of the left ventricle. Ann Thorac Surg. 2002 Sep;74(3):914-6. PMID: 12238864; X-1

1624. Gembruch U, Baschat AA, Gloeckner-Hoffmann K, et al. Prenatal diagnosis and management of fetuses with liver hemangiomata. Ultrasound Obstet Gynecol. 2002 May;19(5):454-60. PMID: 11982977; X-1

1625. Goyal A, Babu SN, Kim V, et al. Hemangioendothelioma of liver and spleen: trauma-induced consumptive coagulopathy. J Pediatr Surg. 2002 Oct;37(10):E29. PMID: 12378475; X-1

1626. Haisley-Royster C, Enjolras O, Frieden IJ, et al. Kasabach-merritt phenomenon: a retrospective study of treatment with vincristine. J Pediatr Hematol Oncol. 2002 Aug-Sep;24(6):459-62. PMID: 12218593; X-1

1627. Hanaoka J, Inoue S, Fujino S, et al. Mediastinal cavernous hemangioma in a child: report of a case. Surg Today. 2002;32(11):985-8. PMID: 12444436; X-1, X-2

1628. Hardisson D, Prim MP, De Diego JI, et al. Kaposiform hemangioendothelioma of the external auditory canal in an adult. Head Neck. 2002 Jun;24(6):614-7. PMID: 12112561; X-1

1629. Harigaya A, Nako Y, Morikawa A, et al. Premature infant with severe periventricular leukomalacia associated with a large placental chorioangioma: a case report. J Perinatol. 2002 Apr-May;22(3):252-4. PMID: 11948392; X-1

1630. Hasson O, Shacham R, Nahlieli O, et al. A firm, bluish mass of the cheek in a 17-month-old child. J Oral Maxillofac Surg. 2002 Mar;60(3):301-4. PMID: 11887144; X-1

1631. Hatton MP, Remulla HD, Tolentino MJ, et al. Clinical applications of color Doppler imaging in the management of orbital lesions. Ophthal Plast Reconstr Surg. 2002 Nov;18(6):462-5. PMID: 12439062; X-1

1632. Heckl S, Aschoff A, Kunze S. Radiation-induced cavernous hemangiomas of the brain: a late effect predominantly in children. Cancer. 2002 Jun 15;94(12):3285-91. PMID: 12115362; X-1

1633. Hein KD, Mulliken JB, Kozakewich HP, et al. Venous malformations of skeletal muscle. Plast Reconstr Surg. 2002 Dec;110(7):1625-35. PMID: 12447041; X-1

1634. Herman AR, Carucci JA. Management of obstructive airway hemangiomas in the neonate. J Drugs Dermatol. 2002 Dec;1(3):331-2. PMID: 12851995; X-2

1635. Herron MD, Coffin CM, Vanderhooft SL. Tufted angiomas: variability of the clinical morphology. Pediatr Dermatol. 2002 Sep-Oct;19(5):394-401. PMID: 12383094; X-1

1636. Hesselmann S, Micke O, Marquardt T, et al. Case report: Kasabach-Merritt syndrome: a review of the therapeutic options and a case report of successful treatment with radiotherapy and interferon alpha. Br J Radiol. 2002 Feb;75(890):180-4. PMID: 11893644; X-1

1637. Holmberg E, Wallgren A, Holm LE, et al. Dose-response relationship for parathyroid adenoma after exposure to ionizing radiation in infancy. Radiat Res. 2002 Oct;158(4):418-23. PMID: 12236809; X-3, X-4

1638. Hopf M, Hopf JUG, Rohde E, et al. Endoscopically controlled laser therapy of recurrent epistaxis with the 940 nm diode laser. Med Laser Appl. 2002 October;17(3):231-41. PMID: 2002433937; X-1

1639. Iwata N, Hattori K, Nakagawa T, et al. Hemangioma of the nasal cavity: a clinicopathologic study. Auris Nasus Larynx. 2002 Oct;29(4):335-9. PMID: 12393037; X-1

1640. Jain S, Goulstine D, Gottlob I. Acute adduction deficit in a 7-week-old infant. Strabismus. 2002 Dec;10(4):241-4. PMID: 12660849; X-1, X-2

1641. Jansen FE, van Huffelen AC, Witkamp T, et al. Diazepam-enhanced beta activity in Sturge Weber syndrome: its diagnostic significance in comparison with MRI. Clin Neurophysiol. 2002 Jul;113(7):1025-9. PMID: 12088695; X-1

1642. Jayakumar PN, Desai SV, Kovoor JM, et al. Percutaneous embolization of mandibular hemangioma: a case report. J Oral Maxillofac Surg. 2002 Aug;60(8):945-8. PMID: 12149745; X-1, X-2

1643. Kaira N, Mahapatra GK, Srivastava D, et al. Hemangioma of the oral cavity in a seven year old: a case report. J Indian Soc Pedod Prev Dent. 2002 Jun;20(2):49-50. PMID: 12435016; X-2

1644. Kaplan DL. Dermclinic. A photo quiz to hone dermatologic skills. Consultant. 2002;42(7):836-, 9-42, 45-6 passim. PMID: X-1

1645. Karagama YG, Howarth K, Steel PR, et al. Lobular capillary haemangioma of the nasal vestibule: a rare entity. Int J Pediatr Otorhinolaryngol. 2002 Oct 21;66(1):71-5. PMID: 12363425; X-1, X-2

1646. Kim DG, Choe WJ, Paek SH, et al. Radiosurgery of intracranial cavernous malformations. Acta Neurochir (Wien). 2002 Sep;144(9):869-78; discussion 78. PMID: 12376768; X-1

1647. Koc ON, Day J, Nieder M, et al. Allogeneic mesenchymal stem cell infusion for treatment of metachromatic leukodystrophy (MLD) and Hurler syndrome (MPS-IH). Bone Marrow Transplant. 2002 Aug;30(4):215-22. PMID: 12203137; X-1

1648. Kontzoglou G, Triaridis S, Noussios G, et al. Subglottic hemangioma treated with interferon alpha 2A. Acta Otorhinolaryngol Belg. 2002;56(1):83-5. PMID: 11894636; X-1, X-2

1649. Kossoff EH, Buck C, Freeman JM. Outcomes of 32 hemispherectomies for Sturge-Weber syndrome worldwide. Neurology. 2002 Dec 10;59(11):1735-8. PMID: 12473761; X-1

1650. Kullendorff CM, Cwikiel W, Sandstrom S. Embolization of hepatic hemangiomas in infants. Eur J Pediatr Surg. 2002 Oct;12(5):348-52. PMID: 12469266; X-1

1651. Kumar VH, Clive J, Rosenkrantz TS, et al. Inguinal hernia in preterm infants (< or = 32-week gestation). Pediatr Surg Int. 2002 Mar;18(2-3):147-52. PMID: 11956782; X-1

1652. Kuo MF, Wang HS, Chen MT. Sincipital encephalocele mismanaged as a facial hemangioma. Pediatr Neurol. 2002 May;26(5):408-10. PMID: 12057807; X-1

1653. Leaute-Labreze C, Boralevi F, Pedespan JM, et al. Pulsed dye laser for Sturge-Weber syndrome. Arch Dis Child. 2002 Nov;87(5):434-5. PMID: 12390926; X-1

1654. Lee CH. Intestinal obstruction caused by infarcted splenic hemangioma with renal vein thrombosis in a newborn: a case report. Int Surg. 2002 Jul-Sep;87(3):157-9. PMID: 12403090; X-1, X-2

1655. Lim SL, Ng Sb A, Tan GM. Ilioinguinal and iliohypogastric nerve block revisited: single shot versus double shot technique for hernia repair in children. Paediatr Anaesth. 2002 Mar;12(3):255-60. PMID: 11903940; X-1

1656. Lu CC, Ko SF, Liang CD, et al. Infantile hepatic hemangioendothelioma presenting as early heart failure: report of two cases. Chang Gung Med J. 2002 Jun;25(6):405-10. PMID: 12173671; X-1

1657. Mahendran R, White SI, Clark AH, et al. Response of childhood tufted angioma to the pulsed-dye laser. J Am Acad Dermatol. 2002 Oct;47(4):620-2. PMID: 12271313; X-1

1658. Mara M, Calda P, Zizka Z, et al. Fetal anemia, thrombocytopenia, dilated umbilical vein, and cardiomegaly due to a voluminous placental chorioangioma. A case report. Fetal Diagn Ther. 2002 Sep-Oct;17(5):286-92. PMID: 12169813; X-1

1659. Marler JJ, Rubin JB, Trede NS, et al. Successful antiangiogenic therapy of giant cell angioblastoma with interferon alfa 2b: report of 2 cases. Pediatrics. 2002 Feb;109(2):E37. PMID: 11826247; X-1

1660. Martinez MI, Sanchez-Carpintero I, North PE, et al. Infantile hemangioma: clinical resolution with 5% imiquimod cream. Arch Dermatol. 2002 Jul;138(7):881-4; discussion 4. PMID: 12071813; X-2

1661. Matitiau A, Birk E, Schonfeld T, et al. Stent implantation for long-segment coarctation of aorta in infant with facial and mediastinal hemangioma. Catheter Cardiovasc Interv. 2002 Apr;55(4):510-2. PMID: 11948901; X-2

1662. Mazoyer E, Enjolras O, Laurian C, et al. Coagulation abnormalities associated with extensive venous malformations of the limbs: differentiation from Kasabach-Merritt syndrome. Clin Lab Haematol. 2002 Aug;24(4):243-51. PMID: 12181029; X-1

1663. McCarthy JG, Borud LJ, Schreiber JS. Hemangiomas of the nasal tip. Plast Reconstr Surg. 2002 Jan;109(1):31-40. PMID: 11786788; X-4

1664. Miura K, Han G, Sano M, et al. Regression of congenital fibrosarcoma to hemangiomatous remnant with histological and genetic findings. Pathol Int. 2002 Sep;52(9):612-8. PMID: 12406191; X-1

1665. Mohan UR, Hay AA, Cleary MA, et al. Cardiovascular changes in children with mucopolysaccharide disorders. Acta Paediatr. 2002;91(7):799-804. PMID: 12200906; X-1

1666. Mulliken JB, Rogers GF, Marler JJ. Circular excision of hemangioma and purse-string closure: the smallest possible scar. Plast Reconstr Surg. 2002 Apr 15;109(5):1544-54; discussion 55. PMID: 11932595; X-3, X-4

1667. Naftchi S, la Cour M. A case of central visual loss in a child due to macular cavernous haemangioma of the retina. Acta Ophthalmol Scand. 2002 Oct;80(5):550-2. PMID: 12390171; X-1

1668. Nassiri SJ. Contralateral exploration is not mandatory in unilateral inguinal hernia in children: a prospective 6-year study. Pediatr Surg Int. 2002 Sep;18(5-6):470-1. PMID: 12415383; X-1

1669. Pascual-Castroviejo I, Frutos R, Viano J, et al. Cobb syndrome: case report. J Child Neurol. 2002 Nov;17(11):847-9. PMID: 12585726; X-1, X-2

1670. Perez J, Pardo J, Gomez C. Vincristine--an effective treatment of corticoid-resistant life-threatening infantile hemangiomas. Acta Oncol. 2002;41(2):197-9. PMID: 12102167; X-1, X-2

1671. Picker L. Saving face. Parents. 2002;77(5):85. PMID: X-2

1672. Poetke M, Jamil B, Muller U, et al. Diffuse neonatal hemangiomatosis associated with Simpson-Golabi-Behmel syndrome: a case report. Eur J Pediatr Surg. 2002 Feb;12(1):59-62. PMID: 11967762; X-1

1673. Pokorny JJ, Roth F, Balfour I, et al. An unusual complication of the treatment of a hemangioma. Ann Plast Surg. 2002 Jan;48(1):83-7. PMID: 11773735; X-2

1674. Pomeranz A, Libman L, Pomeranz M, et al. Ambulatory blood pressure monitoring in children with isolated haematuria. Pediatr Nephrol. 2002 Nov;17(11):938-42. PMID: 12432438; X-1

1675. Price T, Fayad G. Abducens nerve palsy as the sole presenting symptom of petrous apicitis. J Laryngol Otol. 2002 Sep;116(9):726-9. PMID: 12437811; X-1

1676. Prokurat A, Kluge P, Chrupek M, et al. Hemangioma of the liver in children: proliferating vascular tumor or congenital vascular malformation? Med Pediatr Oncol. 2002 Nov;39(5):524-9. PMID: 12228911; X-1

1677. Raja KA, Schurman S, D'Mello R G, et al. Responsiveness of hypercalciuria to thiazide in Dent's disease. J Am Soc Nephrol. 2002 Dec;13(12):2938-44. PMID: 12444212; X-1

1678. Ratageri VH, Rajshankar S. Palatal hemangioma with cleft zero. Indian Pediatr. 2002 Jul;39(7):693-4. PMID: 12147901; X-1, X-2

1679. Ritter MR, Dorrell MI, Edmonds J, et al. Insulin-like growth factor 2 and potential regulators of hemangioma growth and involution identified by large-scale expression analysis. Proc Natl Acad Sci U S A. 2002 May 28;99(11):7455-60. PMID: 12032304; X-1

1680. Rohana J, Boo NY, Hayati AR, et al. Diffuse neonatal haemangiomatosis: a rare cause of haemorrhagic shock and refractory coagulopathy in the newborn. Med J Malaysia. 2002 Sep;57(3):364-7. PMID: 12440278; X-1

1681. Rozylo-Kalinowska I, Brodzisz A, Galkowska E, et al. Application of Doppler ultrasonography in congenital vascular lesions of the head and neck. Dentomaxillofac Radiol. 2002 Jan;31(1):2-6. PMID: 11803381; X-1

1682. Sarkar M, Odegard K, Laussen P. Cardiac surgery in a child with sacral and intrasacral haemangioma. Paediatr Anaesth. 2002 Jul;12(6):552-5. PMID: 12139599; X-2

1683. Schrottner O, Unger F, Eder HG, et al. Gamma-Knife radiosurgery of mesiotemporal tumour epilepsy observations and long-term results. Acta Neurochir Suppl. 2002;84:49-55. PMID: 12379004; X-1

1684. Shalaby R, Desoky A. Needlescopic inguinal hernia repair in children. Pediatr Surg Int. 2002 Mar;18(2-3):153-6. PMID: 11956783; X-1

1685. Singh AD, Ahmad NN, Shields CL, et al. Solitary retinal capillary hemangioma: lack of genetic evidence for von Hippel-Lindau disease. Ophthalmic Genet. 2002 Mar;23(1):21-7. PMID: 11910555; X-1

1686. Singh AD, Nouri M, Shields CL, et al. Treatment of retinal capillary hemangioma. Ophthalmology. 2002 Oct;109(10):1799-806. PMID: 12359597; X-1

1687. Sleep TJ, Fairhurst JJ, Manners RM, et al. Doppler ultrasonography to aid diagnosis of orbital capillary haemangioma in neonates. Eye (Lond). 2002 May;16(3):316-9. PMID: 12032724; X-2

1688. Sugarman JL, Mauro TM, Frieden IJ. Treatment of an ulcerated hemangioma with recombinant platelet-derived growth factor. Arch Dermatol. 2002 Mar;138(3):314-6. PMID: 11902979; X-2

1689. Tamburrini G, Iannelli A, Caldarelli M, et al. Large cerebral cavernoma mimicking a brain tumor. Pediatr Neurosurg. 2002 Aug;37(2):105-6. PMID: 12145521; X-1

1690. Tang P, Hornicek FJ, Gebhardt MC, et al. Surgical treatment of hemangiomas of soft tissue. Clin Orthop Relat Res. 2002 Jun(399):205-10. PMID: 12011711; X-1

1691. Triglia JM, Nazarian B, Sudre-Levillain I, et al. Virtual laryngotracheal endoscopy based on geometric surface modeling using spiral computed tomography data. Ann Otol Rhinol Laryngol. 2002 Jan;111(1):36-43. PMID: 11800368; X-1

1692. Tubbs RS, Wellons JC, 3rd, Oakes WJ. Hemangioma of the transverse sinus. Pediatr Neurosurg. 2002 Nov;37(5):278-9. PMID: 12411724; X-1, X-2

1693. Tuxhorn IE, Pannek HW. Epilepsy surgery in bilateral Sturge-Weber syndrome. Pediatr Neurol. 2002 May;26(5):394-7. PMID: 12057803; X-1

1694. Vachharajani A, Paes B. Orbital lymphangioma with non-contiguous cerebral arteriovenous malformation, manifesting with thrombocytopenia (Kasabach-Merritt syndrome) and intracerebral hemorrhage. Acta Paediatr. 2002;91(1):98-9. PMID: 11883828; X-1

1695. Van Doorne L, De Maeseneer M, Stricker C, et al. Diagnosis and treatment of vascular lesions of the lip. Br J Oral Maxillofac Surg. 2002 Dec;40(6):497-503. PMID: 12464208; X-2

1696. Ville D, Enjolras O, Chiron C, et al. Prophylactic antiepileptic treatment in Sturge-Weber disease. Seizure. 2002 Apr;11(3):145-50. PMID: 12018956; X-1

1697. Walker GM, Abu-Rajab R, MacLennan A, et al. Kasabach-Merritt syndrome in a neonate caused by a kaposiform haemangioendothelioma. Med Pediatr Oncol. 2002 Jun;38(6):424-7. PMID: 11984805; X-1

1698. Walter JW, North PE, Waner M, et al. Somatic mutation of vascular endothelial growth factor receptors in juvenile hemangioma. Genes Chromosomes Cancer. 2002 Mar;33(3):295-303. PMID: 11807987; X-1, X-3

1699. Wananukul S. Clinical manifestation and management of hemangiomas of infancy. J Med Assoc Thai. 2002 Jun;85 Suppl 1:S280-5. PMID: 12188424; X-3, X-4

1700. Wananukul S, Chatproedprai S. Ulcerated hemangiomas: clinical features and management. J Med Assoc Thai. 2002 Nov;85(11):1220-5. PMID: 12546320; X-3, X-4

1701. Warren SM, Longaker MT, Zide BM. The subunit approach to nasal tip hemangiomas. Plast Reconstr Surg. 2002 Jan;109(1):25-30. PMID: 11786787; X-2

1702. Williams HJ, Wake MJ, John PR. Intraosseous haemangioma of the mandible: a case report. Pediatr Radiol. 2002 Aug;32(8):605-8. PMID: 12136355; X-2

1703. Wong SN, Tay YK. Tufted angioma: a report of five cases. Pediatr Dermatol. 2002 Sep-Oct;19(5):388-93. PMID: 12383093; X-1

1704. Yang CH, Ohara K. Successful surgical treatment of verrucous hemangioma: a combined approach. Dermatol Surg. 2002 Oct;28(10):913-19; discussion 20. PMID: 12410675; X-1

1705. Yang KH, Kim DS, Choi JU. The reversible focal MRI abnormalities in complex partial seizure: technical instruction. Childs Nerv Syst. 2002 Dec;18(12):722-4. PMID: 12483359; X-1

1706. Yavuzer R, Latifoglu O, Ozmen S, et al. Unilateral cleft lip complicated by a hemangioma. Plast Reconstr Surg. 2002 Sep 15;110(4):1084-7. PMID: 12198422; X-1

1707. Zalel Y, Gamzu R, Weiss Y, et al. Role of color Doppler imaging in diagnosing and managing pregnancies complicated by placental chorioangioma. J Clin Ultrasound. 2002 Jun;30(5):264-9. PMID: 12116105; X-1

1708. Zenge JP, Fenton L, Lovell MA, et al. Case report: infantile hemangioendothelioma. Curr Opin Pediatr. 2002 Feb;14(1):99-102. PMID: 11880743; X-1

1709. Agesta N, Boralevi F, Sarlangue J, et al. Life-threatening haemorrhage as a complication of a congenital haemangioma. Acta Paediatr. 2003 Oct;92(10):1216-8. PMID: 14632343; X-1, X-2

1710. Akabane N, Hamanaka T. Histopathological study of a case with glaucoma due to Sturge-Weber syndrome. Jpn J Ophthalmol. 2003 Mar-Apr;47(2):151-7. PMID: 12738548; X-1

1711. Allen RM, Sandquist MA, Piatt JH, Jr., et al. Ultrasonographic screening in infants with isolated spinal strawberry nevi. J Neurosurg. 2003 Apr;98(3 Suppl):247-50. PMID: 12691379; X-1

1712. Andronikou S, Mandelstam S, Fasulakis S. MRI and preoperative embolization of a nasal cavity haemangioma in a child. Australas Radiol. 2003 Dec;47(4):386-8. PMID: 14641190; X-2

1713. Andronikou S, McHugh K, Jadwat S, et al. MRI features of bilateral parotid haemangiomas of infancy. Eur Radiol. 2003 Apr;13(4):711-6. PMID: 12664107; X-3, X-4

1714. Aoyagi N, Kojima K, Kasai H. Review of spinal epidural cavernous hemangioma. Neurol Med Chir (Tokyo). 2003 Oct;43(10):471-5; discussion 6. PMID: 14620197; X-1

1715. Bejarano PA, Serrano MF, Casillas J, et al. Concurrent infantile hemangioendothelioma and mesenchymal hamartoma in a developmentally arrested liver of an infant requiring hepatic transplantation. Pediatr Dev Pathol. 2003 Nov-Dec;6(6):552-7. PMID: 15018455; X-1, X-2

1716. Bonaga S, Bardi C, Gigante C, et al. Synovial involvement in hemangiomatosis. Arch Orthop Trauma Surg. 2003 Apr;123(2-3):102-6. PMID: 12721689; X-1

1717. Brasanac D, Janic D, Boricic I, et al. Retroperitoneal kaposiform hemangioendothelioma with tufted angioma-like features in an infant with Kasabach-Merritt syndrome. Pathol Int. 2003 Sep;53(9):627-31. PMID: 14507321; X-1

1718. Caldarella A, Buccoliero AM, Taddei A, et al. Hemangioma of the umbilical cord: report of a case. Pathol Res Pract. 2003;199(1):51-5. PMID: 12650519; X-1

1719. Cansiz H, Yener M, Dervisoglu S, et al. Hemangioendothelioma of the frontal bone in a child. J Craniofac Surg. 2003 Sep;14(5):724-8. PMID: 14501337; X-1

1720. Cansiz H, Yener M, Kalekoglu N, et al. Arteriovenous malformation of the maxillary sinus and mandible: a case report. Ear Nose Throat J. 2003 Aug;82(8):608-10, 12, 14. PMID: 14503098; X-1

1721. Chang SE, Roh KH, Lee MW, et al. Microvenular hemangioma in a boy with acute myelogenous leukemia. Pediatr Dermatol. 2003 May-Jun;20(3):266-7. PMID: 12787280; X-1

1722. Chen CC, Kong MS, Yang CP, et al. Hepatic hemangioendothelioma in children: analysis of thirteen cases. Acta Paediatr Taiwan. 2003 Jan-Feb;44(1):8-13. PMID: 12800377; X-1

1723. Chung MT, Chen CH, Chiu CH, et al. Successful nonoperative therapy for Kaposiform hemangioendothelioma involving the neck: report of 1 case. Otolaryngol Head Neck Surg. 2003 Nov;129(5):605-7. PMID: 14595290; X-1

1724. Coats DK, O'Neil JW, D'Elia VJ, et al. SubTenon's infusion of steroids for treatment of orbital hemangiomas. Ophthalmology. 2003 Jun;110(6):1255-9. PMID: 12799256; X-4

1725. Comi AM, Hunt P, Vawter MP, et al. Increased fibronectin expression in sturge-weber syndrome fibroblasts and brain tissue. Pediatr Res. 2003 May;53(5):762-9. PMID: 12621118; X-1

1726. Coras B, Hohenleutner U, Landthaler M, et al. Spindle cell hemangioma. Dermatol Surg. 2003 Aug;29(8):875-8. PMID: 12859394; X-1, X-2

1727. Correa-Rivas MS, Colon-Gonzalez G, Lugo-Vicente H. Cavernous hemangioma presenting as a right adnexal mass in a child. P R Health Sci J. 2003 Sep;22(3):311-3. PMID: 14619460; X-1

1728. Dasgupta NR, Bentz ML. Nasal gliomas: identification and differentiation from hemangiomas. J Craniofac Surg. 2003 Sep;14(5):736-8. PMID: 14501339; X-1

1729. Davies BW, Fraser N, Najmaldin AS, et al. A prospective study of neonatal inguinal herniotomy: the problem of the postoperative hydrocele. Pediatr Surg Int. 2003 Apr;19(1-2):68-70. PMID: 12721728; X-1

1730. Douri T. Segmental facial hemangioma accompanied by brain anomalies: report of a case. Dermatol Online J. 2003 Dec;9(5):22. PMID: 14996395; X-2

1731. Dumortier J, Vaillant E, Boillot O, et al. Diagnosis and treatment of biliary obstruction caused by portal cavernoma. Endoscopy. 2003 May;35(5):446-50. PMID: 12701019; X-1

1732. Feller L, Lemmer J. Encephalotrigeminal angiomatosis. Sadj. 2003 Oct;58(9):370-3. PMID: 14964051; X-1

1733. Firth PG, Ahmed MI. Systemic embolism in an infant following haemangioma embolization: a two-step process. Paediatr Anaesth. 2003 Oct;13(8):728-32. PMID: 14535915; X-1

1734. Forschner A, Harms D, Metzler G, et al. Ulcerated epithelioid hemangioendothelioma of the foot in childhood. J Am Acad Dermatol. 2003 Jul;49(1):113-6. PMID: 12833020; X-1

1735. Franc-Guimond J, Houle AM, Barrieras D. The Proteus syndrome associated with life threatening hematuria. J Urol. 2003 Dec;170(6 Pt 1):2418-9. PMID: 14634442; X-1

1736. Giaoui L, Princ G, Chiras J, et al. Treatment of vascular malformations of the mandible: a description of 12 cases. Int J Oral Maxillofac Surg. 2003 Apr;32(2):132-6. PMID: 12729771; X-1

1737. Gold L, Nazarian LN, Johar AS, et al. Characterization of maxillofacial soft tissue vascular anomalies by ultrasound and color Doppler imaging: an adjuvant to computed tomography and magnetic resonance imaging. J Oral Maxillofac Surg. 2003 Jan;61(1):19-31. PMID: 12524603; X-1

1738. Gordon S. Birthmark basics. Parents. 2003;78(8):83. PMID: X-2

1739. Gralla J, Ganslandt O, Kober H, et al. Image-guided removal of supratentorial cavernomas in critical brain areas: application of neuronavigation and intraoperative magnetic resonance imaging. Minim Invasive Neurosurg. 2003 Apr;46(2):72-7. PMID: 12761675; X-1

1740. Groot D, Rao J, Johnston P, et al. Algorithm for using a long-pulsed Nd:YAG laser in the treatment of deep cutaneous vascular lesions. Dermatol Surg. 2003 Jan;29(1):35-42. PMID: 12534510; X-1

1741. Guschmann M, Henrich W, Entezami M, et al. Chorioangioma--new insights into a well-known problem. I. Results of a clinical and morphological study of 136 cases. J Perinat Med. 2003;31(2):163-9. PMID: 12747233; X-1

1742. Hadfield PJ, Lloyd-Faulconbridge RV, Almeyda J, et al. The changing indications for paediatric tracheostomy. Int J Pediatr Otorhinolaryngol. 2003 Jan;67(1):7-10. PMID: 12560142; X-3, X-4

1743. Hayashi N, Masumoto T, Okubo T, et al. Hemangiomas in the face and extremities: MR-guided sclerotherapy--optimization with monitoring of signal intensity changes in vivo. Radiology. 2003 Feb;226(2):567-72. PMID: 12563156; X-1

1744. Hohenleutner U, Landthaler M. Abstracts from the literature. Journal of Pediatrics. 2003;142(3):354-5. PMID: X-1

1745. Honda M, Toda K, Baba H, et al. Congenital cavernous angioma of the temporal bone: case report. Surg Neurol. 2003 Feb;59(2):120-3; discussion 3. PMID: 12648911; X-1

1746. Inuzuka M, Tomita K, Tokura Y, et al. Congenital self-healing reticulohistiocytosis presenting with hemorrhagic bullae. J Am Acad Dermatol. 2003 May;48(5 Suppl):S75-7. PMID: 12734483; X-1

1747. Ishikawa K, Saitoh M, Chida S. Detection of bladder hemangioma in a child by blood-pool scintigraphy. Pediatr Radiol. 2003 Jun;33(6):433-5. PMID: 12768257; X-1, X-2

1748. Jeon SY, Jeong JH, Kim HS, et al. Hemifacial degloving approach for medial maxillectomy: a modification of midfacial degloving approach. Laryngoscope. 2003 Apr;113(4):754-6. PMID: 12671442; X-1

1749. Kanamori Y, Hashizume K, Kitano Y, et al. Congenital extrahepatic portocaval shunt (Abernethy type 2), huge liver mass, and patent ductus arteriosus--a case report of its rare clinical presentation in a young girl. J Pediatr Surg. 2003 Apr;38(4):E15. PMID: 12677602; X-1

1750. Kaplan DL. Dermclinic. A photo quiz to hone dermatologic skills. Consultant. 2003;43(8):969. PMID: X-1

1751. Kasahara M, Kiuchi T, Haga H, et al. Monosegmental living-donor liver transplantation for infantile hepatic hemangioendothelioma. J Pediatr Surg. 2003 Jul;38(7):1108-11. PMID: 12861553; X-1

1752. Khong PL, Burrows PE, Kozakewich HP, et al. Fast-flow lingual vascular anomalies in the young patient: is imaging diagnostic? Pediatr Radiol. 2003 Feb;33(2):118-22. PMID: 12557068; X-2

1753. Kilde JD, Rhee JS, Balla AA, et al. Hemangioma of the sphenoid and ethmoid sinuses: two case reports. Ear Nose Throat J. 2003 Mar;82(3):217-21. PMID: 12696244; X-1, X-2

1754. Kiratli H, Bilgic S, Caglar M, et al. Intramuscular hemangiomas of extraocular muscles. Ophthalmology. 2003 Mar;110(3):564-8. PMID: 12623822; X-1, X-2

1755. Kleinman ME, Tepper OM, Capla JM, et al. Increased circulating AC133+ CD34+ endothelial progenitor cells in children with hemangioma. Lymphat Res Biol. 2003;1(4):301-7. PMID: 15624558; X-3

1756. Konez O, Burrows PE, Mulliken JB, et al. Angiographic features of rapidly involuting congenital hemangioma (RICH). Pediatr Radiol. 2003 Jan;33(1):15-9. PMID: 12497230; X-1

1757. Konrad D, Ellis G, Perlman K. Spontaneous regression of severe acquired infantile hypothyroidism associated with multiple liver hemangiomas. Pediatrics. 2003 Dec;112(6 Pt 1):1424-6. PMID: 14654623; X-2

1758. Lau TK, Leung TY, Yu SC, et al. Prenatal treatment of chorioangioma by microcoil embolisation. Bjog. 2003 Jan;110(1):70-3. PMID: 12504940; X-1

1759. Lin DD, Barker PB, Kraut MA, et al. Early characteristics of Sturge-Weber syndrome shown by perfusion MR imaging and proton MR spectroscopic imaging. AJNR Am J Neuroradiol. 2003 Oct;24(9):1912-5. PMID: 14561628; X-1

1760. Lin MC, Chen CH, Chi CS. PHACE syndrome: report of one case. Acta Paediatr Taiwan. 2003 Nov-Dec;44(6):379-82. PMID: 14983664; X-2

1761. Lucas M, Costa AF, Garcia-Moreno JM, et al. Variable expression of cerebral cavernous malformations in carriers of a premature termination codon in exon 17 of the Krit1 gene. BMC Neurol. 2003 Jul 23;3:5. PMID: 12877753; X-1

1762. Ly JQ, Sanders TG, Mulloy JP, et al. Osseous change adjacent to soft-tissue hemangiomas of the extremities: correlation with lesion size and proximity to bone. AJR Am J Roentgenol. 2003 Jun;180(6):1695-700. PMID: 12760946; X-1

1763. Mathiesen T, Edner G, Kihlstrom L. Deep and brainstem cavernomas: a consecutive 8-year series. J Neurosurg. 2003 Jul;99(1):31-7. PMID: 12854740; X-1

1764. Matsumoto K, Nakanishi H, Koizumi Y, et al. Sclerotherapy of hemangioma with late involution. Dermatol Surg. 2003 Jun;29(6):668-71; discussion 71. PMID: 12786717; X-2

1765. Maymon R, Hermann G, Reish O, et al. Chorioangioma and its severe infantile sequelae: case report. Prenat Diagn. 2003 Dec 15;23(12):976-80. PMID: 14663833; X-1

1766. McQueen CT, Cullen RD. Endoscopic ablation of distal tracheal lesions using Nd:YAG contact laser. Int J Pediatr Otorhinolaryngol. 2003 Feb;67(2):181-3. PMID: 12623156; X-2

1767. Mendez R, Capdevila A, Tellado MG, et al. Kaposiform hemangioendothelioma associated with Milroy's disease (primary hereditary lymphedema). J Pediatr Surg. 2003 Jul;38(7):E9-12. PMID: 12861592; X-1

1768. Michel JL. Treatment of hemangiomas with 595 nm pulsed dye laser dermobeam. Eur J Dermatol. 2003 Mar-Apr;13(2):136-41. PMID: 12695128; X-3, X-4

1769. Miles MS, Brunssen SH. Psychometric properties of the parental stressor scale: infant hospitalization. Adv Neonatal Care. 2003 Aug;3(4):189-96. PMID: 14502526; X-1

1770. Miller KK, Giuffre RM, Kellner B, et al. Congenital right ventricular diverticulum in association with disseminated neonatal hemangiomatosis. Can J Cardiol. 2003 Mar 15;19(3):303-5. PMID: 12677288; X-1

1771. Morton DL, Hoon DS, Cochran AJ, et al. Lymphatic mapping and sentinel lymphadenectomy for early-stage melanoma: therapeutic utility and implications of nodal microanatomy and molecular staging for improving the accuracy of detection of nodal micrometastases. Ann Surg. 2003 Oct;238(4):538-49; discussion 49-50. PMID: 14530725; X-1

1772. Naiman AN, Ayari S, Froehlich P. Controlled risk of stenosis after surgical excision of laryngeal hemangioma. Arch Otolaryngol Head Neck Surg. 2003 Dec;129(12):1291-5. PMID: 14676154; X-4

1773. Ng SK, Soo G, Abdullah V, et al. Congenital glabellar hemangioma. Otolaryngol Head Neck Surg. 2003 Jul;129(1):161-2. PMID: 12869938; X-1

1774. Ng WT, Kong CK. Argon plasma coagulation for blue rubber bleb nevus syndrome in a female infant. Eur J Pediatr Surg. 2003 Apr;13(2):137-9. PMID: 12776249; X-1

1775. Nieto J, Hinojosa J, Munoz MJ, et al. Intraventricular cavernoma in pediatric age. Childs Nerv Syst. 2003 Jan;19(1):60-2. PMID: 12541090; X-1

1776. Odemis E, Cakir M, Aynaci FM. Rhombencephalosynapsis associated with cutaneous pretibial hemangioma in an infant. J Child Neurol. 2003 Mar;18(3):225-8. PMID: 12731648; X-1, X-2

1777. O'Keefe M, Lanigan B, Byrne SA. Capillary haemangioma of the eyelids and orbit: a clinical review of the safety and efficacy of intralesional steroid. Acta Ophthalmol Scand. 2003 Jun;81(3):294-8. PMID: 12780411; X-4

1778. Onesti GM, Mazzocchi M, Mezzana P, et al. Different types of embolization before surgical excision of haemangiomas of the face. Acta Chir Plast. 2003;45(2):55-60. PMID: 12921261; X-2

1779. Oviedo A, Abramson LP, Worthington R, et al. Congenital pulmonary capillary hemangiomatosis: Report of two cases and review of the literature. Pediatr Pulmonol. 2003 Sep;36(3):253-6. PMID: 12910588; X-1

1780. Pascual-Castroviejo I, Viano J, Pascual-Pascual SI, et al. Do cutaneous hemangiomas and internal vascular anomalies follow the same evolution? Neurology. 2003 Jul 8;61(1):140-1. PMID: 12847180; X-1

1781. Puig S, Aref H, Brunelle F. Double-needle sclerotherapy of lymphangiomas and venous angiomas in children: a simple technique to prevent complications. AJR Am J Roentgenol. 2003 May;180(5):1399-401. PMID: 12704058; X-1

1782. Rades D, Bajrovic A, Alberti W, et al. Is there a dose-effect relationship for the treatment of symptomatic vertebral hemangioma? Int J Radiat Oncol Biol Phys. 2003 Jan 1;55(1):178-81. PMID: 12504051; X-1

1783. Ramli N, Sachet M, Bao C, et al. Cerebrofacial venous metameric syndrome (CVMS) 3: Sturge-Weber syndrome with bilateral lymphatic/venous malformations of the mandible. Neuroradiology. 2003 Oct;45(10):687-90. PMID: 13680025; X-1

1784. Re M, Forte V, Berardi C, et al. Role of endoscopic CO2 laser surgery in the treatment of congenital infantile subglottic hemangioma. Experience in the Department of Otolaryngology, "Sick Children Hospital", Toronto, Canada. Acta Otorhinolaryngol Ital. 2003 Jun;23(3):175-9. PMID: 14677310; X-3, X-4

1785. Rehman SU, Hazir T, Nisar YB, et al. Blue rubber bleb nevus syndrome: associated with severe GI bleeding requiring one hundred blood transfusions. J Pak Med Assoc. 2003 Nov;53(11):570-3. PMID: 14738268; X-1

1786. Reich P, Winkler J, Straube A, et al. Molecular genetic investigations in the CCM1 gene in sporadic cerebral cavernomas. Neurology. 2003 Apr 8;60(7):1135-8. PMID: 12682320; X-1

1787. Ritter MR, Moreno SK, Dorrell MI, et al. Identifying potential regulators of infantile hemangioma progression through large-scale expression analysis: a possible role for the immune system and indoleamine 2,3 dioxygenase (IDO) during involution. Lymphat Res Biol. 2003;1(4):291-9. PMID: 15624557; X-1, X-3

1788. Roos JE, Pfiffner R, Stallmach T, et al. Infantile hemangioendothelioma. Radiographics. 2003 Nov-Dec;23(6):1649-55. PMID: 14615570; X-1

1789. Schiavetti A, De Pasquale MD, Di Salvo S, et al. Recombinant interferon alfa 2a in hepatic hemangiomatosis with congestive heart failure: a case report. Pediatr Hematol Oncol. 2003 Mar;20(2):161-5. PMID: 12554528; X-2

1790. Sefau SO, Dorey MW, Brownstein S, et al. Radiation-induced chorioretinal degeneration: a clinicopathological report of three cases. Can J Ophthalmol. 2003 Feb;38(1):57-62. PMID: 12608519; X-1

1791. Shenkar R, Elliott JP, Diener K, et al. Differential gene expression in human cerebrovascular malformations. Neurosurgery. 2003 Feb;52(2):465-77; discussion 77-8. PMID: 12535382; X-1

1792. Simon NP, Simon MW. Large cavernous hemangiomas: The need for closer monitoring. International Pediatrics. 2003;18(1):30-2. PMID: 2003109207; X-1

1793. Skorin Jr L. Can You Identify These Facial Findings? Consultant. 2003 01 Sep;43(10):1245-60. PMID: 2003434342; X-1

1794. Skorin L, Jr. Photo quiz: can you identify these facial findings? Consultant. 2003;43(10):1245--6, 50, 53 passim. PMID: X-1

1795. Skrinjaric I, Jukic J, Skrinjaric K, et al. Dental and minor physical anomalies in children with developmental disorders--a discriminant analysis. Coll Antropol. 2003 Dec;27(2):769-78. PMID: 14746170; X-1

1796. Slaughter K, Sullivan T, Boulton J, et al. Early surgical intervention as definitive treatment for ocular adnexal capillary haemangioma. Clin Experiment Ophthalmol. 2003 Oct;31(5):418-23. PMID: 14516430; X-4

1797. Soeda A, Sakai N, Iihara K, et al. Cobb syndrome in an infant: treatment with endovascular embolization and corticosteroid therapy: case report. Neurosurgery. 2003 Mar;52(3):711-5; discussion 4-5. PMID: 12590699; X-1, X-2

1798. Suziedelis AK. Cosmetic surgery for children with Down syndrome: the cruelest cut of all? Health Care Ethics USA. 2003;11(1):E1. PMID: 16184692; X-1

1799. Szabo I, Szabo B. Expanding masses of the posterior orbit. Oftalmologia. 2003;58(3):39-44. PMID: 14702731; X-5

1800. Szymik-Kantorowicz S, Partyka L, Dembinska-Kiec A, et al. Vascular endothelial growth factor in monitoring therapy of hepatic haemangioendothelioma. Med Pediatr Oncol. 2003 Mar;40(3):196-7. PMID: 12518353; X-1

1801. Tan C, Alphonso N, Anderson D, et al. Mediastinal haemangiomas in children. Eur J Cardiothorac Surg. 2003 Jun;23(6):1065-7. PMID: 12829094; X-2

1802. Tastekin A, Kantarci M, Onbas O, et al. Superior sternal cleft and minor hemangiomas in a newborn. Genet Couns. 2003;14(3):349-52. PMID: 14577681; X-1

1803. Toida M, Hasegawa T, Watanabe F, et al. Lobular capillary hemangioma of the oral mucosa: clinicopathological study of 43 cases with a special reference to immunohistochemical characterization of the vascular elements. Pathol Int. 2003 Jan;53(1):1-7. PMID: 12558863; X-1

1804. Tsao MN, Schwartz ML, Bernstein M, et al. Capillary hemangioma of the cavernous sinus. Report of two cases. J Neurosurg. 2003 Jan;98(1):169-74. PMID: 12546367; X-1, X-2

1805. Tubbs RS, Wellons IJ, Oakes WJ. Capillary hemangioma of the calvaria. Pediatr Neurosurg. 2003 Jul;39(2):112. PMID: 12845203; X-2

1806. Van Aalst JA, Bhuller A, Sadove AM. Pediatric vascular lesions. J Craniofac Surg. 2003 Jul;14(4):566-83. PMID: 12867875; X-1, X-2

1807. Van Calenbergh F, Demaerel P, Sciot R, et al. Acquired cerebellar cavernous angioma following childhood radiotherapy in a patient with neurofibromatosis type 1. Acta Neurol Belg. 2003 Jun;103(2):103-6. PMID: 12892005; X-1

1808. Wananukul S, Nuchprayoon I, Seksarn P. Treatment of Kasabach-Merritt syndrome: a stepwise regimen of prednisolone, dipyridamole, and interferon. Int J Dermatol. 2003 Sep;42(9):741-8. PMID: 12956695; X-1

1809. Waner M, North PE, Scherer KA, et al. The nonrandom distribution of facial hemangiomas. Arch Dermatol. 2003 Jul;139(7):869-75. PMID: 12873881; X-3

1810. Wang LY, Hung HY, Lee KS. Infantile subglottic hemangioma treated by intralesional steroid injection: report of one case. Acta Paediatr Taiwan. 2003 Jan-Feb;44(1):35-7. PMID: 12800382; X-2

1811. Warmann S, Bertram H, Kardorff R, et al. Interventional treatment of infantile hepatic hemangioendothelioma. J Pediatr Surg. 2003 Aug;38(8):1177-81. PMID: 12891488; X-1

1812. Watters K, O'Marcaigh A, Canny G, et al. Management of a large bronchial haemangioma in an infant. Int J Pediatr Otorhinolaryngol. 2003 Apr;67(4):429-33. PMID: 12663120; X-2

1813. Werle AH, Kirse DJ, Nopper AJ, et al. Osseous hemangioma of the maxilla in an infant. Otolaryngol Head Neck Surg. 2003 Jun;128(6):906-9. PMID: 12825048; X-1, X-2

1814. Williams EF, 3rd, Hochman M, Rodgers BJ, et al. A psychological profile of children with hemangiomas and their families. Arch Facial Plast Surg. 2003 May-Jun;5(3):229-34. PMID: 12756116; X-3

1815. Williamson A, Patrylo PR, Lee S, et al. Physiology of human cortical neurons adjacent to cavernous malformations and tumors. Epilepsia. 2003 Nov;44(11):1413-9. PMID: 14636349; X-1

1816. Winstanley D, Graham B, Blair M, et al. Sacral hemangioma with sinus tract in an infant. Pediatr Dermatol. 2003 May-Jun;20(3):221-4. PMID: 12787270; X-1, X-2

1817. Witters I, Van Damme MT, Ramaekers P, et al. Benign multiple diffuse neonatal hemangiomatosis after a pregnancy complicated by polyhydramnios and a placental chorioangioma. Eur J Obstet Gynecol Reprod Biol. 2003 Jan 10;106(1):83-5. PMID: 12475589; X-2

1818. Youssef JS, Quraishi HA. Cervicofacial hemangioma and its association with PHACE syndrome. Otolaryngol Head Neck Surg. 2003 May;128(5):758-60. PMID: 12748574; X-2

1819. Zacharia TT, Ittoop A, Perumpillichira JJ, et al. Sonographic appearance of a congenital parotid gland hemangiolymphangioma simulating malignancy in an infant. J Clin Ultrasound. 2003 Nov-Dec;31(9):493-6. PMID: 14595742; X-1

1820. Abe M, Tabuchi K, Tanaka S, et al. Capillary hemangioma of the central nervous system. J Neurosurg. 2004 Jul;101(1):73-81. PMID: 15255254; X-1

1821. Abid N, Rashid A. Haemangioma presenting as perianal ulcer in neonates. J Perinatol. 2004 May;24(5):327-8. PMID: 15116132; X-3, X-4

1822. Agostinelli C, Roncaroli F, Galassi E, et al. Leptomeningeal hemangioblastoma. Case illustration. J Neurosurg. 2004 Aug;101(1 Suppl):122. PMID: 16206984; X-1

1823. Al-Attar M, Verma R, Shannon RS, et al. Focal nodular hyperplasia in a child with hemihypertrophy and multiple cutaneous vascular malformations. Australas Radiol. 2004 Mar;48(1):77-9. PMID: 15027928; X-1

1824. Amer OT, Abd El-Rahma HA, Sherief LM, et al. Role of some viral infections in neonatal cholestasis. Egypt J Immunol. 2004;11(2):149-55. PMID: 16734127; X-1

1825. Andrade ZR, Garippo AL, Saldiva PH, et al. Immunohistochemical and in situ detection of cytomegalovirus in lung autopsies of children immunocompromised by secondary interstitial pneumonia. Pathol Res Pract. 2004;200(1):25-32. PMID: 15157047; X-1

1826. Aviles R, Boyce TG, Thompson DM. Pneumocystis carinii pneumonia in a 3-month-old infant receiving high-dose corticosteroid therapy for airway hemangiomas. Mayo Clin Proc. 2004 Feb;79(2):243-5. PMID: 14959920; X-2

1827. Bains HS, Cirino AC, Ticho BH, et al. Photodynamic therapy using verteporfin for a diffuse choroidal hemangioma in Sturge-Weber syndrome. Retina. 2004 Feb;24(1):152-5. PMID: 15076958; X-1

1828. Bakaris S, Karabiber H, Yuksel M, et al. Case of large placental chorioangioma associated with diffuse neonatal hemangiomatosis. Pediatr Dev Pathol. 2004 May-Jun;7(3):258-61. PMID: 15022059; X-1, X-2

1829. Banerjee R, Bharucha BA, Bhangale T, et al. Use of Blood Viscosity Parameters for Evaluation of Acute Idiopathic Hemiplegia of Childhood in Children of Indian Origin. International Pediatrics. 2004;19(1):48-51. PMID: 2004122492; X-1

1830. Barankin B. Dermatology case challenge. Patient Care. 2004;38(12):67-8. PMID: X-2

1831. Barankin B. Dermatology case challenge: a "red mark and bruising" on an infant's face. Patient Care for the Nurse Practitioner. 2004:1p. PMID: X-1

1832. Bent JP. Airway hemangiomas: contemporary management. Lymphat Res Biol. 2004;2(1):56-60. PMID: 15609928; X-1, X-2

1833. Bernal B, Altman N. Visual functional magnetic resonance imaging in patients with Sturge-Weber syndrome. Pediatr Neurol. 2004 Jul;31(1):9-15. PMID: 15246485; X-1

1834. Bhattacharya JJ, Luo CB, Alvarez H, et al. PHACES syndrome: a review of eight previously unreported cases with late arterial occlusions. Neuroradiology. 2004 Mar;46(3):227-33. PMID: 14758450; X-3

1835. Bilkay U, Tokat C, Ozek C, et al. Reconstruction of congenital absent columella. J Craniofac Surg. 2004 Jan;15(1):60-3. PMID: 14704565; X-1

1836. Blereau RP. Do you recognize these disorders? Consultant. 2004 01 Apr;44(4):605-10. PMID: 2005087462; X-1

1837. Blereau RP. Photo quiz. Do you recognize these disorders? Consultant. 2004;44(4):605. PMID: X-1

1838. Bowman RJ, Nischal KK, Patel K, et al. An ultrasound based classification of periocular haemangiomas. Br J Ophthalmol. 2004 Nov;88(11):1419-21. PMID: 15489485; X-3, X-4

1839. Brook I. Microbiology of infected hemangiomas in children. Pediatr Dermatol. 2004 Mar-Apr;21(2):113-6. PMID: 15078348; X-1, X-3

1840. Bukhari IA. Impetigo herpetiformis in a primigravida: successful treatment with etretinate. J Drugs Dermatol. 2004 Jul-Aug;3(4):449-51. PMID: 15303793; X-1

1841. Chen C, Yu Y, Zhen H. Sturge-Weber syndrome associated with early diffuse choroidal hemangiaoma: a case report. Yan Ke Xue Bao. 2004 Sep;20(3):168-70. PMID: 15499725; X-1

1842. Clark C, Cameron H, Moseley H, et al. Treatment of superficial cutaneous vascular lesions: experience with the KTP 532 nm laser. Lasers Med Sci. 2004;19(1):1-5. PMID: 15316851; X-1

1843. Cohen BA. Neonatal lesions: another baby and another cutaneous lesion -- and more on efficient recognition and management. Contemp Pediatr. 2004;21(10):39--40, 1, 5 passim. PMID: X-1

1844. Cummings TJ, George TM, Fuchs HE, et al. The pathology of extracranial scalp and skull masses in young children. Clin Neuropathol. 2004 Jan-Feb;23(1):34-43. PMID: 14986932; X-2

1845. Demir Z, Oktem F, Celebioglu S. Rare case of intramasseteric cavernous hemangioma in a three-year-old boy: a diagnostic dilemma. Ann Otol Rhinol Laryngol. 2004 Jun;113(6):455-8. PMID: 15224828; X-1

1846. Denier C, Labauge P, Brunereau L, et al. Clinical features of cerebral cavernous malformations patients with KRIT1 mutations. Ann Neurol. 2004 Feb;55(2):213-20. PMID: 14755725; X-1

1847. Desuter GR, El Makhloufi K, Francois GJ, et al. Postcricoid hemangioma: an overlooked cause of dysphagia in infants?-a case report. Dysphagia. 2004 Winter;19(1):48-51. PMID: 14745646; X-2

1848. Donati D, Albisinni U, Zavatta M, et al. Long-term roentgenographic evaluation of proximal femur prosthesis after tumor resection. Chir Organi Mov. 2004 Jul-Aug;89(3):191-203. PMID: 15751586; X-1

1849. Dondon MG, de Vathaire F, Shamsaldin A, et al. Cancer mortality after radiotherapy for a skin hemangioma during childhood. Radiother Oncol. 2004 Jul;72(1):87-93. PMID: 15236880; X-1, X-3

1850. Eber E. Short case presentation. Right-sided subglottic haemangioma. Paediatr Respir Rev. 2004 Mar;5(1):90-1. PMID: 15230262; X-1, X-2

1851. Erasmus CE, Beems T, Rotteveel JJ. Frontal ataxia in childhood. Neuropediatrics. 2004 Dec;35(6):368-70. PMID: 15627946; X-1

1852. Fawcett SL, Grant I, Hall PN, et al. Vincristine as a treatment for a large haemangioma threatening vital functions. Br J Plast Surg. 2004 Mar;57(2):168-71. PMID: 15037175; X-2

1853. Fitz EW, Newman SA. Neuro-ophthalmology of von Hippel-Lindau. Curr Neurol Neurosci Rep. 2004 Sep;4(5):384-90. PMID: 15324605; X-1

1854. Fraunfelder FW, Fraunfelder FT, Corbett JJ. Isotretinoin-associated intracranial hypertension. Ophthalmology. 2004 Jun;111(6):1248-50. PMID: 15177980; X-1

1855. Freese PM, Svalander CT, Molne J, et al. Renal allograft glomerulopathy and the value of immunohistochemistry. Clin Nephrol. 2004 Oct;62(4):279-86. PMID: 15524058; X-1

1856. George ME, Sharma V, Jacobson J, et al. Adverse effects of systemic glucocorticosteroid therapy in infants with hemangiomas. Arch Dermatol. 2004 Aug;140(8):963-9. PMID: 15313812; X-4

1857. Goyal R, Watts P, Lane CM, et al. Adrenal suppression and failure to thrive after steroid injections for periocular hemangioma. Ophthalmology. 2004 Feb;111(2):389-95. PMID: 15019396; X-3, X-4

1858. Greene AK, Rogers GF, Mulliken JB. Management of parotid hemangioma in 100 children. Plast Reconstr Surg. 2004 Jan;113(1):53-60. PMID: 14707622; X-3, X-4

1859. Gulati G, Sharma S, Kothari SS, et al. Comparison of echo and MRI in the imaging evaluation of intracardiac masses. Cardiovasc Intervent Radiol. 2004 Sep-Oct;27(5):459-69. PMID: 15383848; X-1

1860. Gurelik M, Ozum U, Erdogan H, et al. Orbital lymphangioma and its association with intracranial venous angioma. Br J Neurosurg. 2004 Apr;18(2):168-70. PMID: 15176559; X-1

1861. Hall P, Adami HO, Trichopoulos D, et al. Effect of low doses of ionising radiation in infancy on cognitive function in adulthood: Swedish population based cohort study. Bmj. 2004 Jan 3;328(7430):19. PMID: 14703539; X-3

1862. Hayashi S, Kondoh T, Morishita A, et al. Congenital cavernous angioma exhibits a progressive decrease in size after birth. Childs Nerv Syst. 2004 Mar;20(3):199-203. PMID: 14704811; X-1

1863. Hockstein NG, Samadi DS, Gendron K, et al. Pediatric submandibular triangle masses: a fifteen-year experience. Head Neck. 2004 Aug;26(8):675-80. PMID: 15287034; X-1

1864. Ikeda T, Shimamoto K, Tanji N, et al. Cavernous hemangioma of the urinary bladder in an 8-year-old child. Int J Urol. 2004 Jun;11(6):429-31. PMID: 15157217; X-1

1865. Jansen FE, van der Worp HB, van Huffelen A, et al. Sturge-Weber syndrome and paroxysmal hemiparesis: epilepsy or ischaemia? Dev Med Child Neurol. 2004 Nov;46(11):783-6. PMID: 15540641; X-1

1866. Karian VE, Buchanan T, Lord D, et al. Focus on skin disorders: vascular anomalies. "But they told us she had a hemangioma....". Contemp Pediatr. 2004;21(7):51--4, 6-7, 61-4 passim. PMID: X-1

1867. Kim HL, Im SA, Lim GY, et al. High grade hemangioendothelioma of the temporal bone in a child: a case report. Korean J Radiol. 2004 Jul-Sep;5(3):214-7. PMID: 15467419; X-1

1868. Kitagawa H, Kawase H, Wakisaka M, et al. Six cases of children with a benign cervical tumor who required tracheostomy. Pediatr Surg Int. 2004 Jan;20(1):51-4. PMID: 14689216; X-2

1869. Kitagawa N, Ohhama Y, Fukuzato Y, et al. Pericardial hemangioma presenting fetal cardiac tamponade and postnatal bronchostenosis. Pediatr Surg Int. 2004 May;20(5):376-7. PMID: 15221363; X-1, X-2

1870. Kocer U, Ozdemir R, Tiftikcioglu YO, et al. Soft tissue hemangioma formation within a previously excised intraosseous hemangioma site. J Craniofac Surg. 2004 Jan;15(1):82-3. PMID: 14704569; X-1, X-2

1871. Kumar S, Muranjan MN, Tullu MS, et al. Incomplete monosymptomatic leptomeningeal angiomatosis. Indian J Pediatr. 2004 Oct;71(10):947. PMID: 15531846; X-1

1872. Kuo JS, Chen JC, Yu C, et al. Gamma knife radiosurgery for benign cavernous sinus tumors: quantitative analysis of treatment outcomes. Neurosurgery. 2004 Jun;54(6):1385-93; discussion 93-4. PMID: 15157295; X-1

1873. Labeodan OA. Choroid plexus angioma in a newborn presenting with hydrocephalus. Pediatr Neurosurg. 2004 May-Jun;40(3):153-4. PMID: 15367812; X-1

1874. Lam SM, Williams EF, 3rd. Practical considerations in the treatment of capillary vascular malformations, or port wine stains. Facial Plast Surg. 2004 Feb;20(1):71-6. PMID: 15034817; X-1

1875. Lolekha R, Chokephaibulkit K, Yoksan S, et al. Diagnosis of dengue infection using various diagnostic tests in the early stage of illness. Southeast Asian J Trop Med Public Health. 2004 Jun;35(2):391-5. PMID: 15691143; X-1

1876. Martinez AE, Robinson MJ, Alexis JB. Kaposiform hemangioendothelioma associated with nonimmune fetal hydrops. Arch Pathol Lab Med. 2004 Jun;128(6):678-81. PMID: 15163230; X-1

1877. Mathes EF, Haggstrom AN, Dowd C, et al. Clinical characteristics and management of vascular anomalies: findings of a multidisciplinary vascular anomalies clinic. Arch Dermatol. 2004 Aug;140(8):979-83. PMID: 15313815; X-3, X-4

1878. Metz BJ, Rubenstein MC, Levy ML, et al. Response of ulcerated perineal hemangiomas of infancy to becaplermin gel, a recombinant human platelet-derived growth factor. Arch Dermatol. 2004 Jul;140(7):867-70. PMID: 15262700; X-4

1879. Metzelder ML, Springer A, August C, et al. Neonatal hemoperitoneum caused by a congenital liver angioma. J Pediatr Surg. 2004 Feb;39(2):234-6. PMID: 14966751; X-1

1880. Mikuni N, Satow T, Taki J, et al. Endotracheal tube electrodes to map and monitor activities of the vagus nerve intraoperatively. Technical note. J Neurosurg. 2004 Sep;101(3):536-40. PMID: 15352615; X-1

1881. Miyagami M, Katayama Y. Long-term prognosis of hemangioblastomas of the central nervous system: clinical and immunohistochemical study in relation to recurrence. Brain Tumor Pathol. 2004;21(2):75-82. PMID: 15700837; X-1

1882. Miyama S, Goto T. Leptomeningeal angiomatosis with infantile spasms. Pediatr Neurol. 2004 Nov;31(5):353-6. PMID: 15519118; X-1

1883. Mo JQ, Dimashkieh HH, Bove KE. GLUT1 endothelial reactivity distinguishes hepatic infantile hemangioma from congenital hepatic vascular malformation with associated capillary proliferation. Hum Pathol. 2004 Feb;35(2):200-9. PMID: 14991538; X-3, X-4

1884. Mounayer C, Benndorf G, Bisdorff A, et al. Facial infantile hemangiopericytoma resembling an arteriovenous malformation. J Neuroradiol. 2004 Jun;31(3):227-30. PMID: 15356450; X-1

1885. Mulliken JB, Anupindi S, Ezekowitz RA, et al. Case records of the Massachusetts General Hospital. Weekly clinicopathological exercises. Case 13-2004. A newborn girl with a large cutaneous lesion, thrombocytopenia, and anemia. N Engl J Med. 2004 Apr 22;350(17):1764-75. PMID: 15103004; X-1

1886. Muniz AE. Sturge-Weber syndrome presenting as an acute life-threatening event. Pediatr Emerg Care. 2004 Sep;20(9):610-2. PMID: 15599265; X-1

1887. Murakami K, Umezawa K, Kaimori M, et al. Cavernous angioma presenting as epilepsy 13 years after initial diagnosis. J Clin Neurosci. 2004 May;11(4):430-2. PMID: 15080966; X-1

1888. Neudorfer M, Leibovitch I, Stolovitch C, et al. Intraorbital and periorbital tumors in children--value of ultrasound and color Doppler imaging in the differential diagnosis. Am J Ophthalmol. 2004 Jun;137(6):1065-72. PMID: 15183791; X-3, X-4

1889. Nishimura Y, Tajima G, Dwi Bahagia A, et al. Differential diagnosis of neonatal mild hypergalactosaemia detected by mass screening: clinical significance of portal vein imaging. J Inherit Metab Dis. 2004;27(1):11-8. PMID: 14970742; X-1

1890. O'Hagan AH, Irvine AD, Sands A, et al. Miliary neonatal hemangiomatosis with fulminant heart failure and cardiac septal hypertrophy in two infants. Pediatr Dermatol. 2004 Jul-Aug;21(4):469-72. PMID: 15283793; X-1

1891. Okahashi K, Sugimoto K, Iwai M, et al. Intra-articular synovial hemangioma; a rare cause of knee pain and swelling. Arch Orthop Trauma Surg. 2004 Oct;124(8):571-3. PMID: 15340750; X-1

1892. Ozcan C, Apa DD, Gorur K. Pediatric lobular capillary hemangioma of the nasal cavity. Eur Arch Otorhinolaryngol. 2004 Sep;261(8):449-51. PMID: 14652770; X-1, X-2

1893. Pagliai KA, Cohen BA. Pyogenic granuloma in children. Pediatr Dermatol. 2004 Jan-Feb;21(1):10-3. PMID: 14871318; X-1

1894. Patel A, Davies SJ, Sandler PJ. The potentially fatal vascular anomaly and orthodontic treatment--a case report. Dent Update. 2004 May;31(4):230-2, 5-6. PMID: 15188530; X-1

1895. Pransky SM, Canto C. Management of subglottic hemangioma. Curr Opin Otolaryngol Head Neck Surg. 2004 Dec;12(6):509-12. PMID: 15548909; X-1, X-2

1896. Pulidori M, Capuano C, Mouchaty H, et al. Intramuscular thrombosed arteriovenous hemangioma of the upper right arm mimicking a neuroma of the ulnar nerve: case report. Neurosurgery. 2004 Mar;54(3):770-1; discusion 1-2. PMID: 15028157; X-1

1897. Rahbar R, Nicollas R, Roger G, et al. The biology and management of subglottic hemangioma: past, present, future. Laryngoscope. 2004 Nov;114(11):1880-91. PMID: 15510009; X-3, X-4

1898. Ramseier LE, Exner GU. Arthropathy of the knee joint caused by synovial hemangioma. J Pediatr Orthop. 2004 Jan-Feb;24(1):83-6. PMID: 14676540; X-1

1899. Ray R, Rishi A, Venugopal P, et al. Hemangioma of the tricuspid valve: a report of two cases with review of literature. Cardiovasc Pathol. 2004 Mar-Apr;13(2):120-2. PMID: 15033163; X-1, X-2

1900. Reinisch JF, Kim RY, Harshbarger RJ, et al. Surgical management of parotid hemangioma. Plast Reconstr Surg. 2004 Jun;113(7):1940-8. PMID: 15253181; X-4

1901. Rezvani M, Yager JY, Hartfield DS. Group A streptococcal meningitis as a complication of an infected capillary haemangioma. Eur J Pediatr. 2004 Jan;163(1):19-21. PMID: 14610671; X-2

1902. Rizzo R, Pavone L, Pero G, et al. A neurocutaneous disorder with a severe course: Wyburn-Mason's syndrome. J Child Neurol. 2004 Nov;19(11):908-11. PMID: 15658797; X-1

1903. Santoro A, Piccirilli M, Frati A, et al. Intramedullary spinal cord cavernous malformations: report of ten new cases. Neurosurg Rev. 2004 Apr;27(2):93-8. PMID: 14714194; X-1

1904. Sar C, Eralp L. Double thoracic vertebral hemangioma causing complete paraplegia. Am J Orthop (Belle Mead NJ). 2004 Feb;33(2):81-4, 57. PMID: 15005597; X-1

1905. Scott IU, Gorscak J, Gass JD, et al. Anatomic and visual acuity outcomes following thermal laser photocoagulation or photodynamic therapy for symptomatic circumscribed choroidal hemangioma with associated serous retinal detachment. Ophthalmic Surg Lasers Imaging. 2004 Jul-Aug;35(4):281-91. PMID: 15305551; X-1

1906. Sharif K, English M, Ramani P, et al. Management of hepatic epithelioid haemangio-endothelioma in children: what option? Br J Cancer. 2004 Apr 19;90(8):1498-501. PMID: 15083175; X-1

1907. Shields CL, Mashayekhi A, Luo CK, et al. Optical coherence tomography in children: analysis of 44 eyes with intraocular tumors and simulating conditions. J Pediatr Ophthalmol Strabismus. 2004 Nov-Dec;41(6):338-44. PMID: 15609518; X-1, X-2

1908. Shields JA, Shields CL, Scartozzi R. Survey of 1264 patients with orbital tumors and simulating lesions: The 2002 Montgomery Lecture, part 1. Ophthalmology. 2004 May;111(5):997-1008. PMID: 15121380; X-1, X-2

1909. Sidwell RU, Daubeney PE, Porter W, et al. Neonatal hemangiomatosis and atrial septal defect: a rare cause of right heart failure in infancy. Pediatr Dermatol. 2004 Jan-Feb;21(1):66-9. PMID: 14871331; X-1, X-2

1910. Stephen-Haynes J. Vascular birthmarks: a care study of an infant with haemangioma. Br J Nurs. 2004 Jan 22-Feb 11;13(2):87-93. PMID: 14997065; X-2

1911. Sterker I, Grafe G. Periocular hemangiomas in childhood--functional and esthetic results. Strabismus. 2004 Jun;12(2):103-10. PMID: 15672933; X-3, X-4

1912. Sunil TM. Intramuscular hemangioma complicated by a Volkmann's like contracture of the forearm muscles. Indian Pediatr. 2004 Mar;41(3):270-3. PMID: 15064516; X-1

1913. Swietlinski J, Maruniak-Chudek I, Niemir ZI, et al. A case of atypical congenital nephrotic syndrome. Pediatr Nephrol. 2004 Mar;19(3):349-52. PMID: 14714170; X-1, X-2

1914. Tasca RA, Williams RG. Capillary haemangioma of the nasal cavity in a 7-week-old baby--successful treatment using intralesional steroid injection. Int J Pediatr Otorhinolaryngol. 2004 Mar;68(3):365-7. PMID: 15129949; X-1, X-2

1915. Tubbs RS, Wellons JC, 3rd, Iskandar BJ, et al. Isolated flat capillary midline lumbosacral hemangiomas as indicators of occult spinal dysraphism. J Neurosurg. 2004 Feb;100(2 Suppl Pediatrics):86-9. PMID: 14758934; X-3, X-4

1916. Ulgen T, Turhan T, Yurtseven T, et al. Simple anterior orbitotomy. Minim Invasive Neurosurg. 2004 Apr;47(2):115-8. PMID: 15257486; X-1

1917. Walsh R, Harrington J, Beneck D, et al. Congenital infantile hepatic hemangioendothelioma type II treated with orthotopic liver transplantation. J Pediatr Hematol Oncol. 2004 Feb;26(2):121-3. PMID: 14767204; X-1

1918. Walsh SRA, Leung AKC, Fong JHS, et al. Photo diagnosis. Canadian Journal of Diagnosis. 2004;21(6):44. PMID: X-1

1919. Wasserman BN, Medow NB, Homa-Palladino M, et al. Treatment of periocular capillary hemangiomas. J aapos. 2004 Apr;8(2):175-81. PMID: 15088053; X-1

1920. Welsh O, Olazaran Z, Gomez M, et al. Treatment of infantile hemangiomas with short-term application of imiquimod 5% cream. J Am Acad Dermatol. 2004 Oct;51(4):639-42. PMID: 15389206; X-4

1921. Winkler D, Lindner D, Trantakis C, et al. Cavernous malformations--navigational supported surgery. Minim Invasive Neurosurg. 2004 Feb;47(1):24-8. PMID: 15100928; X-1

1922. Wong KK, Sandor GG, Sett SS. Isolated haemangioma of the tricuspid valve. Cardiol Young. 2004 Jun;14(3):324. PMID: 15680028; X-1, X-2

1923. Woo SJ, Kim CJ, Yu YS. Cavernous hemangioma of the iris in an infant. J aapos. 2004 Oct;8(5):499-501. PMID: 15492746; X-1, X-2

1924. Wortsman XC, Holm EA, Wulf HC, et al. Real-time spatial compound ultrasound imaging of skin. Skin Res Technol. 2004 Feb;10(1):23-31. PMID: 14731245; X-1

1925. Wowra B, Muacevic A, Muller-Schunk S, et al. Special indications in gamma knife surgery. Acta Neurochir Suppl. 2004;91:89-102. PMID: 15707030; X-1

1926. Wurm G, Fellner FA. Implementation of T2*-weighted MR for multimodal image guidance in cerebral cavernomas. Neuroimage. 2004 Jun;22(2):841-6. PMID: 15193613; X-1

1927. Yan J, Wu Z. Cavernous hemangioma of the orbit: analysis of 214 cases. Orbit. 2004 Mar;23(1):33-40. PMID: 15513018; X-1

1928. Zawadzka-Glos L, Zajac B, Kaczmarczyk A. Causes of laryngeal stridor in children. New Medicine. 2004;7(3):80-2. PMID: 2005279456; X-1

1929. . Photoclinic: foresee your next patient. Klippel-Trenaunay-Weber syndrome. Consultant. 2005;45(6):700-. PMID: X-1

1930. . Photoclinic: foresee your next patient. Deep (cavernous) hemangioma. Consultant. 2005;45(6):706-. PMID: X-1

1931. Aaberg TM, Jr., Aaberg TM, Sr., Martin DF, et al. Three cases of large retinal capillary hemangiomas treated with verteporfin and photodynamic therapy. Arch Ophthalmol. 2005 Mar;123(3):328-32. PMID: 15767474; X-1

1932. Abe M, Misago N, Tanaka S, et al. Capillary hemangioma of the central nervous system: a comparative study with lobular capillary hemangioma of the skin. Acta Neuropathol. 2005 Feb;109(2):151-8. PMID: 15365728; X-1

1933. Agrawal S, Misra R, Aggarwal A. Angiomatous malformation: a rare cause of recurrent swelling of the knee joint. Indian Pediatr. 2005 Sep;42(9):937-9. PMID: 16208055; X-1

1934. Ali TZ, Beyer G, Taylor M, et al. Splenic hamartoma: immunohistochemical and ultrastructural profile of two cases. Int J Surg Pathol. 2005 Jan;13(1):103-11. PMID: 15735864; X-1

1935. Al-Mazrou KA, Richardson MA. Kasabach-Merritt phenomenon. Saudi Med J. 2005 Aug;26(8):1286-8. PMID: 16127531; X-1, X-2

1936. Antonoff MB, Kreykes NS, Saltzman DA, et al. American Academy of Pediatrics Section on Surgery hernia survey revisited. J Pediatr Surg. 2005 Jun;40(6):1009-14. PMID: 15991187; X-1

1937. Aziz A, Kane TD, Meza MP, et al. An unusual cause of rectal bleeding and intestinal obstruction in a child with peripheral vascular malformations. Pediatr Surg Int. 2005 Jun;21(6):491-3. PMID: 15806421; X-1

1938. Bakri SJ, Sears JE, Singh AD. Transient closure of a retinal capillary hemangioma with verteporfin photodynamic therapy. Retina. 2005 Dec;25(8):1103-4. PMID: 16340546; X-1

1939. Barrio VR, Drolet BA. Treatment of hemangiomas of infancy. Dermatol Ther. 2005 Mar-Apr;18(2):151-9. PMID: 15953144; X-1, X-2

1940. Bay A, Oner AF, Etlik O, et al. Unusual presentation of infantile hemangioendothelioma. Pediatr Blood Cancer. 2005 Mar;44(3):267-9. PMID: 15503295; X-1

1941. Bingul F, Tuncali D, Terzioglu A, et al. Hemangioma of the lower lip associated with schistosomiasis: a case report. Br J Plast Surg. 2005 Jul;58(5):736-7. PMID: 15992532; X-1, X-2

1942. Bitar MA, Moukarbel RV, Zalzal GH. Management of congenital subglottic hemangioma: trends and success over the past 17 years. Otolaryngol Head Neck Surg. 2005 Feb;132(2):226-31. PMID: 15692531; X-2

1943. Bolde SA, Shete SS, Dantkale SS, et al. Kasabach-Merritt syndrome: a case report. Indian J Pathol Microbiol. 2005 Jan;48(1):27-9. PMID: 16758782; X-1

1944. Borsaru AD, Naidoo P. Pyogenic abscess complicating a resolving cerebral haematoma secondary to a cavernous haemangioma: computed tomography and magnetic resonance imaging findings. Australas Radiol. 2005 Apr;49(2):144-50. PMID: 15845053; X-1

1945. Brotchi J, Baleriaux D, Kalangu KK, et al. Capillary hemangioma in the superior sagittal sinus as a rare cause of intracranial hypertension in a child: case report. Neurosurgery. 2005 Oct;57(4):E815. PMID: 17152670; X-1, X-2

1946. Bryan Y, Chwals W, Ovassapian A. Sedation and fiberoptic intubation of a neonate with a cystic hygroma. Acta Anaesthesiol Scand. 2005 Jan;49(1):122-3. PMID: 15675998; X-1

1947. Cai J, Hoff GL, Dew PC, et al. Perinatal periods of risk: analysis of fetal-infant mortality rates in Kansas City, Missouri. Matern Child Health J. 2005 Jun;9(2):199-205. PMID: 15965626; X-1

1948. Caroli E, Salvati M, Roperto R, et al. High-dose radiation-induced meningioma in children - case report and critical review of the literature. Zentralbl Neurochir. 2005 Feb;66(1):39-42. PMID: 15744628; X-1

1949. Ceballos C, Ramundo JM. Management of infants with ulcerated hemangiomas. J Wound Ostomy Continence Nurs. 2005 Jan-Feb;32(1):58-61; discussion -3. PMID: 15718959; X-2

1950. Chan KL, Hui WC, Tam PK. Prospective randomized single-center, single-blind comparison of laparoscopic vs open repair of pediatric inguinal hernia. Surg Endosc. 2005 Jul;19(7):927-32. PMID: 15920685; X-1

1951. Chapas AM, Geronemus RG. Our approach to pediatric dermatologic laser surgery. Lasers Surg Med. 2005 Oct;37(4):255-63. PMID: 16245293; X-1, X-2

1952. Chew EY. Ocular manifestations of von Hippel-Lindau disease: clinical and genetic investigations. Trans Am Ophthalmol Soc. 2005;103:495-511. PMID: 17057815; X-1

1953. Chou SY, Chiang HK, Chow PK, et al. Fetal hepatic hemangioma diagnosed prenatally with ultrasonography. Acta Obstet Gynecol Scand. 2005 Mar;84(3):301-2. PMID: 15715543; X-1, X-2

1954. Chrzanowski DS, Powers CN, Reiter ER. Parapharyngeal space hemangioma in a pediatric patient. Otolaryngol Head Neck Surg. 2005 Sep;133(3):455-7. PMID: 16143201; X-1, X-2

1955. Chuang CC, Lin HC, Huang CW. Submandibular cavernous hemangiomas with multiple phleboliths masquerading as sialolithiasis. J Chin Med Assoc. 2005 Sep;68(9):441-3. PMID: 16187603; X-1

1956. Coffin CM. USCAP Specialty Conference: case 3. Pediatr Dev Pathol. 2005 Jan-Feb;8(1):74-6. PMID: 15702365; X-1

1957. Colella G, Vuolo G, Siniscalchi G, et al. Radiotherapy for maxillo-facial hemangiomas in children. Dental and periodontal long term effects. Minerva Stomatol. 2005 Sep;54(9):509-16. PMID: 16215535; X-1, X-2

1958. Comi AM, Mehta P, Hatfield LA, et al. Sturge-Weber syndrome associated with other abnormalities: a medical record and literature review. Arch Neurol. 2005 Dec;62(12):1924-7. PMID: 16344352; X-1

1959. de Lange DH, Aufenacker TJ, Roest M, et al. Inguinal hernia surgery in The Netherlands: a baseline study before the introduction of the Dutch Guidelines. Hernia. 2005 May;9(2):172-7. PMID: 15723152; X-1

1960. Dourmishev LA, Dourmishev AL. Craniofacial cavernous hemangioma: succesful treatment with methylprednisolone. Acta Dermatovenerol Alp Pannonica Adriat. 2005 Jun;14(2):49-52. PMID: 16001100; X-1

1961. Duhem R, Vinchon M, Leblond P, et al. Cavernous malformations after cerebral irradiation during childhood: report of nine cases. Childs Nerv Syst. 2005 Oct;21(10):922-5. PMID: 15662523; X-1

1962. Dusing SC, Rosenberg A, Hiemenz JR, et al. Gross and fine motor skills of children with Hurler syndrome (MPS-IH) post umbilical cord blood transplantation: a case series report. Pediatr Phys Ther. 2005 Winter;17(4):264-7. PMID: 16357681; X-1

1963. Egeli E, Oghan F, Alper M, et al. Unusual case of laryngeal tumor (capillary hemangioma) obturating the larynx. Ann Otolaryngol Chir Cervicofac. 2005 Jun;122(3):154-6. PMID: 16142096; X-2

1964. Eggers G, Flechtenmacher C, Kurzen H, et al. Infiltrating basal cell carcinoma of the neck 34 years after irradiation of an haemangioma in early childhood. A case-report. J Craniomaxillofac Surg. 2005 Jun;33(3):197-200. PMID: 15878521; X-1, X-2

1965. El-Watidy S. Bifrontal decompressive craniotomy in a 6-month-old infant with posttraumatic refractory intracranial hypertension. Pediatr Neurosurg. 2005 May-Jun;41(3):151-4. PMID: 15995334; X-1

1966. Erkek E, Hizel S, Sanly C, et al. Clinical and histopathological findings in Bannayan-Riley-Ruvalcaba syndrome. J Am Acad Dermatol. 2005 Oct;53(4):639-43. PMID: 16198785; X-1

1967. Ersoy S, Mancini AJ. Hemifacial infantile hemangioma with intracranial extension: a rare entity. Pediatr Dermatol. 2005 Jul-Aug;22(4):309-13. PMID: 16060865; X-2

1968. Ferroli P, Sinisi M, Franzini A, et al. Brainstem cavernomas: long-term results of microsurgical resection in 52 patients. Neurosurgery. 2005 Jun;56(6):1203-12; discussion 12-4. PMID: 15918936; X-1

1969. Fishman SJ, Smithers CJ, Folkman J, et al. Blue rubber bleb nevus syndrome: surgical eradication of gastrointestinal bleeding. Ann Surg. 2005 Mar;241(3):523-8. PMID: 15729077; X-1

1970. Frider B, Bruno A, Selser J, et al. Kasabach-Merrit syndrome and adult hepatic epithelioid hemangioendothelioma an unusual association. J Hepatol. 2005 Feb;42(2):282-3. PMID: 15664259; X-1

1971. Frieden IJ, Haggstrom AN, Drolet BA, et al. Infantile hemangiomas: current knowledge, future directions. Proceedings of a research workshop on infantile hemangiomas, April 7-9, 2005, Bethesda, Maryland, USA. Pediatr Dermatol. 2005 Sep-Oct;22(5):383-406. PMID: 16190987; X-1, X-2

1972. Friedlander SF, Ritter MR, Friedlander M. Recent progress in our understanding of the pathogenesis of infantile hemangiomas. Lymphat Res Biol. 2005;3(4):219-25. PMID: 16379591; X-1

1973. Furuse M, Miyatake SI, Kuroiwa T. Cavernous malformation after radiation therapy for astrocytoma in adult patients: report of 2 cases. Acta Neurochir (Wien). 2005 Oct;147(10):1097-101; discussion 101. PMID: 16021386; X-1

1974. Good WV. Periorbital haemangiomas. Br J Ophthalmol. 2005 Sep;89(9):1074-5. PMID: 16113350; X-2

1975. Gruman A, Liang MG, Mulliken JB, et al. Kaposiform hemangioendothelioma without Kasabach-Merritt phenomenon. J Am Acad Dermatol. 2005 Apr;52(4):616-22. PMID: 15793511; X-1

1976. Guthrie SO, Rhodes M, Janco R, et al. An infant with Kasabach-Merritt syndrome with associated renal hematoma and intussusception. J Perinatol. 2005 Feb;25(2):143-5. PMID: 15660105; X-1, X-2

1977. Guven A, Aygun C, Ince H, et al. Severe hypothyroidism caused by hepatic hemangioendothelioma in an infant of a diabetic mother. Horm Res. 2005;63(2):86-9. PMID: 15711094; X-1

1978. Hamlat A, Adn M, Pasqualini E, et al. Pathophysiology of capillary haemangioma growth after birth. Med Hypotheses. 2005;64(6):1093-6. PMID: 15823691; X-1

1979. Hazen PG, Carney JF, Engstrom CW, et al. Proliferating hemangioma of infancy: successful treatment with topical 5% imiquimod cream. Pediatr Dermatol. 2005 May-Jun;22(3):254-6. PMID: 15916578; X-2

1980. Hernandez F, Navarro M, Encinas JL, et al. The role of GLUT1 immunostaining in the diagnosis and classification of liver vascular tumors in children. J Pediatr Surg. 2005 May;40(5):801-4. PMID: 15937818; X-1

1981. Hibi M, Tokiwa K, Fukata R, et al. Obstructive jaundice in a child with pancreatic hemangioma. Pediatr Surg Int. 2005 Sep;21(9):752-4. PMID: 16047179; X-1, X-2

1982. Ho J, Kendrick V, Dewey D, et al. New insight into the pathophysiology of severe hypothyroidism in an infant with multiple hepatic hemangiomas. J Pediatr Endocrinol Metab. 2005 May;18(5):511-4. PMID: 15921182; X-1, X-2

1983. Hochman M, Mascareno A. Management of nasal hemangiomas. Arch Facial Plast Surg. 2005 Sep-Oct;7(5):295-300. PMID: 16172336; X-1, X-2

1984. Holmberg E, Anderson H, Lundell M, et al. The impact of reproductive factors on breast cancer risk--the feasibility of using Swedish population-based registers to account for the effect of confounding in cohort studies. Cancer Causes Control. 2005 Apr;16(3):235-43. PMID: 15947875; X-1

1985. Hsiao CC, Chen CC, Ko SF, et al. A case of axillary kaposiform hemangioendothelioma resembles a soft tissue sarcoma. J Pediatr Hematol Oncol. 2005 Nov;27(11):596-8. PMID: 16282890; X-1

1986. Huiskamp EA, Muskens RP, Ballast A, et al. Diffuse choroidal haemangioma in Sturge-Weber syndrome treated with photodynamic therapy under general anaesthesia. Graefes Arch Clin Exp Ophthalmol. 2005 Jul;243(7):727-30. PMID: 15702328; X-1

1987. Hurvitz KA, Rosen H, Meara JG. Pediatric cervicofacial tissue expansion. Int J Pediatr Otorhinolaryngol. 2005 Nov;69(11):1509-13. PMID: 15908016; X-1

1988. Iannelli A, Lupi G, Castagna M, et al. Intramedullary capillary hemangioma associated with hydrocephalus in an infant. J Neurosurg. 2005 Sep;103(3 Suppl):272-6. PMID: 16238083; X-1, X-2

1989. Ioannidis AS, Liasis A, Syed S, et al. The value of visual evoked potentials in the evaluation of periorbital hemangiomas. Am J Ophthalmol. 2005 Aug;140(2):314-6. PMID: 16086956; X-2

1990. Islam S, Newman EA, Strouse PJ, et al. Antiangiogenic therapy for a large splenic hemangioma. Pediatr Surg Int. 2005 Dec;21(12):1007-10. PMID: 16215767; X-2

1991. Jian XC. Surgical management of lymphangiomatous or lymphangiohemangiomatous macroglossia. J Oral Maxillofac Surg. 2005 Jan;63(1):15-9. PMID: 15635551; X-1

1992. Jiang XW, Wang GH, Li JH, et al. Expression of glucocorticoid receptor isoforms in cutaneous hemangiomas and vascular malformations. Chin Med J (Engl). 2005 Jun 20;118(12):977-81. PMID: 15978204; X-1, X-3

1993. Jianhong L, Xianliang H, Xuewu J. Transcatheter arterial embolization in the treatment of extensive maxillofacial hemangioma in children. World J Surg. 2005 Dec;29(12):1550-6. PMID: 16317485; X-1

1994. Johann AC, Aguiar MC, do Carmo MA, et al. Sclerotherapy of benign oral vascular lesion with ethanolamine oleate: an open clinical trial with 30 lesions. Oral Surg Oral Med Oral Pathol Oral Radiol Endod. 2005 Nov;100(5):579-84. PMID: 16243243; X-1

1995. Kapoor S, Pal S, Chattopadhyay TK. Giant hemangioma of the liver presenting with abdominal compartment syndrome: A case report. Eur Surg. 2005 February;37(1):52-4. PMID: 2005159028; X-1

1996. Katori H, Tsukuda M. Lobular capillary hemangioma of the nasal cavity in child. Auris Nasus Larynx. 2005 Jun;32(2):185-8. PMID: 15917177; X-2

1997. Kelley TM, Hatfield LA, Lin DD, et al. Quantitative analysis of cerebral cortical atrophy and correlation with clinical severity in unilateral Sturge-Weber syndrome. J Child Neurol. 2005 Nov;20(11):867-70. PMID: 16417855; X-1

1998. Kilickesmez O, Sanal HT, Haholu A, et al. Coexistence of pleomorphic xanthoastrocytoma with Sturge-Weber syndrome: MRI features. Pediatr Radiol. 2005 Sep;35(9):910-3. PMID: 15883827; X-1

1999. Kim MS, Pyo SY, Jeong YG, et al. Gamma knife surgery for intracranial cavernous hemangioma. J Neurosurg. 2005 Jan;102 Suppl:102-6. PMID: 15662789; X-1

2000. Kitagawa Y, Ito H, Iketani M, et al. Epithelioid hemangioendothelioma of the phalanx: a case report. J Hand Surg Am. 2005 May;30(3):615-9. PMID: 15925176; X-1

2001. Koch BL. The child with a neck mass. Appl Radiol. 2005;34(8):8-, 10-4, 6-8 passim. PMID: X-1

2002. Kondo M, Suzuki K, Inoue R, et al. Characterization of T-cell clones specific to ovomucoid from patients with egg-white allergy. J Investig Allergol Clin Immunol. 2005;15(2):107-11. PMID: 16047710; X-1

2003. Kordic R, Sabol Z, Cerovski B, et al. Eye disorders in neurofibromatosis (NF1). Coll Antropol. 2005;29 Suppl 1:29-31. PMID: 16193672; X-1

2004. Kossoff EH, Hatfield LA, Ball KL, et al. Comorbidity of epilepsy and headache in patients with Sturge-Weber syndrome. J Child Neurol. 2005 Aug;20(8):678-82. PMID: 16225815; X-1

2005. Koulouris G, Rao P. Multiple congenital cranial hemangiomas. Skeletal Radiol. 2005 Aug;34(8):485-9. PMID: 15723210; X-1

2006. Kronenberg A, Blei F, Ceisler E, et al. Ocular and systemic manifestations of PHACES (Posterior fossa malformations, Hemangiomas, Arterial anomalies, Cardiac defects and coarctation of the Aorta, Eye abnormalities, and Sternal abnormalities or ventral developmental defects) syndrome. J aapos. 2005 Apr;9(2):169-73. PMID: 15838446; X-3, X-4

2007. Lawley LP, Cerimele F, Weiss SW, et al. Expression of Wilms tumor 1 gene distinguishes vascular malformations from proliferative endothelial lesions. Arch Dermatol. 2005 Oct;141(10):1297-300. PMID: 16230568; X-1

2008. Lee CW, Choi DY, Oh YG, et al. An infantile case of Sturge-Weber syndrome in association with Klippel-Trenaunay-Weber syndrome and phakomatosis pigmentovascularis. J Korean Med Sci. 2005 Dec;20(6):1082-4. PMID: 16361829; X-1

2009. Lehnhardt FG, von Smekal U, Ruckriem B, et al. Value of gradient-echo magnetic resonance imaging in the diagnosis of familial cerebral cavernous malformation. Arch Neurol. 2005 Apr;62(4):653-8. PMID: 15824268; X-1

2010. Liu AL, Wang C, Sun S, et al. Gamma knife radiosurgery for tumors involving the cavernous sinus. Stereotact Funct Neurosurg. 2005;83(1):45-51. PMID: 15860936; X-1

2011. Lok C, Viseux V, Avril MF, et al. Brain magnetic resonance imaging in patients with Cowden syndrome. Medicine (Baltimore). 2005 Mar;84(2):129-36. PMID: 15758842; X-1

2012. Lopez-Gutierrez JC, Diaz M, Ros Z. Giant rapidly involuting congenital hemangioma of the face: 15-year follow-up. Arch Facial Plast Surg. 2005 Sep-Oct;7(5):316-8. PMID: 16172340; X-1

2013. Mackie AS, Kozakewich HP, Geva T, et al. Vascular tumors of the heart in infants and children: case series and review of the literature. Pediatr Cardiol. 2005 Jul-Aug;26(4):344-9. PMID: 15549621; X-1, X-2

2014. Marler JJ, Fishman SJ, Kilroy SM, et al. Increased expression of urinary matrix metalloproteinases parallels the extent and activity of vascular anomalies. Pediatrics. 2005 Jul;116(1):38-45. PMID: 15995028; X-1, X-3

2015. Matulich J, Wood G, Sugo E. Case of non-involuting congenital haemangioma. Australas J Dermatol. 2005 Aug;46(3):165-8. PMID: 16008648; X-1

2016. Mentzel HJ, Dieckmann A, Fitzek C, et al. Early diagnosis of cerebral involvement in Sturge-Weber syndrome using high-resolution BOLD MR venography. Pediatr Radiol. 2005 Jan;35(1):85-90. PMID: 15480615; X-1

2017. Messieha ZS, Ananda RC, Hoffman WE, et al. Bispectral index system (BIS) monitoring reduces time to extubation and discharge in children requiring oral presedation and general anesthesia for outpatient dental rehabilitation. Pediatr Dent. 2005 Nov-Dec;27(6):500-4. PMID: 16532892; X-1

2018. Miller MA, Sandler AD. Elevated plasma vascular endothelial growth factor levels in 2 patients with hemangioendothelioma. J Pediatr Surg. 2005 May;40(5):e17-9. PMID: 15937808; X-1

2019. Morel KD, Hogeling M, Eichenfield LF. More than skin deep: cutaneous signs of systemic disease. Contemp Pediatr. 2005;22(2):48-56. PMID: X-2

2020. Muraoka M, Motomura H, Hayashi I, et al. Two cases of tumor-forming strawberry mark hemangioma of the upper lip which caught surgical treatment. Medical Journal of Minami Osaka Hospital. 2005 September;53(1):47-53. PMID: 2005563049; X-1, X-2

2021. Murthy R, Hanovaz SG, Naik M, et al. Ruthenium-106 plaque brachytherapy for the treatment of diffuse choroidal haemangioma in Sturge-Weber syndrome. Indian J Ophthalmol. 2005 Dec;53(4):274-5. PMID: 16333180; X-1, X-2

2022. Muzaffar F. Clinical profile and morphologic types of infantile hemangioma. A study of 252 children. Journal of Pakistan Association of Dermatologists. 2005;15(2):119-24. PMID: 2006474804; X-3, X-4

2023. Omidvari S, Nezakatgoo N, Ahmadloo N, et al. Role of intralesional bleomycin in the treatment of complicated hemangiomas: prospective clinical study. Dermatol Surg. 2005 May;31(5):499-501. PMID: 15962730; X-3

2024. Pai I, Hegde V, Wilson PO, et al. Ectopic thymus presenting as a subglottic mass: diagnostic and management dilemmas. Int J Pediatr Otorhinolaryngol. 2005 Apr;69(4):573-6. PMID: 15763300; X-1

2025. Pallua N, von Heimburg D. Pre-expanded ultra-thin supraclavicular flaps for (full-) face reconstruction with reduced donor-site morbidity and without the need for microsurgery. Plast Reconstr Surg. 2005 Jun;115(7):1837-44; discussion 45-7. PMID: 15923825; X-1

2026. Park YH, Choi JY, Chung HS, et al. Hematuria and proteinuria in a mass school urine screening test. Pediatr Nephrol. 2005 Aug;20(8):1126-30. PMID: 15947990; X-1

2027. Pascual-Castroviejo I, Pascual-Pascual SI, Garcia-Guereta L, et al. Cutaneous thoracic hemangioma and internal vascular anomalies. J Pediatr Neurol. 2005;3(2):103-6. PMID: 2006563763; X-2

2028. Patrizi A, Varotti E, Parlangeli A, et al. Acquired tufted angioma of the thigh in an adult. [Italian, English]

Angioma tufted acquisito dell'adulto. G Ital Dermatol Venereol. 2005;140(2):149-54. PMID: 2006301608; X-1

2029. Peng Q, Liu W, Tang Y, et al. The establishment of the hemangioma model in nude mouse. J Pediatr Surg. 2005 Jul;40(7):1167-72. PMID: 16034764; X-1

2030. Perez DE, Pereira Neto JS, Graner E, et al. Sturge-Weber syndrome in a 6-year-old girl. Int J Paediatr Dent. 2005 Mar;15(2):131-5. PMID: 15790372; X-1

2031. Piraccini BM, Antonucci A, Rech G, et al. Congenital pseudoclubbing of a fingernail caused by subungual hemangioma. J Am Acad Dermatol. 2005 Aug;53(2 Suppl 1):S123-6. PMID: 16021160; X-1, X-2

2032. Polito E, Burroni L, Pichierri P, et al. Technetium tc 99m-labeled red blood cells in the preoperative diagnosis of cavernous hemangioma and other vascular orbital tumors. Arch Ophthalmol. 2005 Dec;123(12):1678-83. PMID: 16344439; X-1

2033. Posner JC, Spandorfer PR. Early detection of imperforate hymen prevents morbidity from delays in diagnosis. Pediatrics. 2005 Apr;115(4):1008-12. PMID: 15805378; X-1

2034. Prasad KC, Karthik S, Prasad SC. A comprehensive study on lesions of the pinna. Am J Otolaryngol. 2005 Jan-Feb;26(1):1-6. PMID: 15635573; X-3, X-4

2035. Premalata CS, Kumar RV, Appaji L, et al. Childhood hepatic angiosarcoma--a case report. Indian J Pathol Microbiol. 2005 Oct;48(4):487-9. PMID: 16366104; X-1

2036. Puvabanditsin S, Garrow E, Mehta D, et al. Large chorioangioma associated with hydrops fetalis: a case report. Neonatal Intensive Care. 2005 2005 Jan-Feb;18(1):15-7. PMID: X-1

2037. Raghu AR, Tandon S, Rao NN, et al. Intraoral papillary endothelial hyperplasia: case discussion with supportive histochemistry and immunohistochemistry. J Clin Pediatr Dent. 2005 Spring;29(3):253-7. PMID: 15926444; X-1

2038. Reck SD, Zacks DN, Eibschitz-Tsimhoni M. Retinal and intracranial arteriovenous malformations: Wyburn-Mason syndrome. J Neuroophthalmol. 2005 Sep;25(3):205-8. PMID: 16148629; X-1

2039. Reis RM, Reis-Filho JS, Longatto Filho A, et al. Differential Prox-1 and CD 31 expression in mucousae, cutaneous and soft tissue vascular lesions and tumors. Pathol Res Pract. 2005;201(12):771-6. PMID: 16308102; X-1

2040. Rohde V, Spangenberg P, Mayfrank L, et al. Advanced neuronavigation in skull base tumors and vascular lesions. Minim Invasive Neurosurg. 2005 Feb;48(1):13-8. PMID: 15747211; X-1

2041. Roman KS, Somers GR, Jaeggi ET. Prenatal presentation of an intracardiac infantile type of haemangioendothelioma. Cardiol Young. 2005 Apr;15(2):182-3. PMID: 15845162; X-1

2042. Ross G, Bekhor P, Su J, et al. A case of PHACE syndrome. Australas J Dermatol. 2005 Nov;46(4):253-6. PMID: 16197426; X-2

2043. Sabharwal GK, Strouse PJ. Posterior mediastinal hemangioma. Pediatr Radiol. 2005 Dec;35(12):1263-6. PMID: 16163502; X-1, X-2

2044. Sandalcioglu IE, Gasser T, Asgari S, et al. Functional outcome after surgical treatment of intramedullary spinal cord tumors: experience with 78 patients. Spinal Cord. 2005 Jan;43(1):34-41. PMID: 15326473; X-1

2045. Sasaoka N, Kawaguchi M, Yoshitani K, et al. Evaluation of genitofemoral nerve block, in addition to ilioinguinal and iliohypogastric nerve block, during inguinal hernia repair in children. Br J Anaesth. 2005 Feb;94(2):243-6. PMID: 15567812; X-1

2046. Schmidt D, Neumann HP. Spontaneous regression of retinal angiomatous lesions in v. Hippel-Lindau disease (VHL). Eur J Med Res. 2005 Dec 7;10(12):532-4. PMID: 16356869; X-1

2047. Shaul DB, Monforte HL, Levitt MA, et al. Surgical management of perineal masses in patients with anorectal malformations. J Pediatr Surg. 2005 Jan;40(1):188-91. PMID: 15868583; X-3, X-4

2048. Shih YH, Pan DH. Management of supratentorial cavernous malformations: craniotomy versus gammaknife radiosurgery. Clin Neurol Neurosurg. 2005 Feb;107(2):108-12. PMID: 15708224; X-1

2049. Simon SL, Moonis G, Judkins AR, et al. Intracranial capillary hemangioma: case report and review of the literature. Surg Neurol. 2005 Aug;64(2):154-9. PMID: 16051010; X-1

2050. Sullivan JG, Gohel M, Kinder RB. Ectopic adrenocortical tissue found at groin exploration in children: incidence in relation to diagnosis, age and sex. BJU Int. 2005 Feb;95(3):407-10. PMID: 15679804; X-1

2051. Szymik-Kantorowicz S, Kobylarz K, Krysta M, et al. Interferon-alpha in the treatment of high-risk haemangiomas in infants. Eur J Pediatr Surg. 2005 Feb;15(1):11-6. PMID: 15795821; X-4

2052. Taddeucci G, Bonuccelli A, Polacco P. Migraine-like attacks in child with Sturge-Weber syndrome without facial nevus. Pediatr Neurol. 2005 Feb;32(2):131-3. PMID: 15664776; X-1

2053. Takahashi A, Ogawa C, Kanazawa T, et al. Remission induced by interferon alfa in a patient with massive osteolysis and extension of lymph-hemangiomatosis: a severe case of Gorham-Stout syndrome. J Pediatr Surg. 2005 Mar;40(3):E47-50. PMID: 15793714; X-1, X-2

2054. Tansel T, Aydogan U, Yilmazbayhan D, et al. Epitheloid hemangioendothelioma of the heart in infancy. Ann Thorac Surg. 2005 Apr;79(4):1402-5. PMID: 15797093; X-1

2055. Tatli M, Guzel A, Keklikci U, et al. Pediatric orbital multifocal cavernous hemangiomas associated with bilateral arachnoid cysts of the middle cranial fossa. Case report and review of the literature. J Neurosurg. 2005 Nov;103(5 Suppl):454-7. PMID: 16302620; X-1

2056. Thomas RF, Hornung RL, Manning SC, et al. Hemangiomas of infancy: treatment of ulceration in the head and neck. Arch Facial Plast Surg. 2005 Sep-Oct;7(5):312-5. PMID: 16172339; X-2

2057. Trager JD. What's your diagnosis? A 3-month-old girl with an ulcerated perineal plaque. J Pediatr Adolesc Gynecol. 2005 Dec;18(6):409-13. PMID: 16338607; X-1

2058. Tu J, Stoodley MA, Morgan MK, et al. Ultrastructural characteristics of hemorrhagic, nonhemorrhagic, and recurrent cavernous malformations. J Neurosurg. 2005 Nov;103(5):903-9. PMID: 16304995; X-1

2059. Ulrich H, Baumler W, Hohenleutner U, et al. Neodymium-YAG Laser for hemangiomas and vascular malformations -- long term results. J Dtsch Dermatol Ges. 2005 Jun;3(6):436-40. PMID: 15892846; X-3, X-4

2060. Umehara F, Matsuura E, Kitajima S, et al. Unilateral toe-walking secondary to intramuscular hemangioma in the gastrocnemius. Neurology. 2005 Oct 11;65(7):E15. PMID: 16217043; X-1, X-2

2061. Upton A. Diffuse neonatal hemangiomatosis. Journal of Diagnostic Medical Sonography. 2005 July/August;21(4):350-3. PMID: 2005330954; X-1

2062. Verhelst H, Van Coster R. Neuroradiologic findings in a young patient with characteristics of Sturge-Weber syndrome and Klippel-Trenaunay syndrome. J Child Neurol. 2005 Nov;20(11):911-3. PMID: 16417862; X-1

2063. Woo CLF, Ho BHT, Young BWY. A newborn with ptosis secondary to a cavernous haemangioma. Hong Kong Journal of Paediatrics. 2005 July;10(3):211-3+8. PMID: 2005382991; X-1

2064. Yagmurlu B, Fitoz S, Atasoy C, et al. An unusual cause of hydrocephalus: aqueductal developmental venous anomaly. Eur Radiol. 2005 Jun;15(6):1159-62. PMID: 15150667; X-1

2065. Zhang L, Lin X, Wang W, et al. Circulating level of vascular endothelial growth factor in differentiating hemangioma from vascular malformation patients. Plast Reconstr Surg. 2005 Jul;116(1):200-4. PMID: 15988268; X-2

2066. Zur KB, Wood RE, Elluru RG. Pediatric postcricoid vascular malformation: a diagnostic and treatment challenge. Int J Pediatr Otorhinolaryngol. 2005 Dec;69(12):1697-701. PMID: 15961166; X-2

2067. Ada M, Guvenc MG, Yilmaz S. Infantile supraglottic hemangioma: a case report. Ear Nose Throat J. 2006 Jun;85(6):388-9, 91. PMID: 16866116; X-2

2068. Akil H, Statham PF, Gotz M, et al. Adult cerebellar mutism and cognitive-affective syndrome caused by cystic hemangioblastoma. Acta Neurochir (Wien). 2006 May;148(5):597-8. PMID: 16200477; X-1

2069. Al-Shahwan S, Khan AO. Buphthalmos following systemic steroid treatment. J Pediatr Ophthalmol Strabismus. 2006 Sep-Oct;43(5):311-2. PMID: 17022166; X-2

2070. Aoi Y, Kamiya Y, Shioda M, et al. Pre-anesthetic evaluation can play a crucial role in the determination of airway management in a child with oropharyngeal tumor. J Anesth. 2006;20(3):215-9. PMID: 16897242; X-1

2071. Ashworth JL, Biswas S, Wraith E, et al. The ocular features of the mucopolysaccharidoses. Eye (Lond). 2006 May;20(5):553-63. PMID: 15905869; X-1

2072. Audren F, Abitbol O, Dureau P, et al. Non-penetrating deep sclerectomy for glaucoma associated with Sturge-Weber syndrome. Acta Ophthalmol Scand. 2006 Oct;84(5):656-60. PMID: 16965497; X-1

2073. Awwad RJ, Mortelliti AJ. Postcricoid hemangioma of childhood: report of four cases. Ann Otol Rhinol Laryngol. 2006 Mar;115(3):191-4. PMID: 16572608; X-3, X-4

2074. Bajaj Y, Hartley BE, Wyatt ME, et al. Subglottic haemangioma in children: experience with open surgical excision. J Laryngol Otol. 2006 Dec;120(12):1033-7. PMID: 17052378; X-4

2075. Baradaranfar MH, Dabirmoghaddam P. Endoscopic endonasal surgery for resection of benign sinonasal tumors: experience with 105 patients. Arch Iran Med. 2006 Jul;9(3):244-9. PMID: 16859060; X-1

2076. Barankin B. A "red mark and bruising" on an infant's face. Contemp Pediatr. 2006;23(7):16-7. PMID: X-1

2077. Birchler MT, Schmid S, Holzmann D, et al. Kaposiform hemangioendothelioma arising in the ethmoid sinus of an 8-year-old girl with severe epistaxis. Head Neck. 2006 Aug;28(8):761-4. PMID: 16721737; X-1

2078. Broniscer A, Laningham FH, Kocak M, et al. Intratumoral hemorrhage among children with newly diagnosed, diffuse brainstem glioma. Cancer. 2006 Mar 15;106(6):1364-71. PMID: 16463390; X-1

2079. Brooker RW, Keenan WJ. Inguinal hernia: relationship to respiratory disease in prematurity. J Pediatr Surg. 2006 Nov;41(11):1818-21. PMID: 17101350; X-1

2080. Bruneau M, Bijlenga P, Reverdin A, et al. Early surgery for brainstem cavernomas. Acta Neurochir (Wien). 2006 Apr;148(4):405-14. PMID: 16311840; X-1

2081. Bucher S, Guerra M, Corrias F, et al. Basal cell carcinoma of the nose requiring amputation arising after irradiation for childhood hemangioma. Anticancer Res. 2006 Nov-Dec;26(6c):4767-70. PMID: 17214338; X-1, X-2

2082. Burstein FD, Williams JK, Schwentker AR, et al. Intralesional laser therapy treatment for hemangiomas: technical evolution. J Craniofac Surg. 2006 Jul;17(4):756-60. PMID: 16877930; X-1

2083. Cannady SB, Kahn TA, Traboulsi EI, et al. PHACE syndrome: report of a case with a glioma of the anterior skull base and ocular malformations. Int J Pediatr Otorhinolaryngol. 2006 Mar;70(3):561-4. PMID: 16144720; X-2

2084. Chi JH, Lawton MT. Posterior interhemispheric approach: surgical technique, application to vascular lesions, and benefits of gravity retraction. Neurosurgery. 2006 Jul;59(1 Suppl 1):ONS41-9; discussion ONS-9. PMID: 16888550; X-1

2085. Chiummariello S, Mezzana P, Fioramonti P, et al. The use of laser and Varioscope in the management of hemangiomas and vascular malformations. Acta Chir Plast. 2006;48(1):20-5. PMID: 16722347; X-1

2086. Cho SH, Na KS. Haemangioendothelioma on the conjunctiva of the upper eyelid. Clin Experiment Ophthalmol. 2006 Nov;34(8):794-6. PMID: 17073904; X-1

2087. Chopra A, Iyer VK, Thapar R, et al. Diffuse multifocal chorangiomatosis of the placenta with multiple intestinal stenosis of the fetus: combination of rare causes for nonimmune hydrops fetalis. Indian J Pathol Microbiol. 2006 Oct;49(4):600-2. PMID: 17183871; X-1

2088. Cong X. Kangaroo care for analgesia in preterm infants undergoing heel stick pain: Case Western Reserve University; 2006.

2089. Corapcioglu F, Akansel G, Gonullu E, et al. Fatal giant pediatric intracranial cavernous angioma. Turk J Pediatr. 2006 Jan-Mar;48(1):89-92. PMID: 16562795; X-1

2090. Dalen K, Bruaroy S, Wentzel-Larsen T, et al. Non-verbal learning disabilities in children with infantile hydrocephalus, aged 4-7 years: a population-based, controlled study. Neuropediatrics. 2006 Feb;37(1):1-5. PMID: 16541361; X-1

2091. D'Angelo VA, De Bonis C, Amoroso R, et al. Supratentorial cerebral cavernous malformations: clinical, surgical, and genetic involvement. Neurosurg Focus. 2006;21(1):e9. PMID: 16859262; X-1

2092. Davids T, Reid D. Capillary hemangioma of the middle ear. J Otolaryngol. 2006 Jun;35(3):196-9. PMID: 16929999; X-2

2093. de la Hunt MN. Kasabach-Merritt syndrome: dangers of interferon and successful treatment with pentoxifylline. J Pediatr Surg. 2006 Jan;41(1):e29-31. PMID: 16410085; X-1

2094. Delesalle F, Staumont D, Houmany MA, et al. Pulse methylprednisolone therapy for threatening periocular haemangiomas of infancy. Acta Derm Venereol. 2006;86(5):429-32. PMID: 16955189; X-4

2095. Delvi MB, Takrouri MS. Anesthesia for encephalo-trigeminal angiomatosis (Sturge-Weber syndrome). Middle East J Anesthesiol. 2006 Feb;18(4):785-90. PMID: 16749573; X-1

2096. Denier C, Labauge P, Bergametti F, et al. Genotype-phenotype correlations in cerebral cavernous malformations patients. Ann Neurol. 2006 Nov;60(5):550-6. PMID: 17041941; X-1

2097. Deraedt K, Vander Poorten V, Van Geet C, et al. Multifocal kaposiform haemangioendothelioma. Virchows Arch. 2006 Jun;448(6):843-6. PMID: 16596383; X-1

2098. Devalia KL, Mehta R, Yagnik MG. Benign juvenile hemangioma--a case report. Acta Orthop. 2006 Feb;77(1):171-3. PMID: 16534720; X-2

2099. Devesa PM, Sood S, Chaudhari M, et al. Masson's tumour: Differential diagnosis of neck lump in children. Int J Pediatr Otorhinolaryngol Extra. 2006 September;1(3):196-9. PMID: 2006409560; X-1

2100. Downey-Carmona FJ, Gonzalez-Herranz P, De La Fuente-Gonzalez C, et al. Acute compartment syndrome of the foot caused by a hemangioma. J Foot Ankle Surg. 2006 Jan-Feb;45(1):52-5. PMID: 16399561; X-1

2101. Drolet BA, Dohil M, Golomb MR, et al. Early stroke and cerebral vasculopathy in children with facial hemangiomas and PHACE association. Pediatrics. 2006 Mar;117(3):959-64. PMID: 16510684; X-3, X-4

2102. Drosou A, Benjamin L, Linfante I, et al. Infantile midline facial hemangioma with agenesis of the corpus callosum and sinus pericranii: another face of the PHACE syndrome. J Am Acad Dermatol. 2006 Feb;54(2):348-52. PMID: 16443074; X-2

2103. Dubois J, Milot J, Jaeger BI, et al. Orbit and eyelid hemangiomas: is there a relationship between location and ocular problems? J Am Acad Dermatol. 2006 Oct;55(4):614-9. PMID: 17010740; X-3, X-4

2104. Durusoy C, Mihci E, Tacoy S, et al. PHACES syndrome presenting as hemangiomas, sternal clefting and congenital ulcerations on the helices. J Dermatol. 2006 Mar;33(3):219-22. PMID: 16620231; X-2

2105. Eckardt A, Swennen G, Barth EL, et al. Long-term results after mandibular continuity resection in infancy: the role of autogenous rib grafts for mandibular restoration. J Craniofac Surg. 2006 Mar;17(2):255-60. PMID: 16633171; X-1

2106. Farrokhi MR, Aghamajidi J. Surgical treatment of occult spinal dysraphism with tethered spinal cord. Pan Arab Journal of Neurosurgery. 2006 October;10(2):13-6. PMID: 2006588910; X-1

2107. Friedlich P, Shin CE, Seri I. Cardiovascular compromise in the surgical neonate. Seminars in Anesthesia, Perioperative Medicine & Pain. 2006;25(3):124-35. PMID: X-1

2108. Ghidini A, Locatelli A. Diffuse placental chorioangiomatosis causing multiple fetal cerebral embolism: a case report. J Reprod Med. 2006 Apr;51(4):321-4. PMID: 16737029; X-1

2109. Girn HR, Towns G, Chumas P, et al. Gorham's disease of skull base and cervical spine--confusing picture in a two year old. Acta Neurochir (Wien). 2006 Aug;148(8):909-13; discussion 13. PMID: 16791440; X-1

2110. Goddard DS, Liang MG, Chamlin SL, et al. Hypopituitarism in PHACES Association. Pediatr Dermatol. 2006 Sep-Oct;23(5):476-80. PMID: 17014646; X-2

2111. Gold R, O'Keefe M, Langer P. Management of capillary hemangiomas. J Pediatr Ophthalmol Strabismus. 2006 Nov-Dec;43(6):326-30. PMID: 17162966; X-2

2112. Gottschling S, Schneider G, Meyer S, et al. Two infants with life-threatening diffuse neonatal hemangiomatosis treated with cyclophosphamide. Pediatr Blood Cancer. 2006 Feb;46(2):239-42. PMID: 16369922; X-1

2113. Haggstrom AN, Drolet BA, Baselga E, et al. Prospective study of infantile hemangiomas: clinical characteristics predicting complications and treatment. Pediatrics. 2006 Sep;118(3):882-7. PMID: 16950977; X-3, X-4

2114. Haggstrom AN, Lammer EJ, Schneider RA, et al. Patterns of infantile hemangiomas: new clues to hemangioma pathogenesis and embryonic facial development. Pediatrics. 2006 Mar;117(3):698-703. PMID: 16510649; X-1, X-3

2115. Hansen SL, Dosanjh A, Young DM, et al. Hemangiomas and homeobox gene expression. J Craniofac Surg. 2006 Jul;17(4):767-71. PMID: 16877932; X-1

2116. Haroon N, Aggarwal A, Landis MS, et al. What's your call? Cmaj. 2006;175(9):1059-61. PMID: X-1

2117. Harper L, Michel JL, Enjolras O, et al. Successful management of a retroperitoneal kaposiform hemangioendothelioma with Kasabach-Merritt phenomenon using alpha-interferon. Eur J Pediatr Surg. 2006 Oct;16(5):369-72. PMID: 17160787; X-1, X-2

2118. Ishihara H, Bjeljac M, Straumann D, et al. The role of intraoperative monitoring of oculomotor and trochlear nuclei -safe entry zone to tegmental lesions. Minim Invasive Neurosurg. 2006 Jun;49(3):168-72. PMID: 16921458; X-1

2119. Iwami D, Shimaoka S, Mochizuki I, et al. Kaposiform hemangioendothelioma of the mediastinum in a 7-month-old boy: a case report. J Pediatr Surg. 2006 Aug;41(8):1486-8. PMID: 16863862; X-1

2120. Iyoob SD, Tsai A, Ruchelli ED, et al. Large umbilical cord hemangioma: sonographic features with surgical pathologic correlation. J Ultrasound Med. 2006 Nov;25(11):1495-8. PMID: 17060442; X-1

2121. Jallo GI, Freed D, Zareck M, et al. Clinical presentation and optimal management for intramedullary cavernous malformations. Neurosurg Focus. 2006;21(1):e10. PMID: 16859248; X-1

2122. Jeon YS, Cho SG, Kim WH, et al. Cavernous haemangioma of the spermatic cord in a child. Pediatr Radiol. 2006 Dec;36(12):1323-5. PMID: 17031632; X-1

2123. Jothilakshmi K, Matthai J, Paul S, et al. Symptomatic hepatic hemangioendothelioma in a newborn. Indian Pediatr. 2006 Oct;43(10):908-10. PMID: 17079836; X-1

2124. Karikari IO, Selznick LA, Cummings TJ, et al. Capillary hemangioma of the fourth ventricle in an infant. Case report and review of the literature. J Neurosurg. 2006 Mar;104(3 Suppl):188-91. PMID: 16572636; X-2

2125. Kavanagh EC, Heran MK, Peleg A, et al. Imaging of the natural history of an orbital capillary hemangioma. Orbit. 2006 Mar;25(1):69-72. PMID: 16527782; X-2

2126. Kavin H, Berman J, Martin TL, et al. Successful wireless capsule endoscopy for a 2.5-year-old child: obscure gastrointestinal bleeding from mixed, juvenile, capillary hemangioma-angiomatosis of the jejunum. Pediatrics. 2006 Feb;117(2):539-43. PMID: 16452379; X-1, X-2

2127. Keskin M, Kelly CP, Yavuzer R, et al. External filling ports in tissue expansion: confirming their safety and convenience. Plast Reconstr Surg. 2006 Apr 15;117(5):1543-51. PMID: 16641723; X-1

2128. Khan ZA, Melero-Martin JM, Wu X, et al. Endothelial progenitor cells from infantile hemangioma and umbilical cord blood display unique cellular responses to endostatin. Blood. 2006 Aug 1;108(3):915-21. PMID: 16861344; X-1

2129. Kim JM, Cheong JH, Bak KH, et al. Congenital supratentorial hemangioblastoma as an unusual cause of simultaneous supra- and infratentorial intracranial hemorrhage: case report. J Neurooncol. 2006 Mar;77(1):59-63. PMID: 16132529; X-1

2130. Kreusel KM, Bechrakis NE, Neumann HP, et al. Pars plana vitrectomy for juxtapapillary capillary retinal angioma. Am J Ophthalmol. 2006 Mar;141(3):587-9. PMID: 16490522; X-1, X-2

2131. Kumar GS, Poonnoose SI, Chacko AG, et al. Trigonal cavernous angiomas: report of three cases and review of literature. Surg Neurol. 2006 Apr;65(4):367-71, discussion 71. PMID: 16531197; X-1

2132. Kutay V, Yakut C, Ekim H. Mitral annular tumors: report of two cases in childhood. J Card Surg. 2006 Mar-Apr;21(2):191-4. PMID: 16492286; X-1, X-2

2133. Laga S, Gewillig MH, Van Schoubroeck D, et al. Imminent fetal cardiac tamponade by right atrial hemangioma. Pediatr Cardiol. 2006 Sep-Oct;27(5):633-5. PMID: 16944336; X-1

2134. Lantuejoul S, Sheppard MN, Corrin B, et al. Pulmonary veno-occlusive disease and pulmonary capillary hemangiomatosis: a clinicopathologic study of 35 cases. Am J Surg Pathol. 2006 Jul;30(7):850-7. PMID: 16819327; X-1

2135. Lee E, Billings SD, Roumpf S, et al. Abdominal plaque in a 10-day-old boy. Arch Dermatol. 2006 May;142(5):641-6. PMID: 16702506; X-1

2136. Lee TC, Barshes NR, Agee EE, et al. Resolution of medically resistant hypothyroidism after liver transplantation for hepatic hemangioendothelioma. J Pediatr Surg. 2006 Oct;41(10):1783-5. PMID: 17011291; X-1

2137. Lerner A, Gilboa Y, Gerad L, et al. Sonographic detection of fetal cerebellar cavernous hemangioma with in-utero hemorrhage leading to cerebellar hemihypoplasia. Ultrasound Obstet Gynecol. 2006 Dec;28(7):968-71. PMID: 17121422; X-1

2138. Lew SM, Morgan JN, Psaty E, et al. Cumulative incidence of radiation-induced cavernomas in long-term survivors of medulloblastoma. J Neurosurg. 2006 Feb;104(2 Suppl):103-7. PMID: 16506497; X-1

2139. Li JH, Xin YL, Zhang W, et al. Effect of electro-acupuncture in treating patients with lingual hemangioma. Chin J Integr Med. 2006 Jun;12(2):146-9. PMID: 16800996; X-1

2140. Lim HG, Lee JR, Min SK, et al. Aortobrachial bypass for acute vascular insufficiency due to tumor embolization. Eur J Cardiothorac Surg. 2006 Apr;29(4):609. PMID: 16473515; X-1, X-2

2141. Lin DD, Gailloud P, McCarthy EF, et al. Oromaxillofacial osseous abnormality in Sturge-Weber syndrome: case report and review of the literature. AJNR Am J Neuroradiol. 2006 Feb;27(2):274-7. PMID: 16484391; X-1

2142. Linnankivi T, Valanne L, Paetau A, et al. Cerebroretinal microangiopathy with calcifications and cysts. Neurology. 2006 Oct 24;67(8):1437-43. PMID: 16943371; X-1

2143. Loeb JA, Sohrab SA, Huq M, et al. Brain calcifications induce neurological dysfunction that can be reversed by a bone drug. J Neurol Sci. 2006 Apr 15;243(1-2):77-81. PMID: 16430923; X-1

2144. Lomenick JP, Backeljauw PF, Lucky AW. Growth, bone mineral accretion, and adrenal function in glucocorticoid-treated infants with hemangiomas-- a retrospective study. Pediatr Dermatol. 2006 Mar-Apr;23(2):169-74. PMID: 16650230; X-4

2145. Manabe N, Tanaka S, Fukumoto A, et al. Double-balloon enteroscopy in patients with GI bleeding of obscure origin. Gastrointest Endosc. 2006 Jul;64(1):135-40. PMID: 16813826; X-1

2146. McLane K, Bookout KR, McCord S. Case study: using a negative pressure wound therapy device (NPWT) in pediatric patients. Journal of Wound, Ostomy & Continence Nursing. 2006;33(3S):S20-S. PMID: X-2

2147. Mehta JS, Gajdatsy A, Webster AR, et al. Severe, unstable migraine: a risk factor for postoperative ophthalmic artery spasm? Orbit. 2006 Mar;25(1):65-7. PMID: 16527781; X-1

2148. Metry DW, Haggstrom AN, Drolet BA, et al. A prospective study of PHACE syndrome in infantile hemangiomas: demographic features, clinical findings, and complications. Am J Med Genet A. 2006 May 1;140(9):975-86. PMID: 16575892; X-3, X-4

2149. Miller P, Mack CD, Sammer M, et al. The incidence and risk factors for hypotension during emergent decompressive craniotomy in children with traumatic brain injury. Anesth Analg. 2006 Oct;103(4):869-75. PMID: 17000796; X-1

2150. Mishra A, Tripathy K, Bhuyan P, et al. Endovascular papillary angioendothelioma in an elderly female. Indian J Pathol Microbiol. 2006 Jul;49(3):392-3. PMID: 17001894; X-1

2151. Morioka T, Hashiguchi K, Nagata S, et al. Epileptogenicity of supratentorial medullary venous malformation. Epilepsia. 2006 Feb;47(2):365-70. PMID: 16499761; X-1

2152. Morota N, Deletis V. The importance of brainstem mapping in brainstem surgical anatomy before the fourth ventricle and implication for intraoperative neurophysiological mapping. Acta Neurochir (Wien). 2006 May;148(5):499-509; discussion PMID: 16374568; X-1

2153. Murphy AM, Brenner C, Ann Lynch S. Agenesis of the corpus callosum with interhemispheric cyst, hepatic haemangioma and trisomy 21. Clin Dysmorphol. 2006 Jul;15(3):149-51. PMID: 16760733; X-2

2154. Nakamura A, Iguchi H, Kusuki M, et al. Intramasseteric schwannoma in a child. Auris Nasus Larynx. 2006 Sep;33(3):347-50. PMID: 16431063; X-1

2155. Nazir Z, Pervez S. Malignant vascular tumors of liver in neonates. J Pediatr Surg. 2006 Jan;41(1):e49-51. PMID: 16410090; X-1

2156. Neuhauser C, Dietrich K, Bettina R, et al. Successful laser-treatment of an endobronchial hemangioma in an infant. Int J Pediatr Otorhinolaryngol Extra. 2006 September;1(3):213-6. PMID: 2006420082; X-2

2157. Nomura S, Kato S, Ishihara H, et al. Association of intra- and extradural developmental venous anomalies, so-called venous angioma and sinus pericranii. Childs Nerv Syst. 2006 Apr;22(4):428-31. PMID: 16052365; X-1

2158. Oji C, Chukwuneke F, Mgbor N. Tobacco-pouch suture technique for the treatment of vascular lesions of the lip in Enugu, Nigeria. Br J Oral Maxillofac Surg. 2006 Jun;44(3):245-7. PMID: 16009473; X-1

2159. Opie JM, Chow CW, Ditchfield M, et al. Segmental haemangioma of infancy of the lower limb with skeletal overgrowth. Australas J Dermatol. 2006 Aug;47(3):198-203. PMID: 16867004; X-2

2160. Padalino MA, Zanon GF, Migneco F, et al. Surgical repair of incomplete cleft sternum and cardiac anomalies in early infancy. Ann Thorac Surg. 2006 Jun;81(6):2291-4. PMID: 16731175; X-1

2161. Penido MG, Lima EM, Souto MF, et al. Hypocitraturia: a risk factor for reduced bone mineral density in idiopathic hypercalciuria? Pediatr Nephrol. 2006 Jan;21(1):74-8. PMID: 16252112; X-1

2162. Phan TA, Adams S, Wargon O. Segmental haemangiomas of infancy: A review of 14 cases. Australas J Dermatol. 2006 Nov;47(4):242-7. PMID: 17034465; X-4

2163. Pienaar C, Graham R, Geldenhuys S, et al. Intralesional bleomycin for the treatment of hemangiomas. Plast Reconstr Surg. 2006 Jan;117(1):221-6. PMID: 16404271; X-3

2164. Pirgon O, Atabek ME, Akin F, et al. A case of Perlman syndrome presenting with hemorrhagic hemangioma. J Pediatr Hematol Oncol. 2006 Aug;28(8):531-3. PMID: 16912594; X-1, X-2

2165. Pirie S. Minerva. BMJ Case Rep. 2006;333(7562):310-. PMID: X-1

2166. Pittman KM, Losken HW, Kleinman ME, et al. No evidence for maternal-fetal microchimerism in infantile hemangioma: a molecular genetic investigation. J Invest Dermatol. 2006 Nov;126(11):2533-8. PMID: 16902414; X-3

2167. Prabhakar MM, Thakker T. Anterior decompression for cervicothoracic pathology: A study of 14 patients. J Spinal Cord Med. 2006;29(2):163-6. PMID: 16739561; X-1

2168. Puxeddu R, Berlucchi M, Ledda GP, et al. Lobular capillary hemangioma of the nasal cavity: A retrospective study on 40 patients. Am J Rhinol. 2006 Jul-Aug;20(4):480-4. PMID: 16955784; X-1

2169. Rasmussen A, Nava-Salazar S, Yescas P, et al. Von Hippel-Lindau disease germline mutations in Mexican patients with cerebellar hemangioblastoma. J Neurosurg. 2006 Mar;104(3):389-94. PMID: 16572651; X-1

2170. Riley MR, Garcia MG, Cox KL, et al. Hepatic infantile hemangioendothelioma with unusual manifestations. J Pediatr Gastroenterol Nutr. 2006 Jan;42(1):109-13. PMID: 16385264; X-1

2171. Ritter MR, Reinisch J, Friedlander SF, et al. Myeloid cells in infantile hemangioma. Am J Pathol. 2006 Feb;168(2):621-8. PMID: 16436675; X-1

2172. Rosca TI, Pop MI, Curca M, et al. Vascular tumors in the orbit--capillary and cavernous hemangiomas. Ann Diagn Pathol. 2006 Feb;10(1):13-9. PMID: 16414539; X-1, X-2

2173. Saad DF, Shehata BM, Patrick E, et al. Intramuscular hemangioma of the abdominal wall. J Pediatr Surg. 2006 Mar;41(3):601-2. PMID: 16516647; X-1, X-2

2174. Schropp C, Sorensen N, Krauss J. Early periinsular hemispherotomy in children with Sturge-Weber syndrome and intractable epilepsy--outcome in eight patients. Neuropediatrics. 2006 Feb;37(1):26-31. PMID: 16541365; X-1

2175. Schulze SM, Moser RL, Bhattacharyya N. A rare case of diffuse neonatal hemangimatosis. Am Surg. 2006 Apr;72(4):359-62. PMID: 16676865; X-1, X-2

2176. Schwartz SR, Blei F, Ceisler E, et al. Risk factors for amblyopia in children with capillary hemangiomas of the eyelids and orbit. J aapos. 2006 Jun;10(3):262-8. PMID: 16814181; X-3

2177. Sciarretta V, Pasquini E, Frank G, et al. Endoscopic treatment of benign tumors of the nose and paranasal sinuses: a report of 33 cases. Am J Rhinol. 2006 Jan-Feb;20(1):64-71. PMID: 16539297; X-1

2178. Senthilkumar M, Thappa DM. Vascular nevi in children. Indian J Dermatol Venereol Leprol. 2006 Jan-Feb;72(1):19-23. PMID: 16481704; X-3

2179. Shalaby RY, Fawy M, Soliman SM, et al. A new simplified technique for needlescopic inguinal herniorrhaphy in children. J Pediatr Surg. 2006 Apr;41(4):863-7. PMID: 16567212; X-1

2180. Shamaly H, Abu-Nassar Z, Groisman GM, et al. Hepatic hemangloendothelioma: the need for early diagnosis and resection. Isr Med Assoc J. 2006 Aug;8(8):585-6. PMID: 16958255; X-1

2181. Shimizu T, Sugawara K, Tosaka M, et al. Nestin expression in vascular malformations: a novel marker for proliferative endothelium. Neurol Med Chir (Tokyo). 2006 Mar;46(3):111-7. PMID: 16565580; X-1

2182. Shroff PK, Martin TW, Schmitz ML. Successful anesthetic management of a child with an extensive facial hemangioma and high output cardiac failure for placement of a central venous catheter. Paediatr Anaesth. 2006 Jan;16(1):77-81. PMID: 16409535; X-2

2183. Shuman C, Smith AC, Steele L, et al. Constitutional UPD for chromosome 11p15 in individuals with isolated hemihyperplasia is associated with high tumor risk and occurs following assisted reproductive technologies. Am J Med Genet A. 2006 Jul 15;140(14):1497-503. PMID: 16770802; X-1

2184. Simonetti V, Legori A, Strippoli D, et al. Diffuse neonatal hemangiomatosis. A case report with limited visceral involvement. European Journal of Pediatric Dermatology. 2006;16(2):77-80. PMID: 2006491706; X-1

2185. Slasky SE, Shinnar S, Bello JA. Sturge-Weber syndrome: deep venous occlusion and the radiologic spectrum. Pediatr Neurol. 2006 Nov;35(5):343-7. PMID: 17074605; X-1

2186. Snell M, Chau C, Hendrix D, et al. Lack of isohemagglutinin production following minor ABO incompatible unrelated HLA mismatched umbilical cord blood transplantation. Bone Marrow Transplant. 2006 Jul;38(2):135-40. PMID: 16751785; X-1

2187. Sterescu AE, Rousseau-Harsany E, Farrell C, et al. The potential efficacy of omega-3 fatty acids as anti-angiogenic agents in benign vascular tumors of infancy. Med Hypotheses. 2006;66(6):1121-4. PMID: 16500033; X-1, X-2

2188. Surucu O, Sure U, Gaetzner S, et al. Clinical impact of CCM mutation detection in familial cavernous angioma. Childs Nerv Syst. 2006 Nov;22(11):1461-4. PMID: 16983571; X-1

2189. Taki M, Ohi C, Yamashita A, et al. Successful treatment with vincristine of an infant with intractable Kasabach-Merritt syndrome. Pediatr Int. 2006 Feb;48(1):82-4. PMID: 16490078; X-1

2190. Tekkok IH, Sav A. Supratentorial cystic hemangioblastoma with infratentorial extension--a unique location and a rare infant case. Childs Nerv Syst. 2006 Sep;22(9):1177-81. PMID: 16534645; X-1

2191. Tennant LB, Mulliken JB, Perez-Atayde AR, et al. Verrucous hemangioma revisited. Pediatr Dermatol. 2006 May-Jun;23(3):208-15. PMID: 16780464; X-1

2192. Tsang MW, Garzon MC, Frieden IJ. How to measure a growing hemangioma and assess response to therapy. Pediatr Dermatol. 2006 Mar-Apr;23(2):187-90. PMID: 16650235; X-1, X-2

2193. Tucci E, Della Rocca C, Santilli F. Localized bacillary angiomatosis in the oral cavity: observations about a neoplasm with atypical behavior. Description of a case and review of the literature. Minerva Stomatol. 2006 Jan-Feb;55(1-2):67-75. PMID: 16495874; X-1

2194. Turker M, Irken G, Oren H, et al. Evaluation of plasma tissue factor and tissue factor pathway inhibitor levels in childhood hemangiomas. Pediatr Blood Cancer. 2006 Dec;47(7):914-7. PMID: 16395682; X-3

2195. Van Genechten M, Schelfout K, Wojciechowski M, et al. Intravascular papillary endothelial hyperplasia (Masson's tumor) on the anterior chest wall in a 3-year-old boy. Eur J Cardiothorac Surg. 2006 Dec;30(6):938. PMID: 17052911; X-1

2196. Vasudevan SA, Cumbie TA, Dishop MK, et al. Retroperitoneal hemangioma of infancy. J Pediatr Surg. 2006 Jan;41(1):e41-4. PMID: 16410088; X-2

2197. Vesnaver A, Dovsak DA. Treatment of vascular lesions in the head and neck using Nd:YAG laser. J Craniomaxillofac Surg. 2006 Jan;34(1):17-24. PMID: 16352435; X-1

2198. Vijayasekaran S, White DR, Hartley BE, et al. Open excision of subglottic hemangiomas to avoid tracheostomy. Arch Otolaryngol Head Neck Surg. 2006 Feb;132(2):159-63. PMID: 16490873; X-4

2199. Viskova H, Calda P, Zizka Z, et al. Prenatal diagnosis of occipital dermal sinus associated with hemangioma using ultrasound and MRI. Case report. Fetal Diagn Ther. 2006;21(2):232-4. PMID: 16491009; X-1

2200. Vogel AM, Alesbury JM, Burrows PE, et al. Vascular anomalies of the female external genitalia. J Pediatr Surg. 2006 May;41(5):993-9. PMID: 16677899; X-3, X-4

2201. Vogel AM, Alesbury JM, Fox VL, et al. Complex pancreatic vascular anomalies in children. J Pediatr Surg. 2006 Mar;41(3):473-8. PMID: 16516618; X-3, X-4

2202. Vougioukas VI, Glasker S, Hubbe U, et al. Surgical treatment of hemangioblastomas of the central nervous system in pediatric patients. Childs Nerv Syst. 2006 Sep;22(9):1149-53. PMID: 16369852; X-1

2203. Vougiouklakis T, Mitselou A, Zikopoulos K, et al. Ruptured hemangioma of the umbilical cord and intrauterine fetal death, with review data. Pathol Res Pract. 2006;202(7):537-40. PMID: 16684589; X-1

2204. Waldman EH, Goldenberg D, Califano J, et al. Venous malformation of the sternomastoid muscle. Otolaryngol Head Neck Surg. 2006 Aug;135(2):325-7. PMID: 16890092; X-1

2205. Wananukul S, Voramethkul W, Nuchprayoon I, et al. Diffuse Neonatal Hemangiomatosis: report of 5 cases. J Med Assoc Thai. 2006 Aug;89(8):1297-303. PMID: 17048444; X-1

2206. Welch DE, Ignatz ME, Sullivan SE, et al. Orbital hemangioma requiring enucleation in a premature infant. J Pediatr Ophthalmol Strabismus. 2006 Nov-Dec;43(6):365-6. PMID: 17162974; X-2

2207. Winkler D, Lindner D, Strauss G, et al. Surgery of cavernous malformations with and without navigational support--a comparative study. Minim Invasive Neurosurg. 2006 Feb;49(1):15-9. PMID: 16547876; X-1

2208. Witman PM, Wagner AM, Scherer K, et al. Complications following pulsed dye laser treatment of superficial hemangiomas. Lasers Surg Med. 2006 Feb;38(2):116-23. PMID: 16493677; X-4

2209. Woo SH, Ahn HH, Kim SN, et al. Treatment of vascular skin lesions with the variable-pulse 595 nm pulsed dye laser. Dermatol Surg. 2006 Jan;32(1):41-8. PMID: 16393597; X-1

2210. Wu SC, Lin KK. Ahmed glaucoma valve implant for childhood glaucoma in Sturge-Weber syndrome with choroidal hemangioma. Chang Gung Med J. 2006 Sep-Oct;29(5):528-31. PMID: 17214399; X-1

2211. Yallapragada AV, Cure JK, Holden KR. Sturge-Weber syndrome variant with atypical intracranial findings: case report. J Child Neurol. 2006 Feb;21(2):155-7. PMID: 16566882; X-1

2212. Yan AC, Chamlin SL, Liang MG, et al. Congenital infantile fibrosarcoma: a masquerader of ulcerated hemangioma. Pediatr Dermatol. 2006 Jul-Aug;23(4):330-4. PMID: 16918626; X-1

2213. Yeung J, Somers G, Viero S, et al. Multifocal lymphangioendotheliomatosis with thrombocytopenia. J Am Acad Dermatol. 2006 May;54(5 Suppl):S214-7. PMID: 16631943; X-1

2214. Yoshida S, Kikuchi A, Naito S, et al. Giant hemangioma of the fetal neck, mimicking a teratoma. J Obstet Gynaecol Res. 2006 Feb;32(1):47-54. PMID: 16445525; X-1

2215. Zakaria MA, Abdullah JM, George JP, et al. Third ventricular cavernous angioma. Med J Malaysia. 2006 Jun;61(2):229-32. PMID: 16898318; X-1

2216. . PeDIATRICS electronic pages. Pediatrics. 2007;119(6):1181-93. PMID: X-1

2217. Abernethy L. Paediatric neck lumps III -- vascular and lymphatic malformations. Ultrasound. 2007;15(3):142-7. PMID: X-1

2218. Al-Ata J, Arfi AM, Hussain A, et al. Stent angioplasty: an effective alternative in selected infants with critical native aortic coarctation. Pediatr Cardiol. 2007 May-Jun;28(3):183-92. PMID: 17457637; X-1

2219. Amer TA, Elwakil TF, Elbasiouny MS. Open rhinoplasty for treatment of nasal tip haemangioma. Eur J Plast Surg. 2007 September;30(2):67-73. PMID: 2007465247; X-4

2220. Amini H, Razeghinejad MR, Esfandiarpour B. Primary single-plate Molteno tube implantation for management of glaucoma in children with Sturge-Weber syndrome. Int Ophthalmol. 2007 Dec;27(6):345-50. PMID: 17557138; X-1

2221. Ammerman RT, Bodley AL, Putnam FW, et al. In-home cognitive behavior therapy for a depressed mother in a home visitation program. Clin Case Stud. 2007 April;6(2):161-80. PMID: 2007169585; X-1

2222. Baccin CE, Krings T, Alvarez H, et al. A report of two cases with dolichosegmental intracranial arteries as a new feature of PHACES syndrome. Childs Nerv Syst. 2007 May;23(5):559-67. PMID: 17053935; X-1, X-2

2223. Badran AM, Vahedi K, Berrebi D, et al. Pediatric ampullar and small bowel blue rubber bleb nevus syndrome diagnosed by wireless capsule endoscopy. J Pediatr Gastroenterol Nutr. 2007 Feb;44(2):283-6. PMID: 17255847; X-1

2224. Balazs AE, Athanassaki I, Gunn SK, et al. Rapid resolution of consumptive hypothyroidism in a child with hepatic hemangioendothelioma following liver transplantation. Ann Clin Lab Sci. 2007 Summer;37(3):280-4. PMID: 17709695; X-1

2225. Baraka A. A simple approach to airway management in a child with a giant tongue hemangioma--a case report. Middle East J Anesthesiol. 2007 Jun;19(2):469-70. PMID: 17684885; X-2

2226. Barankin B. Dermatology case challenge: what is the lesion on this infant's face? Patient Care. 2007;41:2p. PMID: X-1

2227. Battistini S, Rocchi R, Cerase A, et al. Clinical, magnetic resonance imaging, and genetic study of 5 Italian families with cerebral cavernous malformation. Arch Neurol. 2007 Jun;64(6):843-8. PMID: 17562932; X-1

2228. Baumann CR, Acciarri N, Bertalanffy H, et al. Seizure outcome after resection of supratentorial cavernous malformations: a study of 168 patients. Epilepsia. 2007 Mar;48(3):559-63. PMID: 17346251; X-1

2229. Bella GP, Manivel JC, Thompson RC, Jr., et al. Intramuscular hemangioma: recurrence risk related to surgical margins. Clin Orthop Relat Res. 2007 Jun;459:186-91. PMID: 17438470; X-1

2230. Berkley EM, Gill GJ, Moore LE, et al. Consumptive coagulopathy associated with Gorham syndrome and subsequent Kasabach-Merritt syndrome during pregnancy: a case report. J Reprod Med. 2007 Dec;52(12):1103-6. PMID: 18210901; X-1

2231. Bhagtani H, Love E, Baci G, et al. Index of suspicion. Pediatr Rev. 2007 Jun;28(6):225-9. PMID: 17545334; X-2

2232. Bhattacharjee K, Bhattacharjee H, Deka A. Acute progressive multiple cavernous hemangiomas of orbit in a child--a case report. Orbit. 2007 Jun;26(2):117-9. PMID: 17613859; X-1

2233. Bhattacharyya NK, Chatterjee U, Sen S, et al. Infantile hemangioendothelioma of liver: report of two cases. Indian J Pathol Microbiol. 2007 Apr;50(2):340-2. PMID: 17883065; X-1, X-2

2234. Bourgeois M, Crimmins DW, de Oliveira RS, et al. Surgical treatment of epilepsy in Sturge-Weber syndrome in children. J Neurosurg. 2007 Jan;106(1 Suppl):20-8. PMID: 17233308; X-1

2235. Bradfield YS, Kulkarni A, Potter HD, et al. Eyelid fibrous hamartoma with conjunctival angioma in an infant. Arch Ophthalmol. 2007 Jun;125(6):843-5. PMID: 17563002; X-1

2236. Burn S, Gunny R, Phipps K, et al. Incidence of cavernoma development in children after radiotherapy for brain tumors. J Neurosurg. 2007 May;106(5 Suppl):379-83. PMID: 17566205; X-1

2237. Carroll MB, Higgs JB. Synovial haemangioma presenting as a recurrent monoarticular haemarthrosis. Arch Dis Child. 2007 Jul;92(7):623-4. PMID: 17588975; X-1

2238. Caruana CM. Skin deep: from rashes to birthmarks -- when to worry, when to wait. American Baby. 2007;69(7):29. PMID: X-1, X-2

2239. Chadha M, Singh AP. Unusual knee swelling: a diagnostic dilemma. Arch Orthop Trauma Surg. 2007 Sep;127(7):593-6. PMID: 17165037; X-1, X-2

2240. Chamlin SL, Haggstrom AN, Drolet BA, et al. Multicenter prospective study of ulcerated hemangiomas. J Pediatr. 2007 Dec;151(6):684-9, 9.e1. PMID: 18035154; X-3

2241. Chan KL. Laparoscopic repair of recurrent childhood inguinal hernias after open herniotomy. Hernia. 2007 Feb;11(1):37-40. PMID: 17006622; X-1

2242. Chatha DS, Rybak LD, Wittig JC, et al. Orthopaedic-radiology-pathology conference: Elbow mass in a 9-year-old girl. Clin Orthop Relat Res. 2007 Oct;463:237-43. PMID: 17327808; X-1

2243. Chavers BM, Solid CA, Gilbertson DT, et al. Infection-related hospitalization rates in pediatric versus adult patients with end-stage renal disease in the United States. J Am Soc Nephrol. 2007 Mar;18(3):952-9. PMID: 17251389; X-1

2244. Christison-Lagay ER, Burrows PE, Alomari A, et al. Hepatic hemangiomas: subtype classification and development of a clinical practice algorithm and registry. J Pediatr Surg. 2007 Jan;42(1):62-7; discussion 7-8. PMID: 17208542; X-2

2245. Comati A, Beck H, Halliday W, et al. Upregulation of hypoxia-inducible factor (HIF)-1alpha and HIF-2alpha in leptomeningeal vascular malformations of Sturge-Weber syndrome. J Neuropathol Exp Neurol. 2007 Jan;66(1):86-97. PMID: 17204940; X-1

2246. Conroy FJ, Mahaffey PJ. The use of reinforced adhesive tape in supporting pendulous upper eyelid lesions. Ann Plast Surg. 2007 May;58(5):584-5. PMID: 17452849; X-1, X-2

2247. Correa PH, Nunes LC, Johann AC, et al. Prevalence of oral hemangioma, vascular malformation and varix in a Brazilian population. Braz Oral Res. 2007 Jan-Mar;21(1):40-5. PMID: 17384854; X-1

2248. De Paoli AG, Williams M, Parsons SJ, et al. Massive hepatic congenital haemangioma: clinical dilemmas. J Paediatr Child Health. 2007 Apr;43(4):312-4. PMID: 17444837; X-1, X-2

2249. Deren O, Ozyuncu O, Onderoglu LS, et al. Alcohol injection for the intrauterine treatment of chorioangioma in a pregnancy with transfusion resistant fetal anemia: a case report. Fetal Diagn Ther. 2007;22(3):203-5. PMID: 17228160; X-1

2250. Devadason D, Murphy MS, Brown R, et al. Duodenal capillary hemangiomatous polyps: a novel manifestation of extrahepatic portal hypertension? J Pediatr Gastroenterol Nutr. 2007 Jul;45(1):114-6. PMID: 17592373; X-1

2251. Draghi F, Spinazzola A, Abbati D, et al. Hepatic sonography in the evaluation of potential multi-organ donors. J Ultrasound. 2007 March;10(1):1-4. PMID: 2007303463; X-1

2252. Drut R, Altamirano E. Endothelial cells of intramuscular (infantile) hemangioma express glut1. Int J Surg Pathol. 2007 Apr;15(2):166-8. PMID: 17478771; X-1

2253. Elgin U, Simsek T, Batman A. Use of the ex-press miniature glaucoma implant in a child with Sturge-Weber syndrome. J Pediatr Ophthalmol Strabismus. 2007 Jul-Aug;44(4):248-50. PMID: 17694831; X-1

2254. Ergun R, Okten AI, Gezercan Y, et al. Sturge-Weber syndrome accompanied with multiple congenital intracranial lesions. Acta Neurochir (Wien). 2007 Aug;149(8):829-30; discussion 30. PMID: 17660941; X-1

2255. Ergun SS, Kocabora MS, Su O, et al. Surgical treatment of giant pyogenic granuloma of the upper eyelid. Ann Ophthalmol (Skokie). 2007 Fall;39(3):264-6. PMID: 18025641; X-1, X-2

2256. Ewen JB, Comi AM, Kossoff EH. Myoclonic-astatic epilepsy in a child with Sturge-Weber syndrome. Pediatr Neurol. 2007 Feb;36(2):115-7. PMID: 17275664; X-1

2257. Farasat S. Dermatology: what's your Dx? Blueberries on a toddler... blue rubber bleb nevus syndrome. Contemp Pediatr. 2007;24(7):25. PMID: X-1

2258. Folia M, Naiman N, Dubois R, et al. Management of postcricoid and upper esophageal hemangioma. Int J Pediatr Otorhinolaryngol. 2007 Jan;71(1):147-51. PMID: 16930728; X-3, X-4

2259. Fu CH, Lee LA, Fang TJ, et al. Endoscopic Nd:YAG laser therapy of infantile subglottic hemangioma. Pediatr Pulmonol. 2007 Jan;42(1):89-92. PMID: 17106903; X-3, X-4

2260. Gallot D, Marceau G, Laurichesse-Delmas H, et al. The changes in angiogenic gene expression in recurrent multiple chorioangiomas. Fetal Diagn Ther. 2007;22(3):161-8. PMID: 17228150; X-1

2261. Gao S, Wang YJ, Li JN, et al. Clinical study of CHT-5302/Mp automatic copper needle therapeutic instrument on treatment of cavernous hemangioma and racemosum hemangioma. Eur J Plast Surg. 2007 February;29(6):271-5. PMID: 2007161607; X-1

2262. Geh JL, Geh VS, Jemec B, et al. Surgical treatment of periocular hemangiomas: a single-center experience. Plast Reconstr Surg. 2007 Apr 15;119(5):1553-62. PMID: 17415250; X-4

2263. Georgescu EF, Stanescu L, Dumitrescu D, et al. Portal cavernomatous transformation leading to variceal hemorrhage in Sturge-Webber syndrome. A rare, but possible association. Rom J Morphol Embryol. 2007;48(2):171-5. PMID: 17641805; X-1

2264. Ghosh A, Tibrewal SR, Thapa R. PHACES syndrome with congenital hypothyroidism. Indian Pediatr. 2007 Feb;44(2):144-7. PMID: 17351309; X-2

2265. Griffin N, Khan N, Thomas JM, et al. The radiological manifestations of intramuscular haemangiomas in adults: magnetic resonance imaging, computed tomography and ultrasound appearances. Skeletal Radiol. 2007 Nov;36(11):1051-9. PMID: 17849114; X-1

2266. Grootenhuis MA, Koopman HM, Verrips EG, et al. Health-related quality of life problems of children aged 8-11 years with a chronic disease. Dev Neurorehabil. 2007 Jan-Mar;10(1):27-33. PMID: 17608324; X-1, X-3

2267. Gumus A, Yildirim SV, Kizilkilic O, et al. Case report: seizures in a child caused by a large venous angioma. J Child Neurol. 2007 Jun;22(6):787-9. PMID: 17641273; X-1

2268. Haggstrom AN, Drolet BA, Baselga E, et al. Prospective study of infantile hemangiomas: demographic, prenatal, and perinatal characteristics. J Pediatr. 2007 Mar;150(3):291-4. PMID: 17307549; X-3

2269. Hall BD, Cadle RG, Morrill-Cornelius SM, et al. Phakomatosis pigmentovascularis: Implications for severity with special reference to Mongolian spots associated with Sturge-Weber and Klippel-Trenaunay syndromes. Am J Med Genet A. 2007 Dec 15;143a(24):3047-53. PMID: 17937434; X-1

2270. Hammen T, Romstock J, Dorfler A, et al. Prediction of postoperative outcome with special respect to removal of hemosiderin fringe: a study in patients with cavernous haemangiomas associated with symptomatic epilepsy. Seizure. 2007 Apr;16(3):248-53. PMID: 17276092; X-1

2271. Hauer J, Graubner U, Konstantopoulos N, et al. Effective treatment of kaposiform hemangioendotheliomas associated with Kasabach-Merritt phenomenon using four-drug regimen. Pediatr Blood Cancer. 2007 Nov;49(6):852-4. PMID: 16411198; X-1

2272. Haught EA, Johnson MC, Witt PD. Congenital erythroleukemia presenting as a congenital infantile hemangioma. Plast Reconstr Surg. 2007 Apr 1;119(4):70e-2e. PMID: 17496582; X-1, X-2

2273. Herrero Hernandez A, Escobosa Sanchez O, Acha Garcia T. Successful treatment with vincristine in PHACES syndrome. Clin Transl Oncol. 2007 Apr;9(4):262-3. PMID: 17462981; X-2

2274. Hirth A, Berg A, Greve G. Successful treatment of severe heart failure in an infant with Hurler syndrome. J Inherit Metab Dis. 2007 Oct;30(5):820. PMID: 17768668; X-1

2275. Ho NT, Lansang P, Pope E. Topical imiquimod in the treatment of infantile hemangiomas: a retrospective study. J Am Acad Dermatol. 2007 Jan;56(1):63-8. PMID: 17190622; X-4

2276. Hohenleutner U, Landthaler M, Hamm H, et al. Hemangiomas of infancy and childhood. J Dtsch Dermatol Ges. 2007 Apr;5(4):334-8. PMID: 17376102; X-2

2277. Hsiao CH, Tsao PN, Hsieh WS, et al. Huge, alarming congenital hemangioma of the scalp presenting as heart failure and Kasabach-Merritt syndrome: a case report. Eur J Pediatr. 2007 Jun;166(6):619-20. PMID: 16937128; X-1

2278. Hsiao KH, Lin LH, Chen DF, et al. Hepatic mesenchymal hamartoma combined with infantile hepatic hemangioendothelioma in an infant. J Formos Med Assoc. 2007 Mar;106(3 Suppl):S1-4. PMID: 17493912; X-1

2279. Ibrahim H, Hussein S, Bagga B, et al. Hemangioendothelioma. J La State Med Soc. 2007 Nov-Dec;159(6):307-8. PMID: 18390267; X-1

2280. Izci Y, Gurkanlar D, Gonul E. An unusual type of split cord malformation. J Clin Neurosci. 2007 Apr;14(4):383-6. PMID: 17267224; X-2

2281. Jenny B, Radovanovic I, Haenggeli CA, et al. Association of multiple vertebral hemangiomas and severe paraparesis in a patient with a PTEN hamartoma tumor syndrome. Case report. J Neurosurg. 2007 Oct;107(4 Suppl):307-13. PMID: 17941496; X-2

2282. Joseph RA, Mackley AB, Davis CG, et al. Stress in fathers of surgical neonatal intensive care unit babies. Adv Neonatal Care. 2007 Dec;7(6):321-5. PMID: 18097216; X-1

2283. Joseph RA, Mackley AB, Davis CG, et al. Ethical issues in newborn care. Stress in fathers of surgical neonatal intensive care unit babies. Adv Neonatal Care. 2007;7(6):321-5. PMID: X-1

2284. Judd CD, Chapman PR, Koch B, et al. Intracranial infantile hemangiomas associated with PHACE syndrome. AJNR Am J Neuroradiol. 2007 Jan;28(1):25-9. PMID: 17213418; X-3, X-4

2285. Juhasz C, Batista CE, Chugani DC, et al. Evolution of cortical metabolic abnormalities and their clinical correlates in Sturge-Weber syndrome. Eur J Paediatr Neurol. 2007 Sep;11(5):277-84. PMID: 17408998; X-1

2286. Juhasz C, Lai C, Behen ME, et al. White matter volume as a major predictor of cognitive function in Sturge-Weber syndrome. Arch Neurol. 2007 Aug;64(8):1169-74. PMID: 17698708; X-1

2287. Kalpatthi R, Germak J, Mizelle K, et al. Thyroid abnormalities in infantile hepatic hemangioendothelioma. Pediatr Blood Cancer. 2007 Dec;49(7):1021-4. PMID: 16544297; X-1

2288. Kamida T, Takeda Y, Fujiki M, et al. Nitric oxide synthase and NMDA receptor expressions in cavernoma tissues with epileptogenesis. Acta Neurol Scand. 2007 Dec;116(6):368-73. PMID: 17986094; X-1

2289. Kammoun H, Jallouli M, Gouiaa N, et al. Unusual location of a capillary hemangioma: inguinal location. Aesthetic Plast Surg. 2007 Sep-Oct;31(5):593-5. PMID: 17576501; X-2

2290. Karabagli H, Karabagli P, Alpman A, et al. Congenital supratentorial cystic hemangioblastoma. Case report and review of the literature. J Neurosurg. 2007 Dec;107(6 Suppl):515-8. PMID: 18154025; X-1

2291. Karakus MF, Ozcan KM, Bilal N, et al. Pediatric lobular capillary hemangioma accompanied with a foreign body in the nasal cavity. Int J Pediatr Otorhinolaryngol Extra. 2007 December;2(4):231-4. PMID: 2007506695; X-1, X-2

2292. Kaselas C, Tsikopoulos G, Papouis G, et al. Intralesional administration of interferon A for the management of severe haemangiomas. Pediatr Surg Int. 2007 Mar;23(3):215-8. PMID: 17171547; X-3

2293. Kerimoglu U, Uzumcugil A, Yilmaz G, et al. Intraneural hemangioma of digital nerve diagnosed with MR imaging. Skeletal Radiol. 2007 Feb;36(2):157-60. PMID: 16552604; X-2

2294. Khan MH, Walshe P, Russell J, et al. Congenital subglotic haemingiomas. Ir Med J. 2007 Jan;100(1):339-41. PMID: 17380926; X-1, X-2

2295. Khanna G, Van Heest AE, Agel J, et al. Analysis of factors affecting development of carpal tunnel syndrome in patients with Hurler syndrome after hematopoietic cell transplantation. Bone Marrow Transplant. 2007 Mar;39(6):331-4. PMID: 17277793; X-1

2296. Kharkar S, Shuck J, Conway J, et al. The natural history of conservatively managed symptomatic intramedullary spinal cord cavernomas. Neurosurgery. 2007 May;60(5):865-72; discussion -72. PMID: 17460522; X-1

2297. Kibar Y, Irkilata HC, Coban H, et al. Combined use of percutaneous and transurethral instruments in the preadolescent children with intravesical pathologies. Int Urol Nephrol. 2007;39(3):775-8. PMID: 17333527; X-1

2298. Kirac M, Camtosun A, Canpolat B, et al. Capillary haemangioma of the scrotum. Gazi Medical Journal. 2007 March;18(1):43-4. PMID: 2007217869; X-2

2299. Kleinman ME, Greives MR, Churgin SS, et al. Hypoxia-induced mediators of stem/progenitor cell trafficking are increased in children with hemangioma. Arterioscler Thromb Vasc Biol. 2007 Dec;27(12):2664-70. PMID: 17872454; X-1

2300. Kon T, Mori H, Hasegawa K, et al. Neonatal cavernous angioma located in the basal ganglia with profuse intraoperative bleeding. Childs Nerv Syst. 2007 Apr;23(4):449-53. PMID: 17103006; X-1

2301. Kossoff EH, Balasta M, Hatfield LM, et al. Self-reported treatment patterns in patients with Sturge-Weber syndrome and migraines. J Child Neurol. 2007 Jun;22(6):720-6. PMID: 17641257; X-1

2302. Kurschel S, Maier R, Gellner V, et al. Chiari I malformation and intra-cranial hypertension:a case-based review. Childs Nerv Syst. 2007 Aug;23(8):901-5. PMID: 17486353; X-1

2303. Kwok-Williams M, Perez Z, Squire R, et al. Radiotherapy for life-threatening mediastinal hemangioma with Kasabach-Merritt syndrome. Pediatr Blood Cancer. 2007 Oct 15;49(5):739-44. PMID: 16453298; X-1, X-2

2304. Lagreze WA, Zobor G. A method for noncontact measurement of corneal diameter in children. Am J Ophthalmol. 2007 Jul;144(1):141-2. PMID: 17601441; X-1

2305. Lapkin E. About face. Parents. 2007;82(7):44-, 7, 9 passim. PMID: X-1, X-2

2306. Lee BB, Laredo J, Lee SJ, et al. Congenital vascular malformations: general diagnostic principles. Phlebology. 2007;22(6):253-7. PMID: 18274332; X-1

2307. Lee JW, Cho EY, Hong SH, et al. Spinal epidural hemangiomas: various types of MR imaging features with histopathologic correlation. AJNR Am J Neuroradiol. 2007 Aug;28(7):1242-8. PMID: 17698523; X-1, X-3

2308. Lerut JP, Orlando G, Adam R, et al. The place of liver transplantation in the treatment of hepatic epitheloid hemangioendothelioma: report of the European liver transplant registry. Ann Surg. 2007 Dec;246(6):949-57; discussion 57. PMID: 18043096; X-1

2309. Lesesky EB, Cunningham BB, Makkar HS. Pediatric surgical pearls: minimizing complications. Semin Cutan Med Surg. 2007 Mar;26(1):54-64. PMID: 17349564; X-1

2310. Levi M, Schwartz S, Blei F, et al. Surgical treatment of capillary hemangiomas causing amblyopia. J aapos. 2007 Jun;11(3):230-4. PMID: 17344079; X-4

2311. Liu L, Yang S, Han D, et al. Primary tumours of the facial nerve: diagnostic and surgical treatment experience in Chinese PLA General Hospital. Acta Otolaryngol. 2007 Sep;127(9):993-9. PMID: 17712681; X-1, X-2

2312. Maheshwari R, Thool A. Orbital cavernous hemangioma of childhood. Indian J Ophthalmol. 2007 Jul-Aug;55(4):313-5. PMID: 17595488; X-1

2313. Maronn ML, Corden T, Drolet BA. Pneumocystis carinii pneumonia in infant treated with oral steroids for hemangioma. Arch Dermatol. 2007 Sep;143(9):1224-5. PMID: 17875903; X-2

2314. Mathieu G, Mascard E, Wicart P, et al. Forefoot reconstruction after lesser intermediate metatarsal bone resection for aggressive or malignant tumors in children: report of three cases. Foot Ankle Int. 2007 Sep;28(9):1011-6. PMID: 17880877; X-1

2315. Menon P, Rao KL, Bhasin S, et al. Giant isolated cavernous hemangioma of the stomach. J Pediatr Surg. 2007 Apr;42(4):747-9. PMID: 17448781; X-1

2316. Miliaras D, Conroy J, Pervana S, et al. Karyotypic changes detected by comparative genomic hybridization in a stillborn infant with chorioangioma and liver hemangioma. Birth Defects Res A Clin Mol Teratol. 2007 Mar;79(3):236-41. PMID: 17203486; X-1

2317. Minzer-Conzetti K, Garzon MC, Haggstrom AN, et al. Information about infantile hemangiomas on the Internet: how accurate is it? J Am Acad Dermatol. 2007 Dec;57(6):998-1004. PMID: 17689833; X-1, X-2

2318. Mulliken JB, Bischoff J, Kozakewich HP. Multifocal rapidly involuting congenital hemangioma: a link to chorangioma. Am J Med Genet A. 2007 Dec 15;143a(24):3038-46. PMID: 17937433; X-1

2319. Mulliken JB, Marler JJ, Burrows PE, et al. Reticular infantile hemangioma of the limb can be associated with ventral-caudal anomalies, refractory ulceration, and cardiac overload. Pediatr Dermatol. 2007 Jul-Aug;24(4):356-62. PMID: 17845155; X-3, X-4

2320. Na JI, Cho KH, Kim YG, et al. Angioblastoma showing aggravation after treatment with long-pulsed Nd:YAG laser (1064 nm). Pediatr Dermatol. 2007 Jul-Aug;24(4):397-400. PMID: 17845165; X-1

2321. Nam YS, Hwang K. Intramuscular hemangioma of the lower lip. J Craniofac Surg. 2007 Jul;18(4):958-9. PMID: 17667695; X-1, X-2

2322. Oguz KK, Senturk S, Ozturk A, et al. Impact of recent seizures on cerebral blood flow in patients with sturge-weber syndrome: study of 2 cases. J Child Neurol. 2007 May;22(5):617-20. PMID: 17690070; X-1

2323. O'Regan GM, Watson R, Orr D, et al. Management of vascular birthmarks: review of a multidisciplinary clinic. Ir Med J. 2007 Apr;100(4):425-7. PMID: 17566475; X-1

2324. Ozkur A, Kervancioglu S, Kervancioglu R, et al. Prenatal sonographic diagnosis of an extensive fetal axillary hemangiolymphangioma. J Clin Ultrasound. 2007 Jun;35(5):274-6. PMID: 17354252; X-1

2325. Pascual-Castroviejo I, Lopez-Gutierrez JC. Cutaneous hemangioma associated with persistence of the trigeminal and both proatlantal arteries. J Child Neurol. 2007 Mar;22(3):337-40. PMID: 17621508; X-2

2326. Pascual-Castroviejo I, Pascual-Pascual SI, Lopez-Gutierrez JC, et al. Facial hemangioma and hemispheric migration disorder: presentation of 5 patients. AJNR Am J Neuroradiol. 2007 Sep;28(8):1609-12. PMID: 17846222; X-1

2327. Reddy AR, Chang BY, Bradbury JA. Is this really a capillary haemangioma? Orbit. 2007 Dec;26(4):327-9. PMID: 18097979; X-2

2328. Rodgers B, Zeim S, Crawford B, et al. Splenic papillary angioendothelioma in a 6-year-old girl. J Pediatr Hematol Oncol. 2007 Dec;29(12):808-10. PMID: 18090926; X-1

2329. Rudy SJ. Pediatric dermatology: fungal/yeast infections, viral infections, acne, and hemangiomas. Dermatol Nurs. 2007 Oct;19(5):507-8. PMID: 18286865; X-1

2330. Russell RT, Carlin A, Ashworth M, et al. Diffuse placental chorioangiomatosis and fetal hydrops. Fetal Diagn Ther. 2007;22(3):183-5. PMID: 17228155; X-1

2331. San Millan Ruiz D, Delavelle J, Yilmaz H, et al. Parenchymal abnormalities associated with developmental venous anomalies. Neuroradiology. 2007 Dec;49(12):987-95. PMID: 17703296; X-1

2332. Sari S, Duruturk L. Radiographic evaluation of periapical healing of permanent teeth with periapical lesions after extrusion of AH Plus sealer. Oral Surg Oral Med Oral Pathol Oral Radiol Endod. 2007 Sep;104(3):e54-9. PMID: 17709070; X-1

2333. Schettini ST, Ribeiro RC, Brito PL, et al. Gastric hemangioma in a 5-year-old boy. J Pediatr Surg. 2007 Apr;42(4):717-8. PMID: 17448773; X-1, X-2

2334. Schmitz T, Opgen-Rhein B, Kroschwald P, et al. Severe transient cardiac failure caused by placental chorangiosis. Neonatology. 2007;91(4):271-4. PMID: 17568159; X-1

2335. Schwartz SR, Kodsi SR, Blei F, et al. Treatment of capillary hemangiomas causing refractive and occlusional amblyopia. J aapos. 2007 Dec;11(6):577-83. PMID: 17720571; X-3, X-4

2336. Sevinir B, Ozkan TB. Infantile hepatic hemangioendothelioma: clinical presentation and treatment. Turk J Gastroenterol. 2007 Sep;18(3):182-7. PMID: 17891692; X-1

2337. Shin HT, Orlow SJ, Chang MW. Ulcerated haemangioma of infancy: a retrospective review of 47 patients. Br J Dermatol. 2007 May;156(5):1050-2. PMID: 17326746; X-3, X-4

2338. Singhi P, Mahajan V, Hiremath GM. Joubert syndrome: Review and report of five cases from India. J Pediatr Neurol. 2007;5(4):317-21. PMID: 2008076771; X-1

2339. Sonabend M. Dermatology clinic. Case #1: growing vascular red plaque on a 3-month-old's face. Clinical Advisor. 2007;10(6):102. PMID: X-1, X-2

2340. Song JK, Niimi Y, Kupersmith MJ, et al. Postnatal growth and development of a cerebral arteriovenous malformation on serial magnetic resonance imaging in a child with hemangiomatosis. Case report. J Neurosurg. 2007 May;106(5 Suppl):384-7. PMID: 17566206; X-1

2341. Spalding SJ, Hennon T, Dohar J, et al. Neonatal lupus erythematosus complicated by mucocutaneous and visceral hemangiomas. Lupus. 2007;16(11):904-7. PMID: 17971365; X-1, X-2

2342. Steven M, Kumaran N, Carachi R, et al. Haemangiomas and vascular malformations of the limb in children. Pediatr Surg Int. 2007 Jun;23(6):565-9. PMID: 17390139; X-1

2343. Stockman A, Boralevi F, Taieb A, et al. SACRAL syndrome: spinal dysraphism, anogenital, cutaneous, renal and urologic anomalies, associated with an angioma of lumbosacral localization. Dermatology. 2007;214(1):40-5. PMID: 17191046; X-3, X-4

2344. Stojanovic VD, Milosevic BO, Djapic MB, et al. Idiopathic hypercalciuria associated with urinary tract infection in children. Pediatr Nephrol. 2007 Sep;22(9):1291-5. PMID: 17541648; X-1

2345. Sun ZJ, Zhang L, Zhang WF, et al. Epithelioid hemangioendothelioma of the oral cavity. Oral Dis. 2007 Mar;13(2):244-50. PMID: 17305630; X-1

2346. Syed SP, Martin AM, Haupt HM, et al. Angiostatin receptor annexin II in vascular tumors including angiosarcoma. Hum Pathol. 2007 Mar;38(3):508-13. PMID: 17239928; X-1

2347. Tanaka N, Tsuda M, Samura O, et al. Blue rubber bleb nevus syndrome: Report of a patient with hemangiomas of the vaginal portion of the cervix appearing during pregnancy. J Obstet Gynaecol Res. 2007 Aug;33(4):546-8. PMID: 17688627; X-1

2348. Tang B, Reardon W, Black GC, et al. Congenital ulcerating hemangioma in a baby with KRAS mutation and cardio-facio-cutaneous syndrome. Clin Dysmorphol. 2007 Jul;16(3):203-6. PMID: 17551339; X-2

2349. Tang Y, Liu W, Yu S, et al. A novel in vivo model of human hemangioma: xenograft of human hemangioma tissue on nude mice. Plast Reconstr Surg. 2007 Sep 15;120(4):869-78. PMID: 17805113; X-1

2350. Teh SH, Ong GB. Early presentation of right adrenal mass, hepatoblastoma and hepatic cavernous haemangioma in Beckwith-Wiedemann Syndrome. Med J Malaysia. 2007 Oct;62(4):345-6. PMID: 18551945; X-1

2351. Thomson K, Pinnock R, Teague L, et al. Vincristine for the treatment of Kasabach-Merritt syndrome: recent New Zealand case experience. N Z Med J. 2007;120(1249):U2418. PMID: 17308555; X-1

2352. TJ OL, Messner A. Open excision of subglottic hemangioma with microscopic dissection. Int J Pediatr Otorhinolaryngol. 2007 Sep;71(9):1371-6. PMID: 17644192; X-3, X-4

2353. Tubbs RS, Frykman PK, Harmon CM, et al. An unusual sequelae of an infected persistent dermal sinus tract. Childs Nerv Syst. 2007 May;23(5):569-71. PMID: 16944171; X-1

2354. van Lindert EJ, Tan TC, Grotenhuis JA, et al. Giant cavernous hemangiomas: report of three cases. Neurosurg Rev. 2007 Jan;30(1):83-92; discussion PMID: 16988810; X-1

2355. Vlahovic A, Simic R, Kravljanac D. Circular excision and purse-string suture technique in the management of facial hemangiomas. Int J Pediatr Otorhinolaryngol. 2007 Aug;71(8):1311-5. PMID: 17548115; X-4

2356. Weibel L, Hoey S, Syed S, et al. Picture of the month. Diagnosis: periocular hemangioma: an eye-opening experience. Arch Pediatr Adolesc Med. 2007 Oct;161(10):1001; discussion 2. PMID: 17909145; X-1

2357. Weitz J, Klimstra DS, Cymes K, et al. Management of primary liver sarcomas. Cancer. 2007 Apr 1;109(7):1391-6. PMID: 17315167; X-1

2358. Wilson MW, Hoehn ME, Haik BG, et al. Low-dose cyclophosphamide and interferon alfa 2a for the treatment of capillary hemangioma of the orbit. Ophthalmology. 2007 May;114(5):1007-11. PMID: 17337066; X-4

2359. Winestone JS, Lin J, Sanford RA, et al. Subepyndemal hemangioblastomas of the cervicomedullary junction: lessons learned in the management of two cases. Childs Nerv Syst. 2007 Jul;23(7):761-4. PMID: 17396270; X-1

2360. Wong WT, Agron E, Coleman HR, et al. Genotype-phenotype correlation in von Hippel-Lindau disease with retinal angiomatosis. Arch Ophthalmol. 2007 Feb;125(2):239-45. PMID: 17296901; X-1

2361. Woodward ER, Wall K, Forsyth J, et al. VHL mutation analysis in patients with isolated central nervous system haemangioblastoma. Brain. 2007 Mar;130(Pt 3):836-42. PMID: 17264095; X-1

2362. Wright DR, Russi DC, Mancini AJ, et al. The nasal crease sign in segmental facial hemangioma--an early sign of cartilage destruction. Pediatr Dermatol. 2007 May-Jun;24(3):241-5. PMID: 17542872; X-2

2363. Wu JL, Wu CC, Wang SJ, et al. Imaging strategies in intramuscular haemangiomas: an analysis of 20 cases. Int Orthop. 2007 Aug;31(4):569-75. PMID: 17021834; X-1

2364. Yan J, Qiu H, Li Y. Linear nevus sebaceous syndrome associated with choroidal hemangioma. Orbit. 2007 Dec;26(4):331-5. PMID: 18097980; X-1

2365. Yoon RK, Chussid S, Sinnarajah N. Characteristics of a pediatric patient with a capillary hemangioma of the palatal mucosa: a case report. Pediatr Dent. 2007 May-Jun;29(3):239-42. PMID: 17688022; X-2

2366. Yousenasna L. Neonatal hemangiomatosis. Dermatol Nurs. 2007 Feb;19(1):86. PMID: 17330561; X-1

2367. Yu TW, Liu HM, Lee WT. The correlation between motor impairment and cerebral blood flow in Sturge-Weber syndrome. Eur J Paediatr Neurol. 2007 Mar;11(2):96-103. PMID: 17317246; X-1

2368. Zhao J, Wang Y, Kang S, et al. The benefit of neuronavigation for the treatment of patients with intracerebral cavernous malformations. Neurosurg Rev. 2007 Oct;30(4):313-8; discussion 9. PMID: 17629759; X-1

2369. Zhao Y, Du GH, Wang YF, et al. Multiple intracranial cavernous malformations: clinical features and treatment. Surg Neurol. 2007 Nov;68(5):493-9; discussion 9. PMID: 17707490; X-1

2370. Zolkipli Z, Aylett S, Rankin PM, et al. Transient exacerbation of hemiplegia following minor head trauma in Sturge-Weber syndrome. Dev Med Child Neurol. 2007 Sep;49(9):697-9. PMID: 17718827; X-1

2371. . Management discussion. AAO-HNSF Patient of the Month Program. 2008;37(7):14-25. PMID: X-1

2372. Absi MA, Kin LL, Hanna A, et al. Index of suspicion. Pediatr Rev. 2008 Feb;29(2):61-6. PMID: 18245302; X-1

2373. Ahmadzadeh A, Hakimzadeh M, Safa-Abadi A. Idiopathic hypercalciuria in Iranian Children. Iran J Pediatr. 2008 June;18(2):163-6. PMID: 2008314671; X-1

2374. AlJasser M, Al-Khenaizan S. Cutaneous mimickers of child abuse: a primer for pediatricians. Eur J Pediatr. 2008 Nov;167(11):1221-30. PMID: 18661148; X-1

2375. Al-Khaldi A, Alhabshan F, Tamimi O, et al. Repair of aortic arch atresia with diffuse hypoplasia of the descending thoracic aorta. Eur J Cardiothorac Surg. 2008 Apr;33(4):751-3. PMID: 18262428; X-1, X-2

2376. Atta NM. Ultrasound guided ilioinguinal/iliohypogastric nerve block versus caudal block during surgical inguinal hernia repair in children. Egyptian Journal of Anaesthesia. 2008;24(2):101-7. PMID: 2010638742; X-1

2377. Balm AJ, Smeele LE, Lohuis PJ. Optimizing exposure of the posterolateral maxillary and pterygoid region: the lower cheek flap. Eur J Surg Oncol. 2008 Jun;34(6):699-703. PMID: 18029135; X-1

2378. Barry RB, Hughes BR, Cook LJ. Involution of infantile haemangiomas after imiquimod 5% cream. Clin Exp Dermatol. 2008 Jul;33(4):446-9. PMID: 18485022; X-3, X-4

2379. Baselga E, Cordisco MR, Garzon M, et al. Rapidly involuting congenital haemangioma associated with transient thrombocytopenia and coagulopathy: a case series. Br J Dermatol. 2008 Jun;158(6):1363-70. PMID: 18410425; X-1

2380. Bayliss SJ, Berk DR. Freckling 11 years after pulsed dye laser therapy for an infantile hemangioma: coincidence or a previously unrecognized complication? Clin Pediatr (Phila). 2008 Mar;47(2):189-90. PMID: 18057153; X-2

2381. Benifla M, Rutka JT, Otsubo H, et al. Long-term seizure and social outcomes following temporal lobe surgery for intractable epilepsy during childhood. Epilepsy Res. 2008 Dec;82(2-3):133-8. PMID: 18786810; X-1

2382. Bilgin O, Vollmar C, Peraud A, et al. Ictal SPECT in Sturge-Weber syndrome. Epilepsy Res. 2008 Feb;78(2-3):240-3. PMID: 18222066; X-1

2383. Blankenburg F, Scheer I, Sarioglu N, et al. Spontaneous regression of a vascular tumor of the skull base--infantile hemangioendothelioma? J Pediatr Hematol Oncol. 2008 Sep;30(9):712-5. PMID: 18776768; X-1

2384. Bliek J, Maas S, Alders M, et al. Epigenotype, phenotype, and tumors in patients with isolated hemihyperplasia. J Pediatr. 2008 Jul;153(1):95-100. PMID: 18571544; X-1

2385. Bramhall RJ, Quaba A. A review of 58 patients with periorbital haemangiomas to determine appropriate cases for intervention. J Plast Reconstr Aesthet Surg. 2008;61(2):138-49. PMID: 17981104; X-3, X-4

2386. Brandling-Bennett HA, Metry DW, Baselga E, et al. Infantile hemangiomas with unusually prolonged growth phase: a case series. Arch Dermatol. 2008 Dec;144(12):1632-7. PMID: 19075148; X-3, X-4

2387. Breysem L, Allewaert S, Claus F, et al. The use of duplex doppler ultrasound in a case of multifocal hepatic hemangioma. Jbr-btr. 2008 Jul-Aug;91(4):145-8. PMID: 18817086; X-2

2388. Buckmiller LM, Francis CL, Glade RS. Intralesional steroid injection for proliferative parotid hemangiomas. Int J Pediatr Otorhinolaryngol. 2008 Jan;72(1):81-7. PMID: 18054392; X-4

2389. Bukowinski AT, Ryan MA, Slymen DJ, et al. Haemangiomas and associated congenital malformations in a large population-based sample of infants. Paediatr Perinat Epidemiol. 2008 Nov;22(6):520-9. PMID: 19000289; X-3

2390. Campos M, Ortiz V, Correa MS, et al. Evidenced based management of neonatal hemangiolymphangioma: a case report. Bol Asoc Med P R. 2008 Apr-Jun;100(2):57-9. PMID: 19227732; X-1

2391. Canavese F, Soo BC, Chia SK, et al. Surgical outcome in patients treated for hemangioma during infancy, childhood, and adolescence: a retrospective review of 44 consecutive patients. J Pediatr Orthop. 2008 Apr-May;28(3):381-6. PMID: 18362808; X-3

2392. Caruso S, Miraglia R, Maruzzelli L, et al. An unusual presentation of malignant hepatic epithelioid haemangioendothelioma with left pleural and pulmonary localization. Pediatr Radiol. 2008 Sep;38(9):1027-30. PMID: 18542941; X-1

2393. Cenzato M, Stefini R, Ambrosi C, et al. Post-operative remnants of brainstem cavernomas: incidence, risk factors and management. Acta Neurochir (Wien). 2008 Sep;150(9):879-86; discussion 87. PMID: 18754072; X-1

2394. Ceyhan M, Elmali M, Yildiz L. Mediastinal hemangioma and accompanying aortic arch anomaly. Pediatr Cardiol. 2008 Jul;29(4):867-9. PMID: 18183452; X-2

2395. Chan LK, Smith GC, Quaba AA. The management of periorbital fat excess in haemangioma involution. J Plast Reconstr Aesthet Surg. 2008;61(2):133-7. PMID: 18024248; X-3, X-4

2396. Chang LC, Haggstrom AN, Drolet BA, et al. Growth characteristics of infantile hemangiomas: implications for management. Pediatrics. 2008 Aug;122(2):360-7. PMID: 18676554; X-3

2397. Chi LY, Wang SH, Liu XW, et al. Familial cerebral cavernous malformation: features of clinical manifestation, pathology and imaging in a Chinese family. Cerebrovasc Dis. 2008;26(2):206-8. PMID: 18628620; X-1

2398. Ch'ng S, Tan ST. Facial port-wine stains - clinical stratification and risks of neuro-ocular involvement. J Plast Reconstr Aesthet Surg. 2008 Aug;61(8):889-93. PMID: 17604243; X-1

2399. Cho YH, Taplin C, Mansour A, et al. Case report: consumptive hypothyroidism consequent to multiple infantile hepatic haemangiomas. Curr Opin Pediatr. 2008 Apr;20(2):213-5. PMID: 18332720; X-2

2400. Comi AM, Bellamkonda S, Ferenc LM, et al. Central hypothyroidism and Sturge-Weber syndrome. Pediatr Neurol. 2008 Jul;39(1):58-62. PMID: 18555176; X-1

2401. Connell F, Homfray T, Thilaganathan B, et al. Congenital vascular malformations: a series of five prenatally diagnosed cases. Am J Med Genet A. 2008 Oct 15;146a(20):2673-80. PMID: 18798321; X-1

2402. Daenekindt T, Weyns F, Kho KH, et al. Giant intracranial capillary hemangioma associated with enlarged head circumference in a newborn. J Neurosurg Pediatr. 2008 Jun;1(6):488-92. PMID: 18518703; X-2

2403. Dalen K, Bruaroy S, Wentzel-Larsen T, et al. Intelligence in children with hydrocephalus, aged 4-15 years: a population-based, controlled study. Neuropediatrics. 2008 Jun;39(3):146-50. PMID: 18991193; X-1

2404. Das S, Ankola P, Chiechi M, et al. Perinatal cerebral arterial infarction associated with a placental chorioangioma. Am J Perinatol. 2008 Jun;25(6):381-3. PMID: 18521777; X-1

2405. Datir A, James SL, Ali K, et al. MRI of soft-tissue masses: the relationship between lesion size, depth, and diagnosis. Clin Radiol. 2008 Apr;63(4):373-8; discussion 9-80. PMID: 18325355; X-1

2406. de Ribaupierre S, Ryser C, Villemure JG, et al. Cerebellar lesions: is there a lateralisation effect on memory deficits? Acta Neurochir (Wien). 2008 Jun;150(6):545-50; discussion 50. PMID: 18512000; X-1

2407. Deboer MD, Boston BA. Failure-to-thrive in an infant following injection of capillary hemangioma with triamcinolone acetonide. Clin Pediatr (Phila). 2008 Apr;47(3):296-9. PMID: 18057161; X-2

2408. Deng ZH, Xu CD, Chen SN. Diagnosis and treatment of blue rubber bleb nevus syndrome in children. World J Pediatr. 2008 Feb;4(1):70-3. PMID: 18402258; X-1

2409. Deyrup AT, Tighiouart M, Montag AG, et al. Epithelioid hemangioendothelioma of soft tissue: a proposal for risk stratification based on 49 cases. Am J Surg Pathol. 2008 Jun;32(6):924-7. PMID: 18551749; X-1

2410. Draper H, Diamond IR, Temple M, et al. Multimodal management of endangering hepatic hemangioma: impact on transplant avoidance: a descriptive case series. J Pediatr Surg. 2008 Jan;43(1):120-5; discussion 6. PMID: 18206468; X-3, X-4

2411. Egberts F, Mentzel T, Leuschner I, et al. Metastasizing epithelioid hemangioendothelioma of the nose in childhood. J Cutan Pathol. 2008 Oct;35 Suppl 1:80-2. PMID: 18544051; X-1

2412. Elluru RG. Infant with facial birthmark. AAO-HNSF Patient of the Month Program. 2008;37(8):1-32. PMID: X-1

2413. Enchev YP, Popov RV, Romansky KV, et al. Neuronavigated surgery of intracranial cavernomas--enthusiasm for high technologies or a gold standard? Folia Med (Plovdiv). 2008 Apr-Jun;50(2):11-7. PMID: 18702220; X-1

2414. Esposito V, Paolini S, Morace R, et al. Intraoperative localization of subcortical brain lesions. Acta Neurochir (Wien). 2008 Jun;150(6):537-42; discussion 43. PMID: 18458808; X-1

2415. Frei-Jones M, McKinstry RC, Perry A, et al. Use of thalidomide to diminish growth velocity in a life-threatening congenital intracranial hemangioma. J Neurosurg Pediatr. 2008 Aug;2(2):125-9. PMID: 18671617; X-2

2416. Freundlich M, Alon US. Bisphosphonates in children with hypercalciuria and reduced bone mineral density. Pediatr Nephrol. 2008 Dec;23(12):2215-20. PMID: 18704505; X-1

2417. Ganapathy S, Kleiner LI, Mirkin LD, et al. Intradural capillary hemangioma of the cauda equina. Pediatr Radiol. 2008 Nov;38(11):1235-8. PMID: 18663441; X-1

2418. Gao XH, Wang LL, Zhang L, et al. Familial nevus flammeus associated with early onset cherry angiomas. Int J Dermatol. 2008 Dec;47(12):1284-6. PMID: 19126018; X-1

2419. Gezen F, Karatas A, Is M, et al. Giant cavernous haemangioma in an infant. Br J Neurosurg. 2008 Dec;22(6):787-9. PMID: 18686064; X-1

2420. Greco F, Fiumara A, Sorge G, et al. Subgaleal hematoma in a child with Sturge-Weber syndrome: to prevent stroke-like episodes, is treatment with aspirin advisable? Childs Nerv Syst. 2008 Dec;24(12):1479-81. PMID: 18575872; X-1

2421. Greene AK. Corticosteroid treatment for problematic infantile hemangioma: evidence does not support an increased risk for cerebral palsy. Pediatrics. 2008 Jun;121(6):1251-2. PMID: 18519494; X-2

2422. Gunendi Z, Karatas GK, Sepici V. Diffuse cavernous haemangioma complicated with regional osteoporosis. Rheumatol Int. 2008 Aug;28(10):1041-3. PMID: 18309486; X-1, X-2

2423. Hennedige AA, Quaba AA, Al-Nakib K. Sturge-Weber syndrome and dermatomal facial port-wine stains: incidence, association with glaucoma, and pulsed tunable dye laser treatment effectiveness. Plast Reconstr Surg. 2008 Apr;121(4):1173-80. PMID: 18349634; X-1

2424. Hernandez-Martin A, Torrelo A. Cutaneous and paravertebral infantile hemangioma: report of two cases. Pediatr Dermatol. 2008 Mar-Apr;25(2):193-5. PMID: 18429777; X-2, X-3

2425. Hery G, Becmeur F, Mefat L, et al. Laparoscopic partial splenectomy: indications and results of a multicenter retrospective study. Surg Endosc. 2008 Jan;22(1):45-9. PMID: 17943384; X-1

2426. Herzog D, Soglio DB, Fournet JC, et al. Interface hepatitis is associated with a high incidence of late graft fibrosis in a group of tightly monitored pediatric orthotopic liver transplantation patients. Liver Transpl. 2008 Jul;14(7):946-55. PMID: 18581476; X-1

2427. Ho R. Hail to the red, white, and blue! Contemp Pediatr. 2008;25(9):51. PMID: X-1

2428. Hoey SE, Eastwood D, Monsell F, et al. Histopathological features of Proteus syndrome. Clin Exp Dermatol. 2008 May;33(3):234-8. PMID: 18205855; X-1

2429. Horgan N, O'Keefe M, McLoone E, et al. Fundus fluorescein angiographic characterization of diffuse choroidal hemangiomas. J Pediatr Ophthalmol Strabismus. 2008 Jan-Feb;45(1):26-30. PMID: 18286959; X-1

2430. Hu MH, Wu CT, Lin KL, et al. Intramedullary spinal arteriovenous malformation in a boy of familial cerebral cavernous hemangioma. Childs Nerv Syst. 2008 Mar;24(3):393-6. PMID: 18157540; X-1

2431. Inan M, Chan G, Littleton AG, et al. Efficacy and safety of percutaneous epiphysiodesis. J Pediatr Orthop. 2008 Sep;28(6):648-51. PMID: 18724201; X-1

2432. Jain T, Sharma R, Gupta R. Case report: Subutaneous hemangiomatosis causing Kasabach-Merritt syndrome - MRI features. Indian J Radiol Imaging. 2008 01 Nov;18(4):295-7. PMID: 2008555494; X-1, X-2

2433. Jarvi K, Roebuck DJ, Sebire NJ, et al. Successful treatment of extensive infantile hemangiomatosis of the small bowel in a 3-month-old with thalidomide and somatostatin analog. J Pediatr Gastroenterol Nutr. 2008 May;46(5):593-7. PMID: 18493217; X-1

2434. Jha B, Choudhary AK. Unusual cause of back pain in an adolescent patient: a case report and natural history of aggressive vertebral hemangioma in children. Pain Physician. 2008 Sep-Oct;11(5):687-92. PMID: 18850034; X-1

2435. Jia J, Huang X, Zhang WF, et al. Human monocyte-derived hemangioma-like endothelial cells: evidence from an in vitro study. Cardiovasc Pathol. 2008 Jul-Aug;17(4):212-8. PMID: 18402811; X-1

2436. Jimenez-Hernandez E, Duenas-Gonzalez MT, Quintero-Curiel JL, et al. Treatment with interferon-alpha-2b in children with life-threatening hemangiomas. Dermatol Surg. 2008 May;34(5):640-7. PMID: 18261103; X-4

2437. Jordan LC, Wityk RJ, Dowling MM, et al. Transcranial Doppler ultrasound in children with Sturge-Weber syndrome. J Child Neurol. 2008 Feb;23(2):137-43. PMID: 18056693; X-1

2438. Jorge BF, Del Pozo J, Castineiras I, et al. Treatment of ulcerated haemangiomas with a non-coherent pulsed light source: brief initial clinical report. J Cosmet Laser Ther. 2008 Mar;10(1):48-51. PMID: 18330798; X-3, X-4

2439. Kalicinski P, Ismail H, Broniszczak D, et al. Non-resectable hepatic tumors in children - role of liver transplantation. Ann Transplant. 2008;13(2):37-41. PMID: 18566558; X-1

2440. Kamada N, Mitani Y, Kihira K, et al. Images in cardiovascular medicine. Fatal pulmonary lymphangiectasia manifesting after repeated surgeries for intractable chylopericardium and chylothorax in a 20-month-old girl. Circulation. 2008 Apr 8;117(14):1894-6. PMID: 18391124; X-1

2441. Kamil D, Tepelmann J, Berg C, et al. Spectrum and outcome of prenatally diagnosed fetal tumors. Ultrasound Obstet Gynecol. 2008 Mar;31(3):296-302. PMID: 18307207; X-1

2442. Kan P, Tubay M, Osborn A, et al. Radiographic features of tumefactive giant cavernous angiomas. Acta Neurochir (Wien). 2008 Jan;150(1):49-55; discussion PMID: 18066488; X-1

2443. Kanaheswari Y, Hamzaini AH, Wong SW, et al. Malignant hypertension in a child with phakomatosis pigmentovascularis type II b. Acta Paediatr. 2008 Nov;97(11):1589-91. PMID: 18671691; X-1

2444. Kang GC, Song C. Forty-one cervicofacial vascular anomalies and their surgical treatment--retrospection and review. Ann Acad Med Singapore. 2008 Mar;37(3):165-79. PMID: 18392293; X-1

2445. Kella N, Rathi PK, Rathi S, et al. Small bowel haemangioma: A rare cause of intestinal obstruction in infant. Pak J Med Sci. 2008 July/September;24(4):629-31. PMID: 2008438668; X-2

2446. Keng CY, Lan HHC, Chen CCC, et al. Soft tissue hemangiomas: High-resolution grayscale and color Doppler ultrasonographic features in 43 patients. J Med Ultrasound. 2008;16(3):223-30. PMID: 2008547800; X-4

2447. Khan ZA, Boscolo E, Picard A, et al. Multipotential stem cells recapitulate human infantile hemangioma in immunodeficient mice. J Clin Invest. 2008 Jul;118(7):2592-9. PMID: 18535669; X-1

2448. Khanna G, Gupta A, Gupta V. Synovial hemangioma: a rare benign synovial lesion. Indian J Pathol Microbiol. 2008 Apr-Jun;51(2):257-8. PMID: 18603700; X-1

2449. Kok-Leng Yeow V, Por YC. An audit on orthognathic surgery: a single surgeon's experience. J Craniofac Surg. 2008 Jan;19(1):184-6. PMID: 18216686; X-1

2450. Kretschmar O, Knirsch W, Bernet V. Interventional treatment of a symptomatic neonatal hepatic cavernous hemangioma using the Amplatzer vascular plug. Cardiovasc Intervent Radiol. 2008 Mar-Apr;31(2):411-4. PMID: 17031730; X-1, X-2

2451. Kubiena H, Roka J, Frey M. Surgical management of facial vascular anomalies: Role of intraoperative seventh nerve monitoring. Eur J Plast Surg. 2008 June;31(2):65-9. PMID: 2008283253; X-2

2452. Kutluhan A, Bozdemir K, Ugras S. The treatment of tongue haemangioma by plasma knife surgery. Singapore Med J. 2008 Nov;49(11):e312-4. PMID: 19037538; X-1, X-2

2453. Kyllerman M, Himmelmann K, Fasth A, et al. Late cerebral graft versus host reaction in a bone marrow transplanted girl with Hurler (MPS I) disease. Neuropediatrics. 2008 Oct;39(5):249-51. PMID: 19294596; X-1

2454. Labauge P, Bouly S, Parker F, et al. Outcome in 53 patients with spinal cord cavernomas. Surg Neurol. 2008 Aug;70(2):176-81; discussion 81. PMID: 18207494; X-1

2455. Lahoti SL, McNeese MC, Girardet RG, et al. Vaginal complaints in the prepubertal girl. Contemp Pediatr. 2008;25(5):65-70. PMID: X-1

2456. Lau G. Fatal cerebral infarction complicating therapeutic embolisation of a facial cavernous haemangioma: a case report. Med Sci Law. 2008 Jul;48(3):256-60. PMID: 18754215; X-1

2457. Lawrence GC, Rettenmaier MA, Heinemann S, et al. A precarious pregnancy involving a patient with a large placental chorioangioma: a case report. Arch Gynecol Obstet. 2008 Oct;278(4):383-6. PMID: 18283474; X-1

2458. Leaute-Labreze C, Dumas de la Roque E, Hubiche T, et al. Propranolol for severe hemangiomas of infancy. N Engl J Med. 2008 Jun 12;358(24):2649-51. PMID: 18550886; X-2

2459. Lee JW, Kim DS, Shim KW, et al. Management of intracranial cavernous malformation in pediatric patients. Childs Nerv Syst. 2008 Mar;24(3):321-7. PMID: 17876588; X-1

2460. Leng T, Wang X, Huo R, et al. The value of three-dimensional computed tomographic angiography in the diagnosis and treatment of vascular lesions. Plast Reconstr Surg. 2008 Nov;122(5):1417-24. PMID: 18971725; X-3, X-4

2461. Mahajan D, Miller C, Hirose K, et al. Incidental reduction in the size of liver hemangioma following use of VEGF inhibitor bevacizumab. J Hepatol. 2008 Nov;49(5):867-70. PMID: 18814928; X-1

2462. Malm G, Gustafsson B, Berglund G, et al. Outcome in six children with mucopolysaccharidosis type IH, Hurler syndrome, after haematopoietic stem cell transplantation (HSCT). Acta Paediatr. 2008 Aug;97(8):1108-12. PMID: 18452566; X-1

2463. Martelli L, Collini P, Meazza C, et al. Angiomatoid fibrous histiocytoma in an HIV-positive child. J Pediatr Hematol Oncol. 2008 Mar;30(3):242-4. PMID: 18376290; X-1

2464. Martinez-Lage JF, de la Fuente I, Ros de San Pedro J, et al. Cavernomas in children with brain tumors: a late complication of radiotherapy. Neurocirugia (Astur). 2008 Feb;19(1):50-4. PMID: 18335155; X-1

2465. Mathelin C, Annane K, Treisser A, et al. Pregnancy and post-partum breast cancer: a prospective study. Anticancer Res. 2008 Jul-Aug;28(4c):2447-52. PMID: 18751433; X-1

2466. Melegh Z, Patel Y, Ramani P. Solitary pulmonary infantile hemangioma in an infant with atrial septal defect. Pediatr Dev Pathol. 2008 Nov-Dec;11(6):465-8. PMID: 17990917; X-2

2467. Mendiratta V, Anand R, Chander R, et al. Multiple neonatal haemangiomatosis with liver haemangiomas and anaemia. Australas J Dermatol. 2008 Feb;49(1):42-3. PMID: 18186848; X-2

2468. Metry DW, Siegel DH, Cordisco MR, et al. A comparison of disease severity among affected male versus female patients with PHACE syndrome. J Am Acad Dermatol. 2008 Jan;58(1):81-7. PMID: 18029054; X-2, X-3

2469. Motegi H, Kuroda S, Ishii N, et al. De novo formation of cavernoma after radiosurgery for adult cerebral arteriovenous malformation--case report. Neurol Med Chir (Tokyo). 2008 Sep;48(9):397-400. PMID: 18812682; X-1

2470. Mouat F, Evans HM, Cutfield WS, et al. Massive hepatic hemangioendothelioma and consumptive hypothyroidism. J Pediatr Endocrinol Metab. 2008 Jul;21(7):701-3. PMID: 18780606; X-1

2471. Mukhopadhyay S. Sturge-Weber syndrome: a case report. J Indian Soc Pedod Prev Dent. 2008 Jan;26 Suppl 1:S29-31. PMID: 18974543; X-1

2472. Muramatsu K, Ihara K, Tani Y, et al. Intramuscular hemangioma of the upper extremity in infants and children. J Pediatr Orthop. 2008 Apr-May;28(3):387-90. PMID: 18362809; X-1

2473. Mussa A, Baldassarre G, Rosaia De Santis L, et al. Four new cases of PHACES syndrome: variable phenotypic expression and endocrine features. Acta Paediatr. 2008 Dec;97(12):1729-33. PMID: 18801022; X-2

2474. Nakamura M, Ishii K, Watanabe K, et al. Surgical treatment of intramedullary spinal cord tumors: prognosis and complications. Spinal Cord. 2008 Apr;46(4):282-6. PMID: 17909556; X-1

2475. Naqvi AH, Alfonso DT, Flores P, et al. Resolution of brachial plexus palsy due to hemangioma after intravenous corticosteroid therapy. J Child Neurol. 2008 Aug;23(8):956-8. PMID: 18660479; X-1, X-2

2476. Naqvi J, Ordonez NG, Luna MA, et al. Epithelioid hemangioendothelioma of the head and neck: role of podoplanin in the differential diagnosis. Head Neck Pathol. 2008 Mar;2(1):25-30. PMID: 20614338; X-1

2477. Noudel R, Litre F, Vinchon M, et al. Intramedullary spinal cord cavernous angioma in children: case report and literature review. Childs Nerv Syst. 2008 Feb;24(2):259-63. PMID: 17849122; X-1

2478. Numanoglu KV, Tatli D. A rare cause of hemorrhagic shock in children: bladder hemangioma. J Pediatr Surg. 2008 Jul;43(7):e1-3. PMID: 18639666; X-1, X-2

2479. Ozer EA, Duman N, Kumral A, et al. Chorioangiomatosis presenting with severe anemia and heart failure in a newborn. Fetal Diagn Ther. 2008;23(1):5-6. PMID: 17934289; X-1

2480. Pachl M, Elmalik K, Cohen M, et al. Ruptured splenic cavernous hemangioma in a neonate. J Pediatr Surg. 2008 Feb;43(2):407-9. PMID: 18280302; X-1

2481. Pascual-Castroviejo I, Pascual-Pascual SI, Velazquez-Fragua R, et al. Sturge-Weber syndrome: study of 55 patients. Can J Neurol Sci. 2008 Jul;35(3):301-7. PMID: 18714797; X-1

2482. Patron ME, Duker JS. Girl referred for an unusual optic disc lesion. Ocular Surgery News. 2008;26(23):42. PMID: X-1

2483. Pereira VM, Geibprasert S, Krings T, et al. Pathomechanisms of symptomatic developmental venous anomalies. Stroke. 2008 Dec;39(12):3201-15. PMID: 18988912; X-1

2484. Pinho R, Rodrigues A, Proenca L, et al. Solitary hemangioma of the small bowel disclosed by wireless capsule endoscopy. Gastroenterol Clin Biol. 2008 Jan;32(1 Pt. 1):15-8. PMID: 18405648; X-1

2485. Polgreen LE, Tolar J, Plog M, et al. Growth and endocrine function in patients with Hurler syndrome after hematopoietic stem cell transplantation. Bone Marrow Transplant. 2008 Jun;41(12):1005-11. PMID: 18278070; X-1

2486. Prasad SC, Prasad KC, Bhat J. Vocal cord hemangioma. Med J Malaysia. 2008 Dec;63(5):419-20. PMID: 19803307; X-1

2487. Puvanachandra N, Heran MK, Lyons CJ. Morning glory disk anomaly with ipsilateral capillary hemangioma, agenesis of the internal carotid artery, and Horner syndrome: a variant of PHACES syndrome? J aapos. 2008 Oct;12(5):528-30. PMID: 18620881; X-1, X-2

2488. Quagliano F, Fontana L, Parente G, et al. Choroidal effusion after diode laser cyclophotocoagulation in Sturge-Weber syndrome. J aapos. 2008 Oct;12(5):526-7. PMID: 18571958; X-1

2489. Rahman M, Rahman S, Rahman M, et al. Overlapping of Sturge Weber syndrome and Klippel Trenaunay Weber syndrome. Mymensingh Med J. 2008 Jan;17(1):78-81. PMID: 18285739; X-1, X-2

2490. Rao RP, Drolet BA, Holland KE, et al. PHACES association: a vasculocutaneous syndrome. Pediatr Cardiol. 2008 Jul;29(4):793-9. PMID: 18427881; X-3, X-4

2491. Ray WZ, Lee A, Blackburn SL, et al. Pseudotumor cerebri following tapered corticosteroid treatment in an 8-month-old infant. J Neurosurg Pediatr. 2008 Jan;1(1):88-90. PMID: 18352810; X-2

2492. Rivera LK, Nelson BL. Juvenile hemangioma of the parotid gland. Head Neck Pathol. 2008 Jun;2(2):81-2. PMID: 20614327; X-2

2493. Rodriguez JA, Becker NS, O'Mahony CA, et al. Long-term outcomes following liver transplantation for hepatic hemangioendothelioma: the UNOS experience from 1987 to 2005. J Gastrointest Surg. 2008 Jan;12(1):110-6. PMID: 17710508; X-1

2494. Saetti R, Silvestrini M, Cutrone C, et al. Treatment of congenital subglottic hemangiomas: our experience compared with reports in the literature. Arch Otolaryngol Head Neck Surg. 2008 Aug;134(8):848-51. PMID: 18711059; X-3, X-4

2495. Saxena AK, Willital GH. Infrared thermography: experience from a decade of pediatric imaging. Eur J Pediatr. 2008 Jul;167(7):757-64. PMID: 17762940; X-3, X-4

2496. Sayed W, Hellal Y, Kaabar N, et al. Sternal cleft, a rare congenital anomaly. Report of the first Tunisian case. Tunis Med. 2008 Dec;86(12):1082-5. PMID: 19213519; X-1, X-2

2497. Serena T. Wound closure and gradual involution of an infantile hemangioma using a noncontact, low-frequency ultrasound therapy. Ostomy Wound Manage. 2008 Feb;54(2):68-71. PMID: 18401909; X-2

2498. Sharp L, Makin E, Davenport M. Hepatic haemangioendothelioma: a vertical association with biliary atresia? Eur J Pediatr Surg. 2008 Aug;18(4):277-9. PMID: 18629768; X-1

2499. Siegfried EC, Keenan WJ, Al-Jureidini S. More on propranolol for hemangiomas of infancy. N Engl J Med. 2008 Dec 25;359(26):2846; author reply -7. PMID: 19109584; X-1, X-2

2500. Song DK, Lonser RR. Pathological satiety caused by brainstem hemangioblastoma. J Neurosurg Pediatr. 2008 Dec;2(6):397-401. PMID: 19035684; X-1

2501. Sorteberg A, Bakke SJ, Boysen M, et al. Angiographic balloon test occlusion and therapeutic sacrifice of major arteries to the brain. Neurosurgery. 2008 Oct;63(4):651-60; dicussion 60-1. PMID: 18824944; X-1

2502. Spector JA, Blei F, Zide BM. Early surgical intervention for proliferating hemangiomas of the scalp: indications and outcomes. Plast Reconstr Surg. 2008 Aug;122(2):457-62. PMID: 18626361; X-3, X-4

2503. Stamataki S, Francis HW, Holliday M, et al. Histological features of osteofibrous hemangioma of the maxillofacial and skull base regions. Otolaryngol Head Neck Surg. 2008 May;138(5):587-93. PMID: 18439463; X-1

2504. Strenger V, Sovinz P, Lackner H, et al. Intracerebral cavernous hemangioma after cranial irradiation in childhood. Incidence and risk factors. Strahlenther Onkol. 2008 May;184(5):276-80. PMID: 18427759; X-1

2505. Sun ZY, Yi CG, Zhao H, et al. Infantile hemangioma is originated from placental trophoblast, fact or fiction? Med Hypotheses. 2008 Sep;71(3):444-8. PMID: 18440158; X-1

2506. Tang JY, Chen J, Pan C, et al. Diffuse cavernous hemangioma of the spleen with Kasabach-Merritt syndrome misdiagnosed as idiopathic thrombocytopenia in a child. World J Pediatr. 2008 Aug;4(3):227-30. PMID: 18822934; X-1

2507. Tolar J, Grewal SS, Bjoraker KJ, et al. Combination of enzyme replacement and hematopoietic stem cell transplantation as therapy for Hurler syndrome. Bone Marrow Transplant. 2008 Mar;41(6):531-5. PMID: 18037941; X-1

2508. Torre M, Rapuzzi G, Guida E, et al. Thymectomy to achieve primary closure of total sternal cleft. J Pediatr Surg. 2008 Dec;43(12):e17-20. PMID: 19040914; X-1

2509. Tronina SA, Bobrova NF, Khrinenko VP. Combined surgical method of orbital and periorbital hemangioma treatment in infants. Orbit. 2008;27(4):249-57. PMID: 18716962; X-1

2510. Uyama A, Kawamura A, Akiyama H, et al. A case of cerebellar capillary hemangioma with multiple cysts. Pediatr Neurosurg. 2008;44(4):344-9. PMID: 18552520; X-1, X-2

2511. Varoglu AO, Tan H, Onbas O, et al. Intramedullary angioma with bilateral arm hypothermia. Br J Neurosurg. 2008 Oct;22(5):687-9. PMID: 19016121; X-1

2512. Vasilescu C, Stanciulea O, Popa M, et al. Subtotal laparoscopic splenectomy and esophagogastric devascularization for the thrombocytopenia because of portal cavernoma--case report. J Pediatr Surg. 2008 Jul;43(7):1373-5. PMID: 18639700; X-1

2513. Vasilevska V, Kirjas N, Zafirovski G, et al. Imaging of musculoskeletal soft-tissue vascular anomalies. Rentgenologiya i Radiologiya. 2008;47(1):42-8. PMID: 2008460568; X-5

2514. Verity DH, Rose GE, Restori M. The effect of intralesional steroid injections on the volume and blood flow in periocular capillary haemangiomas. Orbit. 2008;27(1):41-7. PMID: 18307146; X-3, X-4

2515. Vetter-Kauczok CS, Strobel P, Brocker EB, et al. Kaposiform hemangioendothelioma with distant lymphangiomatosis without an association to Kasabach-Merritt-Syndrome in a female adult! Vasc Health Risk Manag. 2008;4(1):263-6. PMID: 18629354; X-1

2516. Vineberg S, Kossoff EH. Puzzler. Don't cry over spilled ... wine? A baby with a post-traumatic seizure. Contemp Pediatr. 2008;25(10):24-, 5-7, 32 passim. PMID: X-1

2517. Walner DL, Parker NP, Kim OS, et al. Lobular capillary hemangioma of the neonatal larynx. Arch Otolaryngol Head Neck Surg. 2008 Mar;134(3):272-7. PMID: 18347252; X-1

2518. Walsh MA, Carcao M, Pope E, et al. Kaposiform hemangioendothelioma presenting antenatally with a pericardial effusion. J Pediatr Hematol Oncol. 2008 Oct;30(10):761-3. PMID: 19011475; X-1

2519. Waner M, Kastenbaum J, Scherer K. Hemangiomas of the nose: surgical management using a modified subunit approach. Arch Facial Plast Surg. 2008 Sep-Oct;10(5):329-34. PMID: 18794411; X-3, X-4

2520. Wang C. Spinal hemangioblastoma: report on 68 cases. Neurol Res. 2008 Jul;30(6):603-9. PMID: 18647501; X-1

2521. Wasong SJ, Klepeiss SA, Zaenglein AL. Picture of the month. Ulcerated infantile hemangioma. Arch Pediatr Adolesc Med. 2008 Sep;162(9):893-4. PMID: 18762610; X-2

2522. Weinbreck N, Marie B, Bressenot A, et al. Immunohistochemical markers to distinguish between hemangioblastoma and metastatic clear-cell renal cell carcinoma in the brain: utility of aquaporin1 combined with cytokeratin AE1/AE3 immunostaining. Am J Surg Pathol. 2008 Jul;32(7):1051-9. PMID: 18496143; X-1

2523. Weiss AH, Kelly JP. Reappraisal of astigmatism induced by periocular capillary hemangioma and treatment with intralesional corticosteroid injection. Ophthalmology. 2008 Feb;115(2):390-7.e1. PMID: 17588666; X-4

2524. Weiss E, Sukal SA, Zimbler MS, et al. Basal cell carcinoma arising 57 years after interstitial radiotherapy of a nasal hemangioma. Dermatol Surg. 2008 Aug;34(8):1137-40. PMID: 18513300; X-1, X-2

2525. Wong WT, Agron E, Coleman HR, et al. Clinical characterization of retinal capillary hemangioblastomas in a large population of patients with von Hippel-Lindau disease. Ophthalmology. 2008 Jan;115(1):181-8. PMID: 17543389; X-1

2526. Wu PA, Mancini AJ, Marghoob AA, et al. Simultaneous occurrence of infantile hemangioma and congenital melanocytic nevus: Coincidence or real association? J Am Acad Dermatol. 2008 Feb;58(2 Suppl):S16-22. PMID: 18191691; X-3

2527. Yan AC. Pain management for ulcerated hemangiomas. Pediatr Dermatol. 2008 Nov-Dec;25(6):586-9. PMID: 19067860; X-1, X-2

2528. Yang Y, Sun M, Hou R, et al. Preliminary study of fibrin glue combined with pingyangmycin for the treatment of venous malformations in the oral and maxillofacial region. J Oral Maxillofac Surg. 2008 Nov;66(11):2219-25. PMID: 18940483; X-1

2529. Yarlagadda R, Menda Y, Graham MM. Tc-99m red blood cell imaging in a patient with blue rubber bleb nevus syndrome. Clin Nucl Med. 2008 May;33(5):374-6. PMID: 18431163; X-1

2530. Yarmel D, Dormans JP, Pawel BR, et al. Recurrent pedal hobnail (Dabska-retiform) hemangioendothelioma with forefoot reconstructive surgery using a digital fillet flap. J Foot Ankle Surg. 2008 Sep-Oct;47(5):487-93. PMID: 18725133; X-1

2531. Yigiter M, Arda IS, Hicsonmez A. An unusual cause of paraphimosis: hemangioma of the glans penis. J Pediatr Surg. 2008 Feb;43(2):e31-3. PMID: 18280267; X-1, X-2

2532. Yu JE, Pai KS, Park MS. Congenital cavernous hemangioma exhibiting subcutaneous fat necrosis. Clin Pediatr (Phila). 2008 Jan;47(1):74-6. PMID: 17766582; X-1

2533. Yun TJ, Na DG, Kwon BJ, et al. A T1 hyperintense perilesional signal aids in the differentiation of a cavernous angioma from other hemorrhagic masses. AJNR Am J Neuroradiol. 2008 Mar;29(3):494-500. PMID: 18039756; X-1

2534. Zhang GY, Yi CG, Li X, et al. Proliferation hemangiomas formation through dual mechanism of vascular endothelial growth factor mediated endothelial progenitor cells proliferation and mobilization through matrix metalloproteinases 9. Med Hypotheses. 2008;70(4):815-8. PMID: 17888584; X-1

2535. . CME posttest. JAAPA. 2009;22(5):50-. PMID: X-1

2536. Acciarri N, Galassi E, Giulioni M, et al. Cavernous malformations of the central nervous system in the pediatric age group. Pediatr Neurosurg. 2009;45(2):81-104. PMID: 19307743; X-1

2537. Acebo E, Gardeazabal J, Gonzalez-Hermosa R, et al. Congenital hemangioma: a report of evolution from rapidly involuting to noninvoluting congenital hemangioma with aberrant Mongolian spots. Pediatr Dermatol. 2009 Mar-Apr;26(2):225-6. PMID: 19419482; X-1

2538. Acioglu E, Cansiz H, Mercan H, et al. Head and neck hemangiopericytomas: diagnostic contradictions. J Craniofac Surg. 2009 May;20(3):930-5. PMID: 19461334; X-1

2539. Adams ME, Aylett SE, Squier W, et al. A spectrum of unusual neuroimaging findings in patients with suspected Sturge-Weber syndrome. AJNR Am J Neuroradiol. 2009 Feb;30(2):276-81. PMID: 19050205; X-1

2540. Agrawal A, Cincu R, Joharapurkar SR, et al. Hemorrhage in brain stem cavernoma presenting with torticollis. Pediatr Neurosurg. 2009;45(1):49-52. PMID: 19258729; X-1

2541. Alexiou GA, Mpairamidis E, Sfakianos G, et al. Surgical management of brain cavernomas in children. Pediatr Neurosurg. 2009;45(5):375-8. PMID: 19940535; X-1

2542. Al-Ghadeer H, Al-Rajhi A, Riley F. Episcleral hemangioma as an isolated finding. Eur J Ophthalmol. 2009 Mar-Apr;19(2):292-4. PMID: 19253250; X-1

2543. Al-Kaabi A, Yanofsky R, Bunge M, et al. Diffuse hemangiomatosis with predominant central nervous system involvement. Pediatr Neurol. 2009 Jan;40(1):54-7. PMID: 19068256; X-1, X-2

2544. Al-Mubarak L, Al-Khenaizan S. A wolf in sheep's disguise: rhabdomyosarcoma misdiagnosed as infantile hemangioma. J Cutan Med Surg. 2009 Sep-Oct;13(5):276-9. PMID: 19769838; X-1

2545. Al-Tonbary Y, Fouda A. Infantile hepatic hemangioendothelioma: an 8-month old infant successfully treated with a corticosteroid. Hematol Oncol Stem Cell Ther. 2009;2(3):422-5. PMID: 20139057; X-1, X-2

2546. Angiero F, Benedicenti S, Benedicenti A, et al. Head and neck hemangiomas in pediatric patients treated with endolesional 980-nm diode laser. Photomed Laser Surg. 2009 Aug;27(4):553-9. PMID: 19558311; X-3, X-4

2547. Badi AN, Kerschner JE, North PE, et al. Histopathologic and immunophenotypic profile of subglottic hemangioma: multicenter study. Int J Pediatr Otorhinolaryngol. 2009 Sep;73(9):1187-91. PMID: 19524305; X-1, X-2

2548. Barbagallo M, Ruggieri M, Incorpora G, et al. Infantile spasms in the setting of Sturge-Weber syndrome. Childs Nerv Syst. 2009 Jan;25(1):111-8. PMID: 18830609; X-1

2549. Barco D, Baselga E, Alegre M, et al. Successful treatment of eccrine angiomatous hamartoma with botulinum toxin. Arch Dermatol. 2009 Mar;145(3):241-3. PMID: 19289750; X-1

2550. Beck DO, Gosain AK. The presentation and management of hemangiomas. Plast Reconstr Surg. 2009 Jun;123(6):181e-91e. PMID: 19483535; X-1, X-2

2551. Benedetti E, Proietti A, Miccoli P, et al. Contrast-enhanced ultrasonography in nodular splenomegaly associated with type B Niemann-Pick disease: an atypical hemangioma enhancement pattern. J Ultrasound. 2009 September;12(3):85-92. PMID: 2009474893; X-1

2552. Bernotas G, Rastenyte D, Deltuva V, et al. Cavernous angiomas: an uncontrolled clinical study of 87 surgically treated patients. Medicina (Kaunas). 2009;45(1):21-8. PMID: 19223702; X-1

2553. Bigorre M, Van Kien AK, Valette H. Beta-blocking agent for treatment of infantile hemangioma. Plast Reconstr Surg. 2009 Jun;123(6):195e-6e. PMID: 19483538; X-3, X-4

2554. Bijarnia S, Shaw P, Vimpani A, et al. Combined enzyme replacement and haematopoietic stem cell transplantation in Hurler syndrome. J Paediatr Child Health. 2009 Jul-Aug;45(7-8):469-72. PMID: 19712183; X-1

2555. Bonifazi E, Milano A. Capillary angioma with findings of Masson's tumor. European Journal of Pediatric Dermatology. 2009 April-June;19(2):117. PMID: 2009569328; X-1

2556. Buckmiller L, Dyamenahalli U, Richter GT. Propranolol for airway hemangiomas: case report of novel treatment. Laryngoscope. 2009 Oct;119(10):2051-4. PMID: 19650125; X-2

2557. Buckmiller LM. Propranolol treatment for infantile hemangiomas. Curr Opin Otolaryngol Head Neck Surg. 2009 Dec;17(6):458-9. PMID: 19858718; X-1, X-2

2558. Bun YY, Ming CK, Ming CH, et al. Endovascular treatment of a neonate with dural arteriovenous fistula and other features suggestive of cerebrofacial arteriovenous metameric syndromes. Childs Nerv Syst. 2009 Mar;25(3):383-7. PMID: 19082615; X-1

2559. Burget GC. Preliminary review of pediatric nasal reconstruction with detailed report of one case. Plast Reconstr Surg. 2009 Sep;124(3):907-18. PMID: 19730311; X-1

2560. Cabrita SV, Goncalves S, Rodrigues H, et al. Antenatal diagnosis of congenital hepatic hemangioma: A case report. Cases Journal. 2009;2(8)PMID: 2010074406; X-1

2561. Cardinal J, de Vera ME, Marsh JW, et al. Treatment of hepatic epithelioid hemangioendothelioma: a single-institution experience with 25 cases. Arch Surg. 2009 Nov;144(11):1035-9. PMID: 19917940; X-1

2562. Cernik C, Channaiah D, Trevino J. Angiomatoid fibrous histiocytoma in a six-year-old child. Pediatr Dermatol. 2009 Sep-Oct;26(5):636-8. PMID: 19840338; X-1

2563. Chao YH, Liang DC, Chen SH, et al. Interferon-alpha for alarming hemangiomas in infants: experience of a single institution. Pediatr Int. 2009 Aug;51(4):469-73. PMID: 19400814; X-4

2564. Chen L, Zhao Y, Chen Z, et al. Multiple dynamic cavernous malformations in a girl: long-term follow-up. Surg Neurol. 2009 Dec;72(6):728-32. PMID: 19604555; X-1

2565. Chen YJ, Wang CK, Tien YC, et al. MRI of multifocal kaposiform haemangioendothelioma without Kasabach-Merritt phenomenon. Br J Radiol. 2009 Mar;82(975):e51-4. PMID: 19211904; X-1

2566. Chiou HJ, Chou YH, Chiu SY, et al. Differentiation of benign and malignant superficial soft-tissue masses using grayscale and color doppler ultrasonography. J Chin Med Assoc. 2009 Jun;72(6):307-15. PMID: 19541566; X-1

2567. Cho WS, Kim SK, Park SH, et al. Intracranial kaposiform hemangioendothelioma: proposal of a new malignant variant. J Neurosurg Pediatr. 2009 Feb;3(2):147-50. PMID: 19278316; X-1

2568. Cole P, Kaufman Y, Metry D, et al. Non-involuting congenital haemangioma associated with high-output cardiomyopathy. J Plast Reconstr Aesthet Surg. 2009 Oct;62(10):e379-82. PMID: 19195949; X-1

2569. Connelly EA, Viera M, Price C, et al. Segmental hemangioma of infancy complicated by life-threatening arterial bleed. Pediatr Dermatol. 2009 Jul-Aug;26(4):469-72. PMID: 19689527; X-2

2570. das Chagas MS, Pinheiro Rdos S, Janini ME, et al. Pyogenic granuloma: lobular capillary hemangioma in the upper lip of a 24-month-old child: case report. J Dent Child (Chic). 2009 Sep-Dec;76(3):237-40. PMID: 19941768; X-1, X-2

2571. Dashti SR, Fiorella D, Spetzler RF, et al. Preoperative Onyx embolization of a giant cavernous malformation involving the dural sinuses. J Neurosurg Pediatr. 2009 Apr;3(4):302-6. PMID: 19338408; X-1

2572. Degerliyurt A, Kantar A, Ceylaner S, et al. Hypomelanosis of Ito and Sturge-Weber syndrome without facial nevus: an association or a new syndrome? Pediatr Neurol. 2009 May;40(5):395-7. PMID: 19380080; X-1

2573. Demirci H, Shields CL, Eagle RC, Jr., et al. Giant cell angiofibroma, a variant of solitary fibrous tumor, of the orbit in a 16-year-old girl. Ophthal Plast Reconstr Surg. 2009 Sep-Oct;25(5):402-4. PMID: 19966660; X-1

2574. Denoyelle F, Leboulanger N, Enjolras O, et al. Role of Propranolol in the therapeutic strategy of infantile laryngotracheal hemangioma. Int J Pediatr Otorhinolaryngol. 2009 Aug;73(8):1168-72. PMID: 19481268; X-3, X-4

2575. Dickie B, Dasgupta R, Nair R, et al. Spectrum of hepatic hemangiomas: management and outcome. J Pediatr Surg. 2009 Jan;44(1):125-33. PMID: 19159729; X-3, X-4

2576. Disma N, Tuo P, Pellegrino S, et al. Three concentrations of levobupivacaine for ilioinguinal/iliohypogastric nerve block in ambulatory pediatric surgery. J Clin Anesth. 2009 Sep;21(6):389-93. PMID: 19833270; X-1

2577. Dong KR, Zheng S, Xiao X. Conservative management of neonatal hepatic hemangioma: a report from one institute. Pediatr Surg Int. 2009 Jun;25(6):493-8. PMID: 19415303; X-3, X-4

2578. Drucker AM, Pope E, Mahant S, et al. Vincristine and corticosteroids as first-line treatment of Kasabach-Merritt syndrome in kaposiform hemangioendothelioma. J Cutan Med Surg. 2009 May-Jun;13(3):155-9. PMID: 19426625; X-1

2579. Dueas-Arias JE, Armbula-Meraz E, Frias-Castro LO, et al. Tetralogy of Fallot associated with macrocephaly-capillary malformation syndrome: A case report and review of the literature. J Med Case Rep. 2009;3(9215)PMID: 2010020224; X-1

2580. Earl JB, Kramm L, Durairaj VD. Benign hamartoma masquerading as a deep orbital hemangioma. J Pediatr Ophthalmol Strabismus. 2009 Jul-Aug;46(4):228-31. PMID: 19645403; X-1, X-2

2581. Eidemuller M, Holmberg E, Jacob P, et al. Breast cancer risk among Swedish hemangioma patients and possible consequences of radiation-induced genomic instability. Mutat Res. 2009 Oct 2;669(1-2):48-55. PMID: 19416732; X-3, X-4

2582. Evagelidou E, Tsanou E, Asproudis I, et al. Orbital cavernous hemangioma in an infant with intracranial lesions: A case report. Cases Journal. 2009 September;2(9)PMID: 2010106097; X-1

2583. Fiorillo A, DeRosa G, Giugliano F, et al. Efficacy of pegylated lyposomal anthracyclines and of intra-arterial carboplatin and doxorubicin combined with local hyperthermia in a case of malignant endovascular papillary angioendothelioma. Curr Drug Deliv. 2009 Jan;6(1):58-61. PMID: 19418956; X-1

2584. Ford S, Dosani M, Robinson AJ, et al. Defining the reliability of sonoanatomy identification by novices in ultrasound-guided pediatric ilioinguinal and iliohypogastric nerve blockade. Anesth Analg. 2009 Dec;109(6):1793-8. PMID: 19923504; X-1

2585. Frieden IJ, Drolet BA. Propranolol for infantile hemangiomas: promise, peril, pathogenesis. Pediatr Dermatol. 2009 Sep-Oct;26(5):642-4. PMID: 19840341; X-2

2586. Friling R, Axer-Siegel R, Ben-Amitai D, et al. Intralesional and sub-Tenon's infusion of corticosteroids for treatment of refractory periorbital and orbital capillary haemangioma. Eye (Lond). 2009 Jun;23(6):1302-7. PMID: 18989344; X-3, X-4

2587. Garces-Ambrossi GL, McGirt MJ, Mehta VA, et al. Factors associated with progression-free survival and long-term neurological outcome after resection of intramedullary spinal cord tumors: analysis of 101 consecutive cases. J Neurosurg Spine. 2009 Nov;11(5):591-9. PMID: 19929363; X-1

2588. Garg R, Gupta N, Sharma A, et al. Acquired capillary hemangioma of the eyelid in a child. J Pediatr Ophthalmol Strabismus. 2009 Mar-Apr;46(2):118-9. PMID: 19343976; X-2

2589. Geramizadeh B, Banani A, Foroutan H, et al. Malignant epithelioid hemangioendothelioma of the bladder: the first case report in a child. J Pediatr Surg. 2009 Jul;44(7):1443-5. PMID: 19573676; X-1

2590. Good WV, Hou C, Frieden IJ, et al. Evidence for visual compromise in preverbal children with orbital vascular birthmarks. Am J Ophthalmol. 2009 Apr;147(4):679-82.e1. PMID: 19195640; X-3, X-4

2591. Gosain AK, Zochowski CG, Cortes W. Refinements of tissue expansion for pediatric forehead reconstruction: a 13-year experience. Plast Reconstr Surg. 2009 Nov;124(5):1559-70. PMID: 20009842; X-1

2592. Grabhorn E, Richter A, Fischer L, et al. Neonates with severe infantile hepatic hemangioendothelioma: limitations of liver transplantation. Pediatr Transplant. 2009 Aug;13(5):560-4. PMID: 18992050; X-1

2593. Green H. Intonation in Hebrew-speaking children with high functioning autism. Asia Pac J Speech Lang Hear. 2009;12(2):187-98. PMID: X-1

2594. Gucev ZS, Pop-Jordanova N, Dumalovska G, et al. Arthrogryposis multiplex congenital (AMC) in a three year old boy: Differential diagnosis with distal arthrogryposis: A case report. Cases Journal. 2009 December;2(12)PMID: 2010090231; X-1

2595. Gunduz K, Kurt RA, Erden E. Well-circumscribed orbital venous-lymphatic malformations with atypical features in children. Br J Ophthalmol. 2009 May;93(5):656-9. PMID: 19074919; X-1

2596. Habibi S, Agrawal S, Kadel JK, et al. Post-traumatic capillary hemangiomas: a rare cause of hand nodules. Clin Rheumatol. 2009 Jun;28 Suppl 1:S51-2. PMID: 19255719; X-1

2597. Haddy N, Andriamboavonjy T, Paoletti C, et al. Thyroid adenomas and carcinomas following radiotherapy for a hemangioma during infancy. Radiother Oncol. 2009 Nov;93(2):377-82. PMID: 19515442; X-1, X-3

2598. Hale TS, Loo SK, Zaidel E, et al. Rethinking a right hemisphere deficit in ADHD. J Atten Disord. 2009 Jul;13(1):3-17. PMID: 18753404; X-1

2599. Hansen LF, Wewer V, Pedersen SA, et al. Severe blue rubber bleb nevus syndrome in a neonate. Eur J Pediatr Surg. 2009 Feb;19(1):47-9. PMID: 18629772; X-1

2600. Hara K, Yoshida T, Kajiume T, et al. Successful treatment of Kasabach-Merritt syndrome with vincristine and diagnosis of the hemangioma using three-dimensional imaging. Pediatr Hematol Oncol. 2009 Jul-Aug;26(5):375-80. PMID: 19579084; X-1, X-2

2601. Hartman KR, Moncur JT, Minniti CP, et al. Mediastinal Kaposiform hemangioendothelioma and Kasabach-Merritt phenomenon in an infant: treatment with interferon. J Pediatr Hematol Oncol. 2009 Sep;31(9):690-2. PMID: 19687760; X-1

2602. Hauck EF, Barnett SL, White JA, et al. Symptomatic brainstem cavernomas. Neurosurgery. 2009 Jan;64(1):61-70; discussion -1. PMID: 19050659; X-1

2603. Hermans DJ, Boezeman JB, Van de Kerkhof PC, et al. Differences between ulcerated and non-ulcerated hemangiomas, a retrospective study of 465 cases. Eur J Dermatol. 2009 Mar-Apr;19(2):152-6. PMID: 19106042; X-3

2604. Highton LR, Pay AD. An unusual midline nasal mass in a newborn. J Plast Reconstr Aesthet Surg. 2009 May;62(5):695-6. PMID: 18502194; X-1

2605. Hoeger PH, Maerker JM, Kienast AK, et al. Neonatal haemangiomatosis associated with placental chorioangiomas: report of three cases and review of the literature. Clin Exp Dermatol. 2009 Jul;34(5):e78-80. PMID: 19438546; X-1

2606. Holmes LB. Chorionic villus sampling and hemangiomas. J Craniofac Surg. 2009 Mar;20 Suppl 1:675-7. PMID: 19218861; X-1, X-2

2607. Holzapfel BM, Geitner U, Diebold J, et al. Synovial hemangioma of the knee joint with cystic invasion of the femur: a case report and review of the literature. Arch Orthop Trauma Surg. 2009 Feb;129(2):143-8. PMID: 18758797; X-1

2608. Hoornweg MJ, Grootenhuis MA, van der Horst CM. Health-related quality of life and impact of haemangiomas on children and their parents. J Plast Reconstr Aesthet Surg. 2009 Oct;62(10):1265-71. PMID: 18602360; X-3, X-4

2609. Houston SK, Bourne TD, Lopes MB, et al. Bilateral massive retinal gliosis associated with retinopathy of prematurity. Arch Pathol Lab Med. 2009 Aug;133(8):1242-5. PMID: 19653718; X-1

2610. Iriz A, Durmaz E, Akmansu SH, et al. Vocal cord hemangioma; A rare localization in adults. Turkish Journal of Medical Sciences. 2009 April;39(2):305-7. PMID: 2009195892; X-1

2611. Iwai Y, Yamanaka K. Gamma knife radiosurgery for other primary intra-axial tumors. Prog Neurol Surg. 2009;22:129-41. PMID: 18948725; X-1

2612. Jackson MG, Simms-Cendan J, Sims SM, et al. Vaginal bleeding due to an infantile hemangioma in a 3-year-old girl. J Pediatr Adolesc Gynecol. 2009 Aug;22(4):e53-5. PMID: 19493519; X-2

2613. Jephson CG, Manunza F, Syed S, et al. Successful treatment of isolated subglottic haemangioma with propranolol alone. Int J Pediatr Otorhinolaryngol. 2009 Dec;73(12):1821-3. PMID: 19796830; X-1, X-2

2614. Jerjes W, Upile T, Vincent A, et al. Management of deep-seated malformations with photodynamic therapy: a new guiding imaging modality. Lasers Med Sci. 2009 Sep;24(5):769-75. PMID: 19377913; X-1

2615. Joe KJ, Huitron SS, Crawford JJ, et al. Idiopathic equinocavovarus foot deformity in an 8-year-old girl. Clin Orthop Relat Res. 2009 Sep;467(9):2482-6. PMID: 19198964; X-1

2616. Johnson O. Splenectomy: experience from Tikur Anbessa Hospital, Addis Ababa 1988-2007. Ethiop Med J. 2009 Jan;47(2):165-9. PMID: 19743797; X-1

2617. Kalane U, Kulkarni S. A case of neurocutaneous syndrome associated with facial hemangioma: PHACE syndrome. J Pediatr Neurol. 2009;7(3):325-7. PMID: 2009387467; X-2

2618. Kleaveland B, Zheng X, Liu JJ, et al. Regulation of cardiovascular development and integrity by the heart of glass-cerebral cavernous malformation protein pathway. Nat Med. 2009 Feb;15(2):169-76. PMID: 19151727; X-1

2619. Koh C, Sugo E, Wargon O. Unusual presentation of GLUT-1 positive infantile haemangioma. Australas J Dermatol. 2009 May;50(2):136-40. PMID: 19397570; X-2

2620. Kossoff EH, Ferenc L, Comi AM. An infantile-onset, severe, yet sporadic seizure pattern is common in Sturge-Weber syndrome. Epilepsia. 2009 Sep;50(9):2154-7. PMID: 19389148; X-1

2621. Ksendzovsky A, Glick R, Utset M, et al. A rare case of hemangioma of infancy presenting as intraspinal hemorrhage. J Neurosurg Pediatr. 2009 May;3(5):429-34. PMID: 19409024; X-2

2622. Laubach HJ, Anderson RR, Luger T, et al. Fractional photothermolysis for involuted infantile hemangioma. Arch Dermatol. 2009 Jul;145(7):748-50. PMID: 19620554; X-2

2623. Lawley LP, Siegfried E, Todd JL. Propranolol treatment for hemangioma of infancy: risks and recommendations. Pediatr Dermatol. 2009 Sep-Oct;26(5):610-4. PMID: 19840322; X-2

2624. Leong E, Bydder S. Use of radiotherapy to treat life-threatening Kasabach-Merritt syndrome. J Med Imaging Radiat Oncol. 2009 Feb;53(1):87-91. PMID: 19453533; X-1

2625. Lisle JW, Bradeen HA, Kalof AN. Kaposiform hemangioendothelioma in multiple spinal levels without skin changes. Clin Orthop Relat Res. 2009 Sep;467(9):2464-71. PMID: 19381744; X-1

2626. Liu FH, Hsueh C, Chao TC, et al. Neck nodule and thyroid cancer in young without radiation exposure history. Pediatr Surg Int. 2009 Sep;25(9):785-8. PMID: 19629501; X-1

2627. Liu XJ, Qin ZP, Tai MZ. Angiographic classification and sclerotic therapy of maxillofacial cavernous haemangiomas: a report of 204 cases. J Int Med Res. 2009 Sep-Oct;37(5):1285-92. PMID: 19930833; X-1

2628. Liu Y, Jiao P, Tan X, et al. Reconstruction of facial defects using prefabricated expanded flaps carried by temporoparietal fascia flaps. Plast Reconstr Surg. 2009 Feb;123(2):556-61. PMID: 19182613; X-1

2629. Lobo-Mueller E, Amaral JG, Babyn PS, et al. Extremity vascular anomalies in children: introduction, classification, and imaging. Semin Musculoskelet Radiol. 2009 Sep;13(3):210-35. PMID: 19724991; X-1, X-2

2630. Lomenick JP, Reifschneider KL, Lucky AW, et al. Prevalence of adrenal insufficiency following systemic glucocorticoid therapy in infants with hemangiomas. Arch Dermatol. 2009 Mar;145(3):262-6. PMID: 19289754; X-3, X-4

2631. Lonser RR, Butman JA, Kiringoda R, et al. Pituitary stalk hemangioblastomas in von Hippel-Lindau disease. J Neurosurg. 2009 Feb;110(2):350-3. PMID: 18834262; X-1

2632. Lopez V, Marti N, Pereda C, et al. Successful management of Kaposiform hemangioendothelioma with Kasabach-Merritt phenomenon using vincristine and ticlopidine. Pediatr Dermatol. 2009 May-Jun;26(3):365-6. PMID: 19706115; X-1

2633. Madan V, Lloyd IC, Wakefield RM, et al. PHACE syndrome. Clin Exp Dermatol. 2009 Jul;34(5):651-2. PMID: 19508485; X-2

2634. Madhusudhan KS, Sharma R, Kandpal H, et al. A rare case of combined soft-tissue and intraosseous arteriovenous malformation of the hand with diffuse periosteal elevation: imaging appearances. Br J Radiol. 2009 Nov;82(983):e219-24. PMID: 19890114; X-1

2635. Maguiness SM, Frieden IJ. Infantile hemangiomas: a look back and future directions. Actas Dermosifiliogr. 2009 Nov;100 Suppl 1:73-6. PMID: 20096199; X-1, X-2

2636. Markiewicz-Kijewska M, Kasprzyk W, Broniszczak D, et al. Hemodynamic failure as an indication to urgent liver transplantation in infants with giant hepatic hemangiomas or vascular malformations--report of four cases. Pediatr Transplant. 2009 Nov;13(7):906-12. PMID: 18992048; X-1

2637. Matsuyama Y, Sakai Y, Katayama Y, et al. Surgical results of intramedullary spinal cord tumor with spinal cord monitoring to guide extent of resection. J Neurosurg Spine. 2009 May;10(5):404-13. PMID: 19442001; X-1

2638. McCuaig CC, Dubois J, Powell J, et al. A phase II, open-label study of the efficacy and safety of imiquimod in the treatment of superficial and mixed infantile hemangioma. Pediatr Dermatol. 2009 Mar-Apr;26(2):203-12. PMID: 19419474; X-4

2639. Meijer-Jorna LB, Breugem CC, de Boer OJ, et al. Presence of a distinct neural component in congenital vascular malformations relates to the histological type and location of the lesion. Hum Pathol. 2009 Oct;40(10):1467-73. PMID: 19454356; X-1

2640. Mendez-Gallart R, Tellado MG, Del Pozo-Losada J, et al. A rapid onset erythematous facial lesion in a neonatal patient. Pediatr Dermatol. 2009 Mar-Apr;26(2):195-6. PMID: 19419472; X-1, X-2

2641. Moghimi M, Ben Razavi S, Akhavan A, et al. Hobnail hemangioendothelioma (Dabska type) in the right thigh. Eur J Pediatr Surg. 2009 Oct;19(5):337-9. PMID: 19431104; X-1

2642. Mohamed AM, Elwakil TF, Taher IM, et al. Cyclin D1 gene amplification in proliferating haemangioma. Cell Tissue Res. 2009 Oct;338(1):107-15. PMID: 19823825; X-1, X-3

2643. Moler FW, Meert K, Donaldson AE, et al. In-hospital versus out-of-hospital pediatric cardiac arrest: a multicenter cohort study. Crit Care Med. 2009 Jul;37(7):2259-67. PMID: 19455024; X-1

2644. Moon SB, Kwon HJ, Park KW, et al. Clinical experience with infantile hepatic hemangioendothelioma. World J Surg. 2009 Mar;33(3):597-602. PMID: 19132441; X-1

2645. Murthy R, Honavar SG. Secondary vasoproliferative retinal tumor associated with Usher syndrome type 1. J aapos. 2009 Feb;13(1):97-8. PMID: 19022692; X-1

2646. Murthy R, Naik MN, Desai S, et al. PHACE syndrome associated with congenital oculomotor nerve palsy. Strabismus. 2009 Apr-Jun;17(2):75-7. PMID: 19551563; X-2

2647. Nielsen GP, Srivastava A, Kattapuram S, et al. Epithelioid hemangioma of bone revisited: a study of 50 cases. Am J Surg Pathol. 2009 Feb;33(2):270-7. PMID: 18852673; X-1

2648. O TM, Alexander RE, Lando T, et al. Segmental hemangiomas of the upper airway. Laryngoscope. 2009 Nov;119(11):2242-7. PMID: 19806648; X-3, X-4

2649. Oliveira AC, de Moraes Ramos FM, Jeunon FA, et al. Central haemangioma of the mandible in a 7-year old child. Int J Paediatr Dent. 2009 May;19(3):216-8. PMID: 18489573; X-2

2650. Ooi KG, Wenderoth JD, Francis IC, et al. Selective embolization and resection of a large noninvoluting congenital hemangioma of the lower eyelid. Ophthal Plast Reconstr Surg. 2009 Mar-Apr;25(2):111-4. PMID: 19300152; X-1

2651. O'Regan GM, Irvine AD, Yao N, et al. Mediastinal and neck kaposiform hemangioendothelioma: report of three cases. Pediatr Dermatol. 2009 May-Jun;26(3):331-7. PMID: 19706099; X-1

2652. Palmero ML, Pope E. Eruptive pyogenic granulomas developing after drug hypersensitivity reaction. J Am Acad Dermatol. 2009 May;60(5):855-7. PMID: 19211171; X-1, X-2

2653. Pandey A, Gangopadhyay AN, Sharma SP, et al. Conservative management of ulcerated haemangioma--twenty years experience. Int Wound J. 2009 Feb;6(1):59-62. PMID: 19291117; X-3, X-4

2654. Pang WB, Zhang TC, Chen YJ, et al. Space-occupying benign lesions in spleen: experiences in a single institute. Pediatr Surg Int. 2009 Jan;25(1):31-5. PMID: 18956203; X-1

2655. Pascual-Castroviejo I, Viano J, Pascual-Pascual SI, et al. Congenital and evolving vascular disorders associated with cutaneous hemangiomas: case report. Neuropediatrics. 2009 Jun;40(3):148-51. PMID: 20020403; X-2

2656. Peker E, Kirimi E, Tuncer O, et al. Brachial plexus paralysis due to giant cavernous hemangioma with Kasabach-Merritt syndrome: successful management with interferon alpha. Platelets. 2009 Dec;20(8):603-5. PMID: 19929246; X-1

2657. Perkins JA, Chen EY, Hoffer FA, et al. Proposal for staging airway hemangiomas. Otolaryngol Head Neck Surg. 2009 Oct;141(4):516-21. PMID: 19786222; X-3, X-4

2658. Perkins JA, Duke W, Chen E, et al. Emerging concepts in airway infantile hemangioma assessment and management. Otolaryngol Head Neck Surg. 2009 Aug;141(2):207-12. PMID: 19643253; X-4

2659. Perkins JA, Oliaei S, Garrison MM, et al. Airway procedures and hemangiomas: treatment patterns and outcome in U.S. pediatric hospitals. Int J Pediatr Otorhinolaryngol. 2009 Sep;73(9):1302-7. PMID: 19592117; X-3, X-4

2660. Petroianu A, Teixeira BC, de Alencar LF. Partial splenectomy for treatment of splenic hemangioma. Chirurgia (Bucur). 2009 Jul-Aug;104(4):483-6. PMID: 19886058; X-1

2661. Peyre M, Di Rocco F, Varlet P, et al. Supratentorial hemangioblastoma in the neonatal period. Pediatr Neurosurg. 2009;45(2):155-6. PMID: 19321952; X-1

2662. Pitt C, Lavery C, Wager N. Psychosocial outcomes of bone marrow transplant for individuals affected by Mucopolysaccharidosis I Hurler Disease: patient social competency. Child Care Health Dev. 2009 Mar;35(2):271-80. PMID: 19228160; X-1

2663. Pitta GBB, Gomes RR. Treatment of ulcerated hemangioma: Case report. Jornal Vascular Brasileiro. 2009;8(3)PMID: 2010146595; X-2

2664. Praveen V, Vidavalur R, Rosenkrantz TS, et al. Infantile hemangiomas and retinopathy of prematurity: possible association. Pediatrics. 2009 Mar;123(3):e484-9. PMID: 19221153; X-3

2665. Rai P, Shah SIS, Narsani AK, et al. Analysis of primary benign orbital lesions. Int J Ophthalmol. 2009 25 Apr;9(4):634-41. PMID: 2009221056; X-5

2666. Ramantani G, Niggemann P, Hahn G, et al. Unusual radiological presentation of tuberous sclerosis complex with leptomeningeal angiomatosis associated with a hypomorphic mutation in the TSC2 gene. J Child Neurol. 2009 Mar;24(3):333-7. PMID: 19258292; X-1

2667. Ramesh R, De Silva B, Atherton DJ. Congenital tufted angioma with persistent low-grade coagulopathy. Clin Exp Dermatol. 2009 Dec;34(8):e766-8. PMID: 19778314; X-1

2668. Roganovic J, Adams D. PHACES syndrome--case report and literature review. Coll Antropol. 2009 Mar;33(1):311-4. PMID: 19408643; X-2

2669. Rudnick EF, Chen EY, Manning SC, et al. PHACES syndrome: otolaryngic considerations in recognition and management. Int J Pediatr Otorhinolaryngol. 2009 Feb;73(2):281-8. PMID: 19081148; X-3, X-4

2670. Sahiner UM, Senel S, Erkek N, et al. Rubinstein Taybi syndrome with hepatic hemangioma. Med Princ Pract. 2009;18(2):162-4. PMID: 19204439; X-2

2671. Saito M, Gunji Y, Kashii Y, et al. Refractory kaposiform hemangioendothelioma that expressed vascular endothelial growth factor receptor (VEGFR)-2 and VEGFR-3: a case report. J Pediatr Hematol Oncol. 2009 Mar;31(3):194-7. PMID: 19262246; X-1

2672. Sardi I, Sanzo M, Giordano F, et al. Monotherapy with thalidomide for treatment of spinal cord hemangioblastomas in a patient with von Hippel-Lindau disease. Pediatr Blood Cancer. 2009 Sep;53(3):464-7. PMID: 19415739; X-1

2673. Savino G, Aliberti S, Colucci D, et al. Atypical presentation of a case of solitary fibrous tumor of the orbit. Orbit. 2009;28(2-3):176-8. PMID: 19839906; X-1

2674. Schick U, Hassler W. Treatment of deep vascular orbital malformations. Clin Neurol Neurosurg. 2009 Dec;111(10):801-7. PMID: 19726125; X-1

2675. Schild C, Kayser G, Aschendorff A, et al. Pedunculated capillary hemangioma of the external ear. Otolaryngol Head Neck Surg. 2009 May;140(5):764-5. PMID: 19393427; X-1

2676. Schmitz R, Heinig J, Klockenbusch W, et al. Antenatal diagnosis of a giant fetal hepatic hemangioma and treatment with maternal corticosteroid. Ultraschall Med. 2009 Jun;30(3):223-6. PMID: 19507116; X-1, X-2

2677. Seitz K, Strobel D, Bernatik T, et al. Contrast-Enhanced Ultrasound (CEUS) for the characterization of focal liver lesions - prospective comparison in clinical practice: CEUS vs. CT (DEGUM multicenter trial). Parts of this manuscript were presented at the Ultrasound Dreilandertreffen 2008, Davos. Ultraschall Med. 2009 Aug;30(4):383-9. PMID: 19688670; X-4

2678. Shafqat G, Iqbal F, Rizvi F. Chorioangioma of the placenta with hydrops foetalis. J Pak Med Assoc. 2009 Jun;59(6):411-2. PMID: 19534382; X-1

2679. Sharan S, Swamy B, Taranath DA, et al. Port-wine vascular malformations and glaucoma risk in Sturge-Weber syndrome. J aapos. 2009 Aug;13(4):374-8. PMID: 19683189; X-1

2680. Sharma J, Hirata Y, Mosca RS. Surgical repair in neonatal life of cardiac haemangiomas diagnosed prenatally. Cardiol Young. 2009 Aug;19(4):403-6. PMID: 19442320; X-1

2681. Simic R, Vlahovic A, Subarevic V. Treatment of nasal hemangiomas. Int J Pediatr Otorhinolaryngol. 2009 Oct;73(10):1402-6. PMID: 19656579; X-3, X-4

2682. Sivasli E, Teksam O, Haliloglu M, et al. Hydrops fetalis associated with chorioangioma and thrombosis of umbilical vein. Turk J Pediatr. 2009 Sep-Oct;51(5):515-8. PMID: 20112613; X-1

2683. Song CE, Cho JH, Kim SY, et al. Endoscopic resection of haemangiomas in the sinonasal cavity. J Laryngol Otol. 2009 Aug;123(8):868-72. PMID: 19275780; X-1

2684. Stahr S, Green B, Woosely J, et al. An infant with an indurated patch on the leg. Pediatr Dermatol. 2009 May-Jun;26(3):347-8. PMID: 19706103; X-1

2685. Sugano H, Nakanishi H, Nakajima M, et al. Seizures continue even after prompt anti-epileptic drug medication in Sturge-Weber syndrome--study from prolonged video electrocoticography, a case report. Childs Nerv Syst. 2009 Jan;25(1):143-6. PMID: 18769930; X-1

2686. Summa A, Cerasti D, Crisi G, et al. Formation of intracerebral cavernous malformation after radiation treatment for medulloblastoma in a child. Neuroradiol J. 2009 April;22(2):198-203. PMID: 2009323268; X-1

2687. Sung KS, Seo SW, Shon MS. The diagnostic value of needle biopsy for musculoskeletal lesions. Int Orthop. 2009 Dec;33(6):1701-6. PMID: 19655141; X-1

2688. Thapa R, Ghosh A, Dhar S. Infantile giant congenital melanocytic nevus: report of three unusual cases. Int J Dermatol. 2009 Nov;48(11):1209-12. PMID: 20064178; X-1

2689. Turowski C, Feist H, Alzen G, et al. Conversion of a neonatal hepatic hemangioma to focal nodular hyperplasia. Pathol Int. 2009 Apr;59(4):251-4. PMID: 19351369; X-2

2690. Tyzio R, Khalilov I, Represa A, et al. Inhibitory actions of the gamma-aminobutyric acid in pediatric Sturge-Weber syndrome. Ann Neurol. 2009 Aug;66(2):209-18. PMID: 19743469; X-1

2691. Uchida Y, Takeda K, Tada K, et al. Multifocal haemangioma with extracutaneous involvement associated with hypergalactosaemia. Clin Exp Dermatol. 2009 Dec;34(8):e617-9. PMID: 19489861; X-2

2692. van der Meijs BB, Merks JH, de Haan TR, et al. Neonatal hepatic haemangioendothelioma: treatment options and dilemmas. Pediatr Radiol. 2009 Mar;39(3):277-81. PMID: 19083217; X-1

2693. Vartzelis G, Lancaster D, Fallon P. Intracranial hypertension in pediatric patients with acute lymphoblastic leukemia. Pediatr Blood Cancer. 2009 Mar;52(3):418-20. PMID: 19058211; X-1

2694. Vlahovic A, Simic R, Djokic D, et al. Diffuse neonatal hemangiomatosis treatment with cyclophosphamide: a case report. J Pediatr Hematol Oncol. 2009 Nov;31(11):858-60. PMID: 19829152; X-2

2695. Vural M, Acikalin MF, Adapinar B, et al. Congenital cavernous hemangioma of the calvaria. Case report. J Neurosurg Pediatr. 2009 Jan;3(1):41-5. PMID: 19119903; X-1

2696. Wakamoto H, Nakamura Y, Ebihara T, et al. Reversible coma associated with prolonged high-dose phenobarbital therapy in bilateral Sturge-Weber syndrome. J Child Neurol. 2009 Dec;24(12):1547-51. PMID: 19671890; X-1

2697. Wallen KE, Hadar EJ, Perry V, et al. Posterior fossa neoplasm and PHACES syndrome: a case report. J Pediatr Hematol Oncol. 2009 Mar;31(3):203-5. PMID: 19262249; X-2

2698. Wang J, Pei G, Yan J, et al. Coexistence of a giant splenic hemangioma and multiple hepatic hemangiomas mimicking a left adrenal neuroblastoma accompanied with multifocal hepatic metastases: pyrite answer. J Pediatr Hematol Oncol. 2009 Dec;31(12):983-4. PMID: 19935098; X-1, X-2

2699. Watanabe S, Takagi S, Sato Y, et al. Early surgical intervention for Japanese children with infantile hemangioma of the craniofacial region. J Craniofac Surg. 2009 Mar;20 Suppl 1:707-9. PMID: 19218860; X-3, X-4

2700. Wharton S, Soueid A, Nishikawa H, et al. Endangering cutaneous infantile hemangioma treated with vincristine: A case report. Eur J Plast Surg. 2009 June;32(3):157-61. PMID: X-2

2701. Wiegand S, Eivazi B, Karger R, et al. Surgery in patients with vascular malformations of the head and neck: value of coagulation disorders. Phlebology. 2009 Feb;24(1):38-42. PMID: 19155340; X-1

2702. Wolfe SQ, Farhat H, Elhammady MS, et al. Transarterial embolization of a scalp hemangioma presenting with Kasabach-Merritt syndrome. J Neurosurg Pediatr. 2009 Nov;4(5):453-7. PMID: 19877779; X-1

2703. Wootton-Gorges SL. MR imaging of primary bone tumors and tumor-like conditions in children. Radiol Clin North Am. 2009;47(6):957-75. PMID: X-1, X-2

2704. Wu G, Jones J, Sequeira IB, et al. Congenital pericardial hemangioma responding to high-dose corticosteroid therapy. Can J Cardiol. 2009 Apr;25(4):e139-40. PMID: 19340361; X-1

2705. Xia C, Zhang R, Mao Y, et al. Pediatric cavernous malformation in the central nervous system: report of 66 cases. Pediatr Neurosurg. 2009;45(2):105-13. PMID: 19307744; X-1

2706. Yamanaka G, Miyajima T, Kawashima H, et al. Effectiveness of intravenous immunoglobulin for epilepsy associated with Opitz trigonocephaly syndrome. Journal of Tokyo Medical University. 2009 January;67(1):71-4. PMID: 2009113377; X-1

2707. Yamashita Y, Kumabe T, Higano S, et al. Minimum apparent diffusion coefficient is significantly correlated with cellularity in medulloblastomas. Neurol Res. 2009 Nov;31(9):940-6. PMID: 19138469; X-1

2708. Yang HY, Zheng LW, Yang HJ, et al. Long-pulsed Nd: YAG laser treatment in vascular lesions of the oral cavity. J Craniofac Surg. 2009 Jul;20(4):1214-7. PMID: 19553836; X-3, X-4

2709. Yang Y, Sun M, Cheng X, et al. Bleomycin A5 plus dexamethasone for control of growth in infantile parotid hemangiomas. Oral Surg Oral Med Oral Pathol Oral Radiol Endod. 2009 Jul;108(1):62-9. PMID: 19451005; X-3, X-4

2710. Yaylali O, Kirac S, Acar M, et al. Diagnosis and follow-up of eyelid hemangioma with TC-99M RBC scintigraphy. Anatolian Journal of Clinical Investigation. 2009;3(3):185-9. PMID: 2009616570; X-2

2711. Yoon HS, Lee JH, Moon HN, et al. Successful treatment of retroperitoneal infantile hemangioendothelioma with Kasabach-Merritt syndrome using steroid, alpha-interferon, and vincristine. J Pediatr Hematol Oncol. 2009 Dec;31(12):952-4. PMID: 19875968; X-1

2712. Yu H, Qin A. Could local delivery of bisphosphonates be a new therapeutic choice for hemangiomas? Med Hypotheses. 2009 Oct;73(4):495-7. PMID: 19625131; X-2

2713. Zenzen W, Perez-Atayde AR, Elisofon SA, et al. Hepatic failure in a rapidly involuting congenital hemangioma of the liver: failure of embolotherapy. Pediatr Radiol. 2009 Oct;39(10):1118-23. PMID: 19588131; X-1, X-2

2714. Zhang W, He J, Wang J, et al. Ulcerated epithelioid hemangioendothelioma of the right armpit in childhood. J Pediatr Hematol Oncol. 2009 Aug;31(8):595-8. PMID: 19636267; X-1

2715. Ach T, Thiemeyer D, Hoeh AE, et al. Intravitreal bevacizumab for retinal capillary haemangioma: longterm results. Acta Ophthalmol. 2010 Jun;88(4):e137-8. PMID: 19681788; X-1, X-2

2716. Adeolu AA, Balogun JA, Adeleye AO, et al. Management of symptomatic vertebral haemangioma in a resource challenged environment. Childs Nerv Syst. 2010 Jul;26(7):979-82. PMID: 20217099; X-1

2717. Adi-Bensaid L, Ben-David A. Typical acquisition by atypical children: Initial consonant cluster acquisition by Israeli Hebrew-acquiring children with cochlear implants. Clin Linguist Phon. 2010 Oct;24(10):771-94. PMID: 20831377; X-1

2718. Agnese M, Cipolletta L, Bianco MA, et al. Blue rubber bleb nevus syndrome. Acta Paediatr. 2010 Apr;99(4):632-5. PMID: 19958301; X-1

2719. Aguilera D, Tomita T, Goldman S, et al. Incidental resolution of a radiation-induced cavernous hemangioma of the brain following the use of bevacizumab in a child with recurrent medulloblastoma. Pediatr Neurosurg. 2010;46(4):303-7. PMID: 21196797; X-1

2720. Ahsan U, Zaman T, Rashid T, et al. Cutaneous manifestations in 1000 Pakistani newborns. Journal of Pakistan Association of Dermatologists. 2010 October/December;20(4):199-205. PMID: 2011035544; X-1, X-2

2721. Alkonyi B, Chugani HT, Behen M, et al. The role of the thalamus in neuro-cognitive dysfunction in early unilateral hemispheric injury: a multimodality imaging study of children with Sturge-Weber syndrome. Eur J Paediatr Neurol. 2010 Sep;14(5):425-33. PMID: 20447845; X-1

2722. Alomari AK, Alomari AI. Picture of the month: kaposiform hemangioendothelioma with Kasabach-Merritt phenomenon. Arch Pediatr Adolesc Med. 2010 Apr;164(4):387, 8. PMID: 20368493; X-1

2723. Arneja JS, Chim H, Drolet BA, et al. The Cyrano nose: refinements in surgical technique and treatment approach to hemangiomas of the nasal tip. Plast Reconstr Surg. 2010 Oct;126(4):1291-9. PMID: 20885249; X-3, X-4

2724. Arneja JS, Pappas PN, Shwayder TA, et al. Management of complicated facial hemangiomas with beta-blocker (propranolol) therapy. Plast Reconstr Surg. 2010 Sep;126(3):889-95. PMID: 20811222; X-3, X-4

2725. Ashley RA, Figueroa TE. Gross hematuria in a 3-year-old girl caused by a large isolated bladder hemangioma. Urology. 2010 Oct;76(4):952-4. PMID: 20627282; X-1, X-2

2726. Avagyan AB, Sargsyan AL, Shahinyan AL. Neoplasms of the maxillo-facial region in children of various age groups. New Armenian Medical Journal. 2010 September;4 (3):39. PMID: 70707747; X-1, X-2

2727. Avila ED, Molon RS, Conte Neto N, et al. Lip cavernous hemangioma in a young child. Braz Dent J. 2010;21(4):370-4. PMID: 20976391; X-1

2728. Barcot Z, Zupancic B. Pulsed dye laser treatment of vascular lesions in childhood. Acta Dermatovenerol Croat. 2010;18(3):201-8. PMID: 20887704; X-1, X-2

2729. Bauland CG, Smit JM, Bartelink LR, et al. Hemangioma in the newborn: increased incidence after chorionic villus sampling. Prenat Diagn. 2010 Oct;30(10):913-7. PMID: 20824891; X-3

2730. Bechtel B, Hasson M. Depth of presentation in periocular hemangioma may be important clinical indicator. Ocular Surgery News. 2010;28(5):15-. PMID: X-2

2731. Benoit MM, Fink DS, Brigger MT, et al. Lobular capillary hemangioma of the nasal cavity in a five-year-old boy. Otolaryngol Head Neck Surg. 2010 Feb;142(2):290-1. PMID: 20115993; X-2

2732. Benoit MM, North PE, McKenna MJ, et al. Facial nerve hemangiomas: vascular tumors or malformations? Otolaryngol Head Neck Surg. 2010 Jan;142(1):108-14. PMID: 20096233; X-1

2733. Berlucchi M, Pedruzzi B, Farina D. Radiology quiz case 2. Lobular capillary hemangioma (LCH). Arch Otolaryngol Head Neck Surg. 2010 Nov;136(11):1141, 3. PMID: 21079173; X-1

2734. Bessho K, Etani Y, Ichimori H, et al. Increased type 3 iodothyronine deiodinase activity in a regrown hepatic hemangioma with consumptive hypothyroidism. Eur J Pediatr. 2010 Feb;169(2):215-21. PMID: 19548001; X-2

2735. Bien E, Kazanowska B, Dantonello T, et al. Factors predicting survival in childhood malignant and intermediate vascular tumors : retrospective analysis of the Polish and German cooperative paediatric soft tissue sarcoma study groups and review of the literature. Ann Surg Oncol. 2010 Jul;17(7):1878-89. PMID: 20333551; X-1

2736. Blanchet C, Nicollas R, Bigorre M, et al. Management of infantile subglottic hemangioma: acebutolol or propranolol? Int J Pediatr Otorhinolaryngol. 2010 Aug;74(8):959-61. PMID: 20557953; X-3, X-4

2737. Blatt J, Stavas J, Moats-Staats B, et al. Treatment of childhood kaposiform hemangioendothelioma with sirolimus. Pediatr Blood Cancer. 2010 Dec 15;55(7):1396-8. PMID: 20730884; X-1

2738. Bonaccorsi-Riani E, Lerut JP. Liver transplantation and vascular tumours. Transpl Int. 2010 Jul;23(7):686-91. PMID: 20492619; X-1

2739. Bonifazi E, Acquafredda A, Milano A, et al. Severe hypoglycemia during successful treatment of diffuse hemangiomatosis with propranolol. Pediatr Dermatol. 2010 Mar-Apr;27(2):195-6. PMID: 20537072; X-1

2740. Bonifazi E, Mazzotta F, Colonna V, et al. Topical propranolol in the superficial infantile hemangioma of the skin. European Journal of Pediatric Dermatology. 2010 October-December;20(4):247-51. PMID: 2011242089; X-3, X-4

2741. Boyce J, Dodge-Palomba S. Propranolol treatment in periocular pediatric patients with hemangiomas. Insight. 2010 Jan-Mar;35(1):22-3. PMID: 20218265; X-1, X-2

2742. Breugem SJM, Tytgat LGA, Schaap GR. Practical orthopaedic pathology. Epithelioid hemangioendothelioma of the upper thigh in a child. Curr Orthop Pract. 2010;21(5):518-20. PMID: X-1

2743. Buckmiller LM, Munson PD, Dyamenahalli U, et al. Propranolol for infantile hemangiomas: early experience at a tertiary vascular anomalies center. Laryngoscope. 2010 Apr;120(4):676-81. PMID: 20112413; X-4

2744. Canadas KT, Baum ED, Lee S, et al. Case report: Treatment failure using propanolol for treatment of focal subglottic hemangioma. Int J Pediatr Otorhinolaryngol. 2010 Aug;74(8):956-8. PMID: 20846505; X-2

2745. Cetinkaya S, Kendirci HN, Agladioglu SY, et al. Hypothyroidism due to hepatic hemangioendothelioma: a case report. J Clin Res Pediatr Endocrinol. 2010;2(3):126-30. PMID: 21274327; X-1, X-2

2746. Chan RV, Yonekawa Y, Lane AM, et al. Proton beam irradiation using a light-field technique for the treatment of choroidal hemangiomas. Ophthalmologica. 2010;224(4):209-16. PMID: 19940527; X-1

2747. Chang JJ, Lui TH. Intramuscular haemangioma of flexor digitorum brevis. Foot Ankle Surg. 2010 Jun;16(2):e8-11. PMID: 20483132; X-1

2748. Chang L, Mruthyunjaya P, Rodriguez-Rosa RE, et al. Postoperative cilioretinal artery occlusion in Sturge Weber-associated glaucoma. J aapos. 2010 Aug;14(4):358-60. PMID: 20621528; X-1

2749. Chee D, Phillips R, Maixner W, et al. The potential of capillary birthmarks as a significant marker for capillary malformation-arteriovenous malformation syndrome in children who had nontraumatic cerebral hemorrhage. J Pediatr Surg. 2010 Dec;45(12):2419-22. PMID: 21129558; X-1

2750. Cheng JF, Gole GA, Sullivan TJ. Propranolol in the management of periorbital infantile haemangioma. Clin Experiment Ophthalmol. 2010 Aug;38(6):547-53. PMID: 20553300; X-4

2751. Chik KK, Luk CK, Chan HB, et al. Use of propranolol in infantile haemangioma among Chinese children. Hong Kong Med J. 2010 Oct;16(5):341-6. PMID: 20889997; X-4

2752. Chukuezi AB, Nwosu JN. Pattern of nasal and paranasal sinus tumours in Owerri, Nigeria. Research Journal of Medical Sciences. 2010;4(1):11-4. PMID: 2010077098; X-1, X-2

2753. Consales A, Piatelli G, Ravegnani M, et al. Treatment and outcome of children with cerebral cavernomas: a survey on 32 patients. Neurol Sci. 2010 Apr;31(2):117-23. PMID: 19834644; X-1

2754. Cornips EM, Vinken PA, Ter Laak-Poort M, et al. Intramedullary cavernoma presenting with hematomyelia: report of two girls. Childs Nerv Syst. 2010 Mar;26(3):391-8. PMID: 19865818; X-1

2755. Crouch M. As they grow: 0-12 months. Taking care of it! Parents. 2010;85(7):152. PMID: X-1

2756. Cuccaro P, Rapacciuolo A, Vitiello R, et al. Infantile facial haemangioma and subclinical left ventricular dysfunction: the importance of z score in the diagnostic and therapeutic process. J Cardiovasc Med (Hagerstown). 2010 Sep;11(9):692-4. PMID: 20404742; X-1, X-2

2757. Da Ines D, Petitcolin V, Joubert-Zakeyh J, et al. Epithelioid hemangioendothelioma of the liver with metastatic coeliac lymph nodes in an 11-year-old boy. Pediatr Radiol. 2010 Jul;40(7):1293-6. PMID: 20112013; X-1

2758. Damm DD. Gingival mass. Congenital epulis. Gen Dent. 2010 Jul-Aug;58(4):344, 7. PMID: 20591782; X-1

2759. de Lange DH, Kreeft M, van Ramshorst GH, et al. Inguinal hernia surgery in The Netherlands: are patients treated according to the guidelines? Hernia. 2010 Apr;14(2):143-8. PMID: 19882299; X-1

2760. de Mesquita CJ. About strawberry, crab claws, and the Sir James Black's invention. Hypothesis: can we battle keloids with propranolol? Med Hypotheses. 2010 Feb;74(2):353-9. PMID: 19758768; X-1, X-2

2761. de Waele L, Freson K, Louwette S, et al. Severe gastrointestinal bleeding and thrombocytopenia in a child with an anti-GATA1 autoantibody. Pediatr Res. 2010 Mar;67(3):314-9. PMID: 19924028; X-1

2762. Duffy KJ, Runge-Samuelson C, Bayer ML, et al. Association of hearing loss with PHACE syndrome. Arch Dermatol. 2010 Dec;146(12):1391-6. PMID: 20713775; X-3

2763. Erbay A, Sarialioglu F, Malbora B, et al. Propranolol for infantile hemangiomas: a preliminary report on efficacy and safety in very low birth weight infants. Turk J Pediatr. 2010 Sep-Oct;52(5):450-6. PMID: 21434528; X-4

2764. Erol OO, Uysal OA, Agaoglu G. Percutaneous electrothrombosis: a minimally invasive technique for the treatment of deep hemangiomas. Aesthetic Plast Surg. 2010 Apr;34(2):214-7. PMID: 19856020; X-1

2765. Fahrtash F, McCahon E, Arbuckle S. Successful treatment of kaposiform hemangioendothelioma and tufted angioma with vincristine. J Pediatr Hematol Oncol. 2010 Aug;32(6):506-10. PMID: 20523249; X-1

2766. Feng ST, Chan T, Ching AS, et al. CT and MR imaging characteristics of infantile hepatic hemangioendothelioma. Eur J Radiol. 2010 Nov;76(2):e24-9. PMID: 20576387; X-1

2767. Fernandez-Pineda I, Lopez-Gutierrez JC, Ramirez G, et al. Vincristine-ticlopidine-aspirin: an effective therapy in children with Kasabach-Merritt phenomenon associated with vascular tumors. Pediatr Hematol Oncol. 2010 Nov;27(8):641-5. PMID: 20863161; X-1

2768. Frank RC, Cowan BJ, Harrop AR, et al. Visual development in infants: visual complications of periocular haemangiomas. J Plast Reconstr Aesthet Surg. 2010 Jan;63(1):1-8. PMID: 19097831; X-3, X-4

2769. Fronie A, Simionescu C, Vasca V, et al. Histopathological aspects of benign mesenchymal tumors located in "high risk areas" of the tongue. Rom J Morphol Embryol. 2010;51(1):97-104. PMID: 20191127; X-1

2770. Gaitanis JN, McMillan HJ, Wu A, et al. Electrophysiologic evidence for anterior horn cell disease in amyoplasia. Pediatr Neurol. 2010 Aug;43(2):142-7. PMID: 20610128; X-1

2771. Gajewska K, Herinckx A, Holoye A, et al. Antenatal embolization of a large chorioangioma by percutaneous Glubran 2 injection. Ultrasound Obstet Gynecol. 2010 Dec;36(6):773-5. PMID: 20737457; X-1

2772. Ganguly R, Mukherjee A. Infantile hemangioendothelioma: A case report and discussion. Pathol Res Pract. 2010 Jan 15;206(1):53-8. PMID: 19321270; X-1

2773. Gelmetti C, Frasin A, Restano L. Innovative therapeutics in pediatric dermatology. Dermatol Clin. 2010 Jul;28(3):619-29. PMID: 20510770; X-2

2774. Gernon TJ, McHugh JB, Thorne MC. Pathology quiz case 2. Diagnosis: Nasal lobular capillary hemangioma (pyogenic granuloma). Arch Otolaryngol Head Neck Surg. 2010 Sep;136(9):930, 2-3. PMID: 20855692; X-1

2775. Giardini A, Gholam C, Khambadkone S, et al. Need for comprehensive vascular assessment before surgical repair of aortic coarctation in PHACES syndrome. Pediatr Cardiol. 2010 Feb;31(2):291-3. PMID: 19936584; X-2

2776. Giron-Vallejo O, Lopez-Gutierrez JC, Fernandez-Pineda I, et al. Dental caries as a side effect of infantile hemangioma treatment with propranolol solution. Pediatr Dermatol. 2010 Nov-Dec;27(6):672-3. PMID: 21510011; X-2

2777. Glade RS, Vinson K, Becton D, et al. Management of complicated hemangiomas with vincristine/vinblastine: Quantitative response to therapy using MRI. Int J Pediatr Otorhinolaryngol. 2010 Nov;74(11):1221-5. PMID: 20884067; X-4

2778. Gordillo G, Fang H, Park H, et al. Nox-4-dependent nuclear H2O2 drives DNA oxidation resulting in 8-OHdG as urinary biomarker and hemangioendothelioma formation. Antioxid Redox Signal. 2010 Apr 15;12(8):933-43. PMID: 19817625; X-1

2779. Greenberger S, Adini I, Boscolo E, et al. Targeting NF-kappaB in infantile hemangioma-derived stem cells reduces VEGF-A expression. Angiogenesis. 2010 Dec;13(4):327-35. PMID: 20872175; X-1

2780. Greenberger S, Boscolo E, Adini I, et al. Corticosteroid suppression of VEGF-A in infantile hemangioma-derived stem cells. N Engl J Med. 2010 Mar 18;362(11):1005-13. PMID: 20237346; X-1

2781. Greene AK. Systemic corticosteroid is effective and safe treatment for problematic infantile hemangioma. Pediatr Dermatol. 2010 May-Jun;27(3):322-3. PMID: 20609168; X-1, X-2

2782. Grover C, Arora P, Kedar A, et al. Combination of oral corticosteroids and polidocanol sclerotherapy in the management of infantile hemangiomas. Dermatol Surg. 2010 Dec;36(12):2030-6. PMID: 21040124; X-4

2783. Guiteau JJ, Cotton RT, Karpen SJ, et al. Pediatric liver transplantation for primary malignant liver tumors with a focus on hepatic epithelioid hemangioendothelioma: the UNOS experience. Pediatr Transplant. 2010 May;14(3):326-31. PMID: 20051026; X-1

2784. Guo S, Hunt MG, Superstein R. Treatment of infantile hemangiomas. J Pediatr Ophthalmol Strabismus. 2010 Jul-Aug;47(4):198-201. PMID: 20635807; X-1, X-2

2785. Haddy N, Dondon MG, Paoletti C, et al. Breast cancer following radiotherapy for a hemangioma during childhood. Cancer Causes Control. 2010 Nov;21(11):1807-16. PMID: 20607383; X-1

2786. Haggstrom AN, Garzon MC, Baselga E, et al. Risk for PHACE syndrome in infants with large facial hemangiomas. Pediatrics. 2010 Aug;126(2):e418-26. PMID: 20643720; X-3, X-4

2787. Haider KM, Plager DA, Neely DE, et al. Outpatient treatment of periocular infantile hemangiomas with oral propranolol. J aapos. 2010 Jun;14(3):251-6. PMID: 20603059; X-4

2788. Hassanein AH, Fishman SJ, Mulliken JB, et al. Metastatic neuroblastoma mimicking infantile hemangioma. J Pediatr Surg. 2010 Oct;45(10):2045-9. PMID: 20920727; X-2

2789. Hassell LA, Roanh le D. Potential response to curcumin in infantile hemangioendothelioma of the liver. Pediatr Blood Cancer. 2010 Aug;55(2):377-9. PMID: 20582974; X-1

2790. Holland KE, Frieden IJ, Frommelt PC, et al. Hypoglycemia in children taking propranolol for the treatment of infantile hemangioma. Arch Dermatol. 2010 Jul;146(7):775-8. PMID: 20644039; X-3, X-4

2791. Hong B, Hermann EJ, Klein R, et al. Surgical resection of osteolytic calvarial lesions: clinicopathological features. Clin Neurol Neurosurg. 2010 Dec;112(10):865-9. PMID: 20685034; X-1

2792. Hong JY, Kim WO, Koo BN, et al. The relative position of ilioinguinal and iliohypogastric nerves in different age groups of pediatric patients. Acta Anaesthesiol Scand. 2010 May;54(5):566-70. PMID: 20236097; X-1

2793. Huang AP, Chen JS, Yang CC, et al. Brain stem cavernous malformations. J Clin Neurosci. 2010 Jan;17(1):74-9. PMID: 20005720; X-1

2794. Hunzeker CM, Geronemus RG. Treatment of superficial infantile hemangiomas of the eyelid using the 595-nm pulsed dye laser. Dermatol Surg. 2010 May;36(5):590-7. PMID: 20384759; X-4

2795. Iacobas I, Burrows PE, Frieden IJ, et al. LUMBAR: association between cutaneous infantile hemangiomas of the lower body and regional congenital anomalies. J Pediatr. 2010 Nov;157(5):795-801.e1-7. PMID: 20598318; X-3, X-4

2796. Indolfi P, Donofrio V, Fusco C, et al. Kaposiform hemangioendothelioma of the kidney: an unusual presentation of a rare vascular neoplasm. J Pediatr Hematol Oncol. 2010 Jul;32(5):e195-8. PMID: 20588198; X-1

2797. Irving ND, Lim JH, Cohen B, et al. Sturge-Weber syndrome: ear, nose, and throat issues and neurologic status. Pediatr Neurol. 2010 Oct;43(4):241-4. PMID: 20837301; X-1

2798. Jadhav VM, Tolat SN. Dramatic response of propranolol in hemangioma: report of two cases. Indian J Dermatol Venereol Leprol. 2010 Nov-Dec;76(6):691-4. PMID: 21079315; X-2

2799. Jinnin M, Ishihara T, Boye E, et al. Recent progress in studies of infantile hemangioma. J Dermatol. 2010 Nov;37(11):939-55. PMID: 21039783; X-2

2800. Kao YC, Lin MI. Intramuscular hemangioma of the temporalis muscle with incidental finding of bilateral symmetric calcification of the basal ganglia: a case report. Pediatr Neonatol. 2010 Oct;51(5):296-9. PMID: 20951361; X-1

2801. Kattepura S, Kini U, Das K. Retroauricular intravascular lobular capillary haemangioma in a child. Int J Pediatr Otorhinolaryngol Extra. 2010 January;5(1):13-5. PMID: 2009648957; X-1, X-2

2802. Kazim SF, Bhatti, Enam SA. Intracranial cavernous angiomas. J Coll Physicians Surg Pak. 2010 Nov;20(11):738-43. PMID: 21078247; X-1

2803. Kelly ME, Juern AM, Grossman WJ, et al. Immunosuppressive effects in infants treated with corticosteroids for infantile hemangiomas. Arch Dermatol. 2010 Jul;146(7):767-74. PMID: 20479291; X-4

2804. Khandpur S, Sharma VK. Utility of intralesional sclerotherapy with 3% sodium tetradecyl sulphate in cutaneous vascular malformations. Dermatol Surg. 2010 Mar;36(3):340-6. PMID: 20100267; X-1

2805. Killory BD, Chang SW, Wait SD, et al. Use of flexible hollow-core CO2 laser in microsurgical resection of CNS lesions: early surgical experience. Neurosurgery. 2010 Jun;66(6):1187-92. PMID: 20495434; X-1

2806. Kim TJ, Lee YS, Song YS, et al. Infantile hemangioendothelioma with elevated serum alpha fetoprotein: report of 2 cases with immunohistochemical analysis. Hum Pathol. 2010 May;41(5):763-7. PMID: 20153513; X-1, X-2

2807. Kiymaz N, Yilmaz N, Ozen S, et al. Cavernous hemangioma presenting as a giant cervical mass: a case report. Turk Neurosurg. 2010 Jan;20(1):69-72. PMID: 20066626; X-1, X-2

2808. Kossoff EH, Borsage JL, Comi AM. A pilot study of the modified Atkins diet for Sturge-Weber syndrome. Epilepsy Res. 2010 Dec;92(2-3):240-3. PMID: 20934305; X-1

2809. Kostrzewa JP, Bowman MK, Woolley AL. Middle ear hemangioma: A novel treatment for a rare problem. Int J Pediatr Otorhinolaryngol Extra. 2010 March;5(2):50-2. PMID: 2010101491; X-2

2810. Kumar PV, Salimi A, Ahmadi J. Infantile hepatic hemangioendothelioma: report of a case with fine needle aspiration findings. Acta Cytol. 2010 Sep-Oct;54(5 Suppl):807-10. PMID: 21053545; X-2

2811. Kumar V, Murali M. Large cavernous hemangioma. Indian Pediatr. 2010 Jun;47(6):521-2. PMID: 20622281; X-1

2812. Leboulanger N, Fayoux P, Teissier N, et al. Propranolol in the therapeutic strategy of infantile laryngotracheal hemangioma: A preliminary retrospective study of French experience. Int J Pediatr Otorhinolaryngol. 2010 Nov;74(11):1254-7. PMID: 20800295; X-4

2813. Lee IJ, Kim CS, Seo SJ, et al. A case of non-involuting congenital haemangioma with multiple epidermal cysts. J Plast Reconstr Aesthet Surg. 2010 Jan;63(1):e19-22. PMID: 19345168; X-1

2814. Levitin GM, Thompson SH, Berenstein A, et al. Surgical treatment of buccofacial region vascular anomalies using an intraoral buccomucosal flap procedure. Arch Otolaryngol Head Neck Surg. 2010 Feb;136(2):134-7. PMID: 20157057; X-1

2815. Li YC, McCahon E, Rowe NA, et al. Successful treatment of infantile haemangiomas of the orbit with propranolol. Clin Experiment Ophthalmol. 2010 Aug;38(6):554-9. PMID: 20491798; X-4

2816. Listernick R. A 1-day-old boy with a liver mass. Pediatr Ann. 2010 Jun;39(6):332-5. PMID: 20669886; X-1

2817. Londero M, Pastore S, Zanazzo GA, et al. A child with pain after mild trauma. J Pediatr. 2010 Oct;157(4):693. PMID: 20553843; X-1

2818. Lunsford LD, Khan AA, Niranjan A, et al. Stereotactic radiosurgery for symptomatic solitary cerebral cavernous malformations considered high risk for resection. J Neurosurg. 2010 Jul;113(1):23-9. PMID: 20170299; X-1

2819. Macedo A, Jr., Ottoni SL, Barroso U, Jr., et al. Bladder hemangiomas and Proteus syndrome: a rare clinical association. J Pediatr Urol. 2010 Aug;6(4):429-31. PMID: 20044313; X-1, X-2

2820. Mackley AB, Locke RG, Spear ML, et al. Forgotten parent: NICU paternal emotional response. Adv Neonatal Care. 2010 Aug;10(4):200-3. PMID: 20697219; X-1

2821. Madhusudhan KS, Srivastava DN, Gamanagatti S. Multifocal epithelioid hemangioendothelioma presenting with hemoptysis. Indian J Pediatr. 2010 Jun;77(6):699-700. PMID: 20532691; X-1

2822. Maguiness SM, Hoffman WY, McCalmont TH, et al. Early white discoloration of infantile hemangioma: a sign of impending ulceration. Arch Dermatol. 2010 Nov;146(11):1235-9. PMID: 21079059; X-3, X-4

2823. Manobianca G, Zoccolella S, Petruzzellis A, et al. The incidence of major stroke subtypes in southern Italy: a population-based study. Eur J Neurol. 2010 Sep;17(9):1148-55. PMID: 20298424; X-1

2824. Maton B, Krsek P, Jayakar P, et al. Medically intractable epilepsy in Sturge-Weber syndrome is associated with cortical malformation: implications for surgical therapy. Epilepsia. 2010 Feb;51(2):257-67. PMID: 19780796; X-1

2825. Maturo S, Hartnick C. Initial experience using propranolol as the sole treatment for infantile airway hemangiomas. Int J Pediatr Otorhinolaryngol. 2010 Mar;74(3):323-5. PMID: 20071038; X-2

2826. Mazereeuw-Hautier J, Hoeger PH, Benlahrech S, et al. Efficacy of propranolol in hepatic infantile hemangiomas with diffuse neonatal hemangiomatosis. J Pediatr. 2010 Aug;157(2):340-2. PMID: 20488455; X-4

2827. Mazzotta F, Bonifazi E. Eruptive angioma with satellitosis. European Journal of Pediatric Dermatology. 2010 July-September;20(3):207. PMID: 2010635564; X-1

2828. McHoney M. Early human development: neonatal tumours: vascular tumours. Early Hum Dev. 2010 Oct;86(10):613-8. PMID: 20850940; X-2

2829. Menzler K, Chen X, Thiel P, et al. Epileptogenicity of cavernomas depends on (archi-) cortical localization. Neurosurgery. 2010 Oct;67(4):918-24. PMID: 20881556; X-1

2830. Meyer L, Graffstaedt H, Giest H, et al. Effectiveness of propranolol in a newborn with liver hemangiomatosis. Eur J Pediatr Surg. 2010 Nov;20(6):414-5. PMID: 20628969; X-1

2831. Mistry N, Tzifa K. Use of propranolol to treat multicentric airway haemangioma. J Laryngol Otol. 2010 Dec;124(12):1329-32. PMID: 20370949; X-2

2832. Mitsionis GI, Pakos EE, Kosta P, et al. Intramuscular hemangioma of the foot: A case report and review of the literature. Foot Ankle Surg. 2010 Jun;16(2):e27-9. PMID: 20483123; X-1, X-2

2833. Miyoshi Y, Yasuhara T, Omori M, et al. Infantile cervical intramedullary cavernous angioma manifesting as hematomyelia. Case report. Neurol Med Chir (Tokyo). 2010;50(8):677-82. PMID: 20805654; X-1

2834. Mousa W, Kues K, Haas E, et al. Successful treatment of a large hemangioma with propranolol. J Dtsch Dermatol Ges. 2010 Mar;8(3):184-6. PMID: 19788583; X-1, X-2

2835. Muthamilselvan S, Vinoth PN, Vilvanathan V, et al. Hepatic haemangioma of infancy: role of propranolol. Ann Trop Paediatr. 2010;30(4):335-8. PMID: 21118629; X-2

2836. Nagy G, Razak A, Rowe JG, et al. Stereotactic radiosurgery for deep-seated cavernous malformations: a move toward more active, early intervention. Clinical article. J Neurosurg. 2010 Oct;113(4):691-9. PMID: 20433275; X-1

2837. Naouri M, Schill T, Maruani A, et al. Successful treatment of ulcerated haemangioma with propranolol. J Eur Acad Dermatol Venereol. 2010 Sep;24(9):1109-12. PMID: 20337809; X-3, X-4

2838. Nishino K, Ito Y, Sorimachi T, et al. Sturge-Weber syndrome associated with arteriovenous malformation in a patient presenting with progressive brain edema and cyst formation. J Neurosurg Pediatr. 2010 May;5(5):529-34. PMID: 20433269; X-1

2839. Nonogaki S, Campos HGA, Butugan O, et al. Markers of vascular differentiation, proliferation and tissue remodeling in juvenile nasopharyngeal angiofibromas. Exp Ther Med. 2010 November;1(6):921-6. PMID: 2010598723; X-1

2840. Ohue S, Fukushima T, Kumon Y, et al. Surgical management of brainstem cavernomas: selection of approaches and microsurgical techniques. Neurosurg Rev. 2010 Jul;33(3):315-22; discussion 23-4. PMID: 20358241; X-1

2841. Osio A, Fraitag S, Hadj-Rabia S, et al. Clinical spectrum of tufted angiomas in childhood: a report of 13 cases and a review of the literature. Arch Dermatol. 2010 Jul;146(7):758-63. PMID: 20644037; X-1

2842. Otte JB, Meyers R. PLUTO first report. Pediatr Transplant. 2010 Nov;14(7):830-5. PMID: 20946516; X-1

2843. Pandya R, Tummala V. Giant infantile pulmonary hemangioma. Pediatr Radiol. 2010 Dec;40 Suppl 1:S63-7. PMID: 20461368; X-1, X-2

2844. Paramanathan N, Ooi KG, Reeves D, et al. Synchronous radiation-induced orbital meningioma and multiple cavernomas. Clin Experiment Ophthalmol. 2010 May;38(4):414-7. PMID: 20491803; X-1

2845. Pascual-Castroviejo I, Pascual-Pascual SI, Velazquez-Fragua R, et al. Association of cutaneous red-to-purple hemangiomas with leptomeningeal hemangiomas. a clinical study of two patients. Neuropediatrics. 2010 Feb;41(1):7-11. PMID: 20571984; X-3, X-4

2846. Patil SJ, Moray AA, Kiran VS, et al. PHACE/S syndrome: a syndromic infantile segmental hemangioma. Indian J Pediatr. 2010 Aug;77(8):911-3. PMID: 20953914; X-2

2847. Pavlakovic H, Kietz S, Lauerer P, et al. Hyperkalemia complicating propranolol treatment of an infantile hemangioma. Pediatrics. 2010 Dec;126(6):e1589-93. PMID: 21115582; X-2

2848. Perez-Valle S, Peinador M, Herraiz P, et al. Vincristine, an efficacious alternative for diffuse neonatal haemangiomatosis. Acta Paediatr. 2010 Feb;99(2):311-5. PMID: 20353500; X-1, X-2

2849. Peters C, Langham S, Mullis PE, et al. Use of combined liothyronine and thyroxine therapy for consumptive hypothyroidism associated with hepatic haemangiomas in infancy. Horm Res Paediatr. 2010;74(2):149-52. PMID: 20516650; X-1, X-2

2850. Petersen TA, Morrison LA, Schrader RM, et al. Familial versus sporadic cavernous malformations: differences in developmental venous anomaly association and lesion phenotype. AJNR Am J Neuroradiol. 2010 Feb;31(2):377-82. PMID: 19833796; X-1

2851. Poulsen ML, Budtz-Jorgensen E, Bisgaard ML. Surveillance in von Hippel-Lindau disease (vHL). Clin Genet. 2010 Jan;77(1):49-59. PMID: 19863552; X-1

2852. Provenzale JM. Imaging findings of structural causes of epilepsy in children: a guide for the radiologist in the emergency room. Emerg Radiol. 2010 Nov;17(6):479-86. PMID: 20596745; X-1

2853. Pruksachatkun C. Report of the 11th World Congress of Pediatric Dermatology in Bangkok, Thailand. Pediatr Dermatol. 2010 May-Jun;27(3):223-5. PMID: 20609139; X-2

2854. Ramasubramanian A, Shields CL, Harmon SA, et al. Autofluorescence of choroidal hemangioma in 34 consecutive eyes. Retina. 2010 Jan;30(1):16-22. PMID: 19952988; X-1

2855. Rao AB, Pence J, Mirkin DL. Diffuse infantile hemangiomatosis of the ileum presenting with multiple perforations: a case report and review of the literature. J Pediatr Surg. 2010 Sep;45(9):1890-2. PMID: 20850639; X-1

2856. Rasalkar DD, Chu WC, Cheng FW, et al. An institutional review of paediatric haemangiomas: prevalence, imaging features, and outcomes. Hong Kong Med J. 2010 Oct;16(5):334-40. PMID: 20889996; X-4

2857. Rempel GR, Borton BL. Is aspiration during swalowing more common in children with indigenous herita ge? Paediatr Child Health 2010 May-June;15:65A. PMID: 70780368; X-1

2858. Rosbe KW, Suh KY, Meyer AK, et al. Propranolol in the management of airway infantile hemangiomas. Arch Otolaryngol Head Neck Surg. 2010 Jul;136(7):658-65. PMID: 20644059; X-3, X-4

2859. Saafan AM, Salah MM. Using pulsed dual-wavelength 595 and 1064 nm is more effective in the management of hemangiomas. J Drugs Dermatol. 2010 Apr;9(4):310-4. PMID: 20514786; X-3, X-4

2860. Sachdeva R, Dadgostar H, Kaiser PK, et al. Verteporfin photodynamic therapy of six eyes with retinal capillary haemangioma. Acta Ophthalmol. 2010 Dec;88(8):e334-40. PMID: 20946329; X-1

2861. Salunke P, Sinha R, Khandelwal NK, et al. Primary intraosseus cavernous hemangioma of the skull base. Br J Neurosurg. 2010 Feb;24(1):84-5. PMID: 20158361; X-1

2862. Sarikaya-Seiwert S, Gierga K, Wessalowski R, et al. Solitary spinal epidural cavernous angiomas in children presenting with acute neurological symptoms caused by hemorrhage. J Neurosurg Pediatr. 2010 Jan;5(1):89-93. PMID: 20043742; X-1

2863. Sato Y, Nozawa S, Yoshiike M, et al. Xenografting of testicular tissue from an infant human donor results in accelerated testicular maturation. Hum Reprod. 2010 May;25(5):1113-22. PMID: 20172867; X-1

2864. Schupp CJ, Holland-Cunz S, Schenk JP, et al. Multiple hemangiomas and hemangiomatosis--risk factors and outcome over an eight year period. Eur J Pediatr Surg. 2010 Nov;20(6):379-81. PMID: 20665431; X-3

2865. Schwanke J. Birthmarks in newborns can signal later problems. Contemp Pediatr. 2010;27(7):24-6. PMID: X-2

2866. Senchak AJ, Dann M, Cable B, et al. Successful treatment of cutaneous hemangioma of infancy with topical imiquimod 5%: a report of 3 cases. Ear Nose Throat J. 2010 Mar;89(3):E21-5. PMID: 20229466; X-3, X-4

2867. Serra AM, Soares FM, Cunha Junior AG, et al. Therapeutic management of skin hemangiomas in children. An Bras Dermatol. 2010 May-Jun;85(3):307-17. PMID: 20676463; X-3, X-4

2868. Sharma S, Sankhyan N, Gulati S, et al. Intracranial cavernomatous hemangiomas as a cause of childhood temporal lobe epilepsy. J Child Neurol. 2010 Nov;25(11):1423-4. PMID: 20519670; X-1

2869. Shen W, Cui J, Chen J, et al. Kasabach-Merritt syndrome: case reports of successful treatment with partial tumor resection and vincristine chemotherapy. Ann Plast Surg. 2010 Sep;65(3):361-3. PMID: 20733375; X-1

2870. Shen W, Cui J, Chen J, et al. Kasabach-Merritt syndrome with partial resection of tumor, reduction of tumor blood, and vincristine chemotherapy. J Craniofac Surg. 2010 Jan;21(1):215-6. PMID: 20098187; X-1

2871. Sigamani E, Iyer VK, Agarwala S. Fine needle aspiration cytology of infantile haemangioendothelioma of the liver: a report of two cases. Cytopathology. 2010 Dec;21(6):398-402. PMID: 20337692; X-1

2872. Snyder H, Pope AW. Psychosocial adjustment in children and adolescents with a craniofacial anomaly: diagnosis-specific patterns. Cleft Palate Craniofac J. 2010 May;47(3):264-72. PMID: 19860517; X-1, X-3

2873. Sorrell J, Carmichael C, Chamlin S. Oral sucrose for pain relief in young infants with hemangiomas treated with intralesional steroids. Pediatr Dermatol. 2010 Mar-Apr;27(2):154-5. PMID: 20537065; X-1

2874. Spinks J. A clue on the face. BMJ Case Rep. 2010;2010PMID: 22736736; X-2

2875. Storch CH, Hoeger PH. Propranolol for infantile haemangiomas: insights into the molecular mechanisms of action. Br J Dermatol. 2010 Aug;163(2):269-74. PMID: 20456345; X-1, X-2

2876. Suh KY, Frieden IJ. Infantile hemangiomas with minimal or arrested growth: a retrospective case series. Arch Dermatol. 2010 Sep;146(9):971-6. PMID: 20855695; X-3, X-4

2877. Sukop A, Malis J, Tvrdek M, et al. Diagnostic dilemmas of infantile sarcoma of the forearm. Acta Chir Plast. 2010;52(1):19-21. PMID: 21110498; X-1

2878. Suskauer SJ, Trovato MK, Zabel TA, et al. Physiatric findings in individuals with Sturge-Weber syndrome. Am J Phys Med Rehabil. 2010 Apr;89(4):323-30. PMID: 20068437; X-1

2879. Suurmeijer AJ. Papillary hemangiomas and glomeruloid hemangiomas are distinct clinicopathological entities. Int J Surg Pathol. 2010 Feb;18(1):48-54. PMID: 18805868; X-1

2880. Tabatabaii SA, Khanbabaii G, Khatami AR, et al. Characteristic and follow-up of subglottic hemangiomas in Iranian children. J Res Med Sci. 2010;15(4)PMID: 2010399093; X-2

2881. Tamai N, Hashii Y, Osuga K, et al. Kaposiform hemangioendothelioma arising in the deltoid muscle without the Kasabach-Merritt phenomenon. Skeletal Radiol. 2010 Oct;39(10):1043-6. PMID: 20309545; X-1

2882. Tanwar M, Sihota R, Dada T, et al. Sturge-Weber syndrome with congenital glaucoma and cytochrome P450 (CYP1B1) gene mutations. J Glaucoma. 2010 Aug;19(6):398-404. PMID: 20051892; X-1

2883. Terui K, Nakatani Y, Kambe M, et al. Kaposiform hemangioendothelioma of the choledochus. J Pediatr Surg. 2010 Sep;45(9):1887-9. PMID: 20850638; X-1

2884. Thiex R, Mulliken JB, Revencu N, et al. A novel association between RASA1 mutations and spinal arteriovenous anomalies. AJNR Am J Neuroradiol. 2010 Apr;31(4):775-9. PMID: 20007727; X-1

2885. Torre M, Yankovic F, Herrera O, et al. Granular cell tumor mimicking a subglottic hemangioma. J Pediatr Surg. 2010 Dec;45(12):e9-11. PMID: 21129532; X-1, X-2

2886. Truong MT, Chang KW, Berk DR, et al. Propranolol for the treatment of a life-threatening subglottic and mediastinal infantile hemangioma. J Pediatr. 2010 Feb;156(2):335-8. PMID: 20105647; X-2

2887. Truong MT, Perkins JA, Messner AH, et al. Propranolol for the treatment of airway hemangiomas: a case series and treatment algorithm. Int J Pediatr Otorhinolaryngol. 2010 Sep;74(9):1043-8. PMID: 20674045; X-4

2888. Turin E, Grados MA, Tierney E, et al. Behavioral and psychiatric features of Sturge-Weber syndrome. J Nerv Ment Dis. 2010 Dec;198(12):905-13. PMID: 21135644; X-1

2889. Ulku R, Onat S, Avci A, et al. Resection of intercostal hemangioma with involved chest wall and ribs: in an 11-year-old girl. Tex Heart Inst J. 2010;37(4):486-9. PMID: 20844630; X-1

2890. Utsumi K, Ogasawara N, Sasaki M, et al. Intussusception in a child caused by capillary hemangioma of the colon. Clin J Gastroenterol. 2010 April;3(2):83-7. PMID: 2010389756; X-1, X-2

2891. Vanlander A, Decaluwe W, Vandelanotte M, et al. Propranolol as a novel treatment for congenital visceral haemangioma. Neonatology. 2010;98(3):229-31. PMID: 20389127; X-1, X-2

2892. Veening MA, Verbeke JI, Witbreuk MM, et al. Kaposiform (spindle cell) hemangioendotelioma in a child with an unusual presentation. J Pediatr Hematol Oncol. 2010 Apr;32(3):240-2. PMID: 20387265; X-1

2893. Walter C, Mbebe T, Caragounis E, et al. Blue rubber bleb naevus syndrome: a rare cause of gastrointestinal bleeding in an African child. Afr J Paediatr Surg. 2010 Sep-Dec;7(3):206-8. PMID: 20859034; X-1

2894. Wang NK, Hung KL, Liao HC, et al. A patient with PHACE syndrome with marked ipsilateral cerebral atrophy. Pediatr Neonatol. 2010 Apr;51(2):130-4. PMID: 20417465; X-1, X-2

2895. Warren SM, Zide BM. Reconstruction of temporal and suprabrow defects. Ann Plast Surg. 2010 Mar;64(3):298-301. PMID: 20179477; X-1

2896. Watanabe M, Abe M, Ogawa S. A case of neonatal cardiac tamponade associated with benign hemangioma. J Nippon Med Sch. 2010 Feb;77(1):2-3. PMID: 20154451; X-1, X-2

2897. Watanabe S, Takahashi T, Fujibuchi T, et al. Synovial hemangioma of the knee joint in a 3-year-old girl. J Pediatr Orthop B. 2010 Nov;19(6):515-20. PMID: 20697297; X-1, X-2

2898. Wiegand S, Zimmermann AP, Eivazi B, et al. Analysis of clinically suspected orbital cavernomas. Br J Ophthalmol. 2010 Dec;94(12):1653-6. PMID: 20494913; X-1

2899. Wiygul JB, Palmer L. Isolated hemangioma causing gross painless hematuria in an adolescent male. Urology. 2010 Aug;76(2):463-4. PMID: 20163837; X-1, X-2

2900. Wortsman X, Wortsman J, Arellano J, et al. Pilomatrixomas presenting as vascular tumors on color Doppler ultrasound. J Pediatr Surg. 2010 Oct;45(10):2094-8. PMID: 20920738; X-1

2901. Xie CM, Kubba H. Parotidectomy in children: indications and complications. J Laryngol Otol. 2010 Dec;124(12):1289-93. PMID: 20519039; X-3, X-4

2902. Xu QW, Xu R, Du ZY, et al. Surgical treatment for hemangioblastomas in the medulla oblongata. Acta Neurochir (Wien). 2010 Aug;152(8):1331-5; discussion 5. PMID: 20419458; X-1

2903. Yadav N, Prabhakar H, Singh GP, et al. Acute hemodynamic instability during alcohol ablation of symptomatic vertebral hemangioma: a prospective study. J Clin Neurosci. 2010 Jun;17(6):810-1. PMID: 20400319; X-1

2904. Yang CY, Hsu JF, Lin KL, et al. An extra-axial hemangioma mimicking a large prenatal brain tumor. Brain Dev. 2010 Nov;32(10):883-6. PMID: 20347240; X-1, X-2

2905. Yu DC, Grabowski MJ, Kozakewich HP, et al. Primary lung tumors in children and adolescents: a 90-year experience. J Pediatr Surg. 2010 Jun;45(6):1090-5. PMID: 20620301; X-1

2906. Zanardini C, Papageorghiou A, Bhide A, et al. Giant placental chorioangioma: natural history and pregnancy outcome. Ultrasound Obstet Gynecol. 2010 Mar;35(3):332-6. PMID: 19859897; X-1

2907. Zhang Z, Chen HJ, Yang WJ, et al. Infantile hepatic hemangioendothelioma: a clinicopathologic study in a Chinese population. World J Gastroenterol. 2010 Sep 28;16(36):4549-57. PMID: 20857525; X-1

2908. . In brief: oral propranolol infantile hemangiomas. Med Lett Drugs Ther. 2011 Oct 31;53(1376):88. PMID: 22033213; X-2

2909. . Propranolol effective in shrinking infantile hemangioma. Contemp Pediatr. 2011;28(9):11-2. PMID: X-1, X-2

2910. Abdul Aziz DA, Khandasamy Y, Tamba RP, et al. Bleeding small bowel cavernous haemangioma following blunt trauma to the abdomen presenting as subacute intestinal obstruction in a child. BMJ Case Rep. 2011;2011PMID: 22679168; X-1

2911. Abujarir R, Salama H, Alsulaiti G, et al. Congenital scalp myofibroma: A case report. J Neonatal Perinatal Med. 2011;4(1):75-8. PMID: 2011178756; X-1

2912. Ackermann O, Fabre M, Franchi S, et al. Widening spectrum of liver angiosarcoma in children. J Pediatr Gastroenterol Nutr. 2011 Dec;53(6):615-9. PMID: 21832953; X-1, X-3

2913. Adepoju O, Wong A, Kitajewski A, et al. Expression of HES and HEY genes in infantile hemangiomas. Vasc Cell. 2011;3(19)PMID: 2012150764; X-1, X-3

2914. Al Dhaybi R, Superstein R, Milet A, et al. Treatment of periocular infantile hemangiomas with propranolol: case series of 18 children. Ophthalmology. 2011 Jun;118(6):1184-8. PMID: 21292326; X-4

2915. Albertini AF, Brousse N, Bodemer C, et al. Retiform hemangioendothelioma developed on the site of an earlier cystic lymphangioma in a six-year-old girl. Am J Dermatopathol. 2011 Oct;33(7):e84-7. PMID: 21915027; X-1

2916. Alkonyi B, Chugani HT, Juhasz C. Transient focal cortical increase of interictal glucose metabolism in Sturge-Weber syndrome: implications for epileptogenesis. Epilepsia. 2011 Jul;52(7):1265-72. PMID: 21480889; X-1

2917. Alkonyi B, Chugani HT, Karia S, et al. Clinical outcomes in bilateral Sturge-Weber syndrome. Pediatr Neurol. 2011 Jun;44(6):443-9. PMID: 21555056; X-1

2918. Annamalai A, Puri V, Mehta S. Radium implant treatment of a birthmark at infancy and its association with malignancy. Am Surg. 2011 Mar;77(3):372-3. PMID: 21375861; X-1

2919. Antonio MT, Maia SF, Dionisio MT, et al. Superior sternal cleft, supraumbilical midline raphe and haemangiomas in a baby girl with an ostium secundum ASD. Clin Dysmorphol. 2011 Apr;20(2):95-7. PMID: 21233709; X-2

2920. Athavale SM, Ries WR, Carniol PJ. Laser treatment of cutaneous vascular tumors and malformations. Facial Plast Surg Clin North Am. 2011 May;19(2):303-12. PMID: 21763991; X-1

2921. Avery G, Davis C, Tan ST. Hemangioma causing deformational plagiocephaly. J Craniofac Surg. 2011 Jan;22(1):223-5. PMID: 21233747; X-3, X-4

2922. Bagazgoitia L, Hernandez-Martin A, Torrelo A. Recurrence of infantile hemangiomas treated with propranolol. Pediatr Dermatol. 2011 Nov-Dec;28(6):658-62. PMID: 22082463; X-3, X-4

2923. Ballah D, Cahill AM, Fontalvo L, et al. Vascular anomalies: what they are, how to diagnose them, and how to treat them. Curr Probl Diagn Radiol. 2011 Nov-Dec;40(6):233-47. PMID: 21939817; X-1, X-2

2924. Barros A, Freitas AC, Cabral AJ, et al. Giant placental chorioangioma: a rare cause of fetal hydrops. BMJ Case Rep. 2011;2011PMID: 22696752; X-1

2925. Bauland CG, Luning TH, Smit JM, et al. Untreated hemangiomas: growth pattern and residual lesions. Plast Reconstr Surg. 2011 Apr;127(4):1643-8. PMID: 21460670; X-3, X-4

2926. Bay MJ, Kossoff EH, Lehmann CU, et al. Survey of aspirin use in Sturge-Weber syndrome. J Child Neurol. 2011 Jun;26(6):692-702. PMID: 21427442; X-1

2927. Behen ME, Juhasz C, Wolfe-Christensen C, et al. Brain damage and IQ in unilateral Sturge-Weber syndrome: support for a "fresh start" hypothesis. Epilepsy Behav. 2011 Oct;22(2):352-7. PMID: 21852199; X-1

2928. Behnke NM, Patel M, Davidson T, et al. Orthopaedic case of the month: Rapidly progressive shoulder soft tissue mass in an 8-week-old girl. Clin Orthop Relat Res. 2011 Feb;469(2):624-9. PMID: 21128034; X-1

2929. Beltran C, Garcia RJ, Tevah J, et al. Severe recurrent epistaxis in children: A case report involving two complex underlying conditions. Int J Pediatr Otorhinolaryngol Extra. 2011 December;6(4):335-8. PMID: 2012060823; X-2

2930. Bigi S, Capone Mori A, Steinlin M, et al. Cavernous malformations of the central nervous system in children: presentation, treatment and outcome of 20 cases. Eur J Paediatr Neurol. 2011 Mar;15(2):109-16. PMID: 21041104; X-1

2931. Bonet-Coloma C, Minguez-Martinez I, Palma-Carrio C, et al. Clinical characteristics, treatment and outcome of 28 oral haemangiomas in pediatric patients. Med Oral Patol Oral Cir Bucal. 2011 Jan;16(1):e19-22. PMID: 20711165; X-3, X-4

2932. Bonini FK, Bellodi FS, Souza EM. Propranolol treatment for hemangioma of infancy. An Bras Dermatol. 2011 Jul-Aug;86(4):763-6. PMID: 21987146; X-2

2933. Boscolo E, Mulliken JB, Bischoff J. VEGFR-1 mediates endothelial differentiation and formation of blood vessels in a murine model of infantile hemangioma. Am J Pathol. 2011 Nov;179(5):2266-77. PMID: 21945324; X-1

2934. Boscolo E, Stewart CL, Greenberger S, et al. JAGGED1 signaling regulates hemangioma stem cell-to-pericyte/vascular smooth muscle cell differentiation. Arterioscler Thromb Vasc Biol. 2011 Oct;31(10):2181-92. PMID: 21757656; X-1

2935. Bracken J, Robinson I, Snow A, et al. PHACE syndrome: MRI of intracerebral vascular anomalies and clinical findings in a series of 12 patients. Pediatr Radiol. 2011 Sep;41(9):1129-38. PMID: 21674285; X-3, X-4

2936. Breur JM, de Graaf M, Breugem CC, et al. Hypoglycemia as a result of propranolol during treatment of infantile hemangioma: a case report. Pediatr Dermatol. 2011 Mar-Apr;28(2):169-71. PMID: 20738795; X-2

2937. Cavaleiro LHS, Viana FO, Unger DAA, et al. Propranolol for extensive hemangiomas of infancy: Two case reports

Hemangiomas extensos da infancia tratados com propranolol: Relato de dois casos. Jornal Vascular Brasileiro. 2011 June;10(2):173-6. PMID: 2012158295; X-2

2938. Chaudhary SC, Sonkar SK, Kumar V, et al. Sturge Weber syndrome. J Assoc Physicians India. 2011 May;59:327-9. PMID: 21751615; X-1

2939. Chen TH, Lin JY, Chen WF, et al. Elevated serum alpha-fetoprotein in a neonate with cutaneous infantile hemangioendothelioma. Pediatr Int. 2011 Apr;53(2):258-61. PMID: 21501314; X-1, X-2

2940. Chen YC, Wu JC, Liu L, et al. Correlation between ventriculoperitoneal shunts and inguinal hernias in children: an 8-year follow-up. Pediatrics. 2011 Jul;128(1):e121-6. PMID: 21690112; X-1

2941. Chkioua L, Khedhiri S, Ben Turkia H, et al. Hurler disease (mucopolysaccharidosis type IH): clinical features and consanguinity in Tunisian population. Diagn Pathol. 2011;6:113. PMID: 22074387; X-1

2942. Cho JH, Choi JY, Noh HI, et al. Giant lobular capillary hemangioma of the palate associated with Kasabach-Merritt syndrome. Int J Pediatr Otorhinolaryngol Extra. 2011 January;6(1):48-50. PMID: 2011040392; X-1, X-2

2943. Cho MW, Johnston S, Neitzschman HR. Radiology case of the month: 11-year-old girl with intramuscular hemangioma. Intramuscular hemangioma within the right soleus muscle. J La State Med Soc. 2011 Jul-Aug;163(4):234, 6. PMID: 21954659; X-2

2944. Choi GH, Kim KN, Lee S, et al. The clinical features and surgical outcomes of patients with intramedullary spinal cord cavernous malformations. Acta Neurochir (Wien). 2011 Aug;153(8):1677-84; discussion 85. PMID: 21720938; X-1

2945. Chow WC, Ha SY, Chan GCF. Vincristine can induce regression of vascular malformation in long standing refractory Kasabach Merritt phenomenon. Hong Kong Journal of Paediatrics. 2011;16(2):121-4. PMID: 2011235414; X-1

2946. Claerhout I, Buijsrogge M, Delbeke P, et al. The use of propranolol in the treatment of periocular infantile haemangiomas: a review. Br J Ophthalmol. 2011 Sep;95(9):1199-202. PMID: 21131380; X-1

2947. Collins D, Sebire NJ, Barnacle A, et al. 'Mini' free groin flap for treatment of a tufted angioma of the finger. J Plast Reconstr Aesthet Surg. 2011 May;64(5):e128-31. PMID: 21277269; X-1

2948. Cong X, Ludington-Hoe SM, Walsh S. Randomized crossover trial of kangaroo care to reduce biobehavioral pain responses in preterm infants: a pilot study. Biol Res Nurs. 2011 Apr;13(2):204-16. PMID: 21196428; X-1

2949. Corapcioglu F, Buyukkapu-Bay S, Binnetoglu K, et al. Preliminary results of propranolol treatment for patients with infantile hemangioma. Turk J Pediatr. 2011 Mar-Apr;53(2):137-41. PMID: 21853649; X-4

2950. del Pozo J, Lopez-Gutierrez JC, Gomez-Tellado M, et al. Capillary-lymphatic malformation, kaposiform hemangioendothelioma and delayed Kasabach-Merritt phenomenon. Pediatr Dermatol. 2011 Jul-Aug;28(4):439-43. PMID: 20403115; X-1

2951. Dempers J, Wadee SA, Boyd T, et al. Hepatic hemangioendothelioma presenting as sudden unexpected death in infancy: a case report. Pediatr Dev Pathol. 2011 Jan-Feb;14(1):71-4. PMID: 20465426; X-1

2952. Deyrup AT, Miettinen M, North PE, et al. Pediatric cutaneous angiosarcomas: a clinicopathologic study of 10 cases. Am J Surg Pathol. 2011 Jan;35(1):70-5. PMID: 21164289; X-1

2953. Di Pisa M, Chiaramonte G, Arcadipane A, et al. Air embolism during endoscopic retrograde cholangiopancreatography in a pediatric patient. Minerva Anestesiol. 2011 Jan;77(1):90-2. PMID: 21150852; X-1

2954. Dickison P, Christou E, Wargon O. A prospective study of infantile hemangiomas with a focus on incidence and risk factors. Pediatr Dermatol. 2011 Nov-Dec;28(6):663-9. PMID: 21995808; X-3

2955. Draus JM, Jr., Kamel S, Seims A, et al. The role of laparoscopic evaluation to detect a contralateral defect at initial presentation for inguinal hernia repair. Am Surg. 2011 Nov;77(11):1463-6. PMID: 22196658; X-1

2956. Dukatz T, Sarnthein J, Sitter H, et al. Quality of life after brainstem cavernoma surgery in 71 patients. Neurosurgery. 2011 Sep;69(3):689-95. PMID: 21508880; X-1

2957. Dutra AK, Lopes A, Ikeda MK, et al. The role of surgical treatment in orbital vascular anomalies. Aesthetic Plast Surg. 2011 Dec;35(6):1087-96. PMID: 21556982; X-1

2958. Dyer SR, Saraiya S, Sirigiri R, et al. Congenital lobular capillary hemangioma of the larynx: A case report. Int J Pediatr Otorhinolaryngol Extra. 2011 December;6(4):339-45. PMID: 2012060824; X-1, X-2

2959. Eivazi B, Cremer HJ, Mangold C, et al. Hemangiomas of the nasal tip: an approach to a therapeutic challenge. Int J Pediatr Otorhinolaryngol. 2011 Mar;75(3):368-75. PMID: 21208666; X-4

2960. El-Badrawy A, Elzaafarany M, Youssef TF, et al. Role of diffusion-weighted MR imaging in chest wall masses. Egyptian Journal of Radiology and Nuclear Medicine. 2011 June;42(2):147-51. PMID: 2011518000; X-1

2961. El-Essawy R, Galal R, Abdelbaki S. Nonselective beta-blocker propranolol for orbital and periorbital hemangiomas in infants: A new first-line of treatment? Clin Ophthalmol. 2011 17 Nov;5(1):1639-44. PMID: 2012053298; X-4

2962. El-Koussy M, Stepper F, Spreng A, et al. Incidence, clinical presentation and imaging findings of cavernous malformations of the CNS. A twenty-year experience. Swiss Med Wkly. 2011;141:w13172. PMID: 21491213; X-1

2963. Eltaybe AA, Hassen YS. Non invasive management of haemangioma and vascular malformation using intralesional bleomycin injection. Eur Surg. 2011 April;43:19-20. PMID: X-1

2964. Enomoto Y, Yoshimura S, Egashira Y, et al. Transarterial embolization for cervical hemangioma associated with Kasabach-merritt syndrome. Neurol Med Chir (Tokyo). 2011;51(5):375-8. PMID: 21613765; X-2

2965. Fabian ID, Ben-Zion I, Samuel C, et al. Reduction in astigmatism using propranolol as first-line therapy for periocular capillary hemangioma. Am J Ophthalmol. 2011 Jan;151(1):53-8. PMID: 20970771; X-3, X-4

2966. Faraci M, Morana G, Bagnasco F, et al. Magnetic resonance imaging in childhood leukemia survivors treated with cranial radiotherapy: a cross sectional, single center study. Pediatr Blood Cancer. 2011 Aug;57(2):240-6. PMID: 21671360; X-1

2967. Ferreira Rda C, Wolff FR, Morschbacher R. Oral propranolol as a new treatment for facial infantile hemangioma: case report. Arq Bras Oftalmol. 2011 May-Jun;74(3):207-8. PMID: 21915449; X-1, X-2

2968. Fridman G, Grieser E, Hill R, et al. Propranolol for the treatment of orbital infantile hemangiomas. Ophthal Plast Reconstr Surg. 2011 May-Jun;27(3):190-4. PMID: 21283032; X-3, X-4

2969. Fukushima H, Kudo T, Fuskushima T, et al. An infant with life-threatening hemangioma successfully treated with low-dose cyclophosphamide. Pediatr Int. 2011 Dec;53(6):1073-5. PMID: 22181565; X-1

2970. Fussell JN, Wilson T, Pride H. Case report: Congenital dacryocystocele and dacryocystitis. Pediatr Dermatol. 2011 Jan-Feb;28(1):70-2. PMID: 21276064; X-1

2971. Gao W, Qiao X, Ma S, et al. Contribution of skin trauma to infantile skin hemangioma. Med Hypotheses. 2011 Apr;76(4):512-3. PMID: 21220189; X-1, X-2

2972. Gardner R, Dwyer C, Morrison C. MINERVA. Bmj. 2011;343(7821):486-. PMID: X-2

2973. Gaudric A, Krivosic V, Duguid G, et al. Vitreoretinal surgery for severe retinal capillary hemangiomas in von hippel-lindau disease. Ophthalmology. 2011 Jan;118(1):142-9. PMID: 20801520; X-1

2974. Gawley SD, Bingham EA, McGinnity G. Visual outcomes of treated periocular capillary haemangiomas in childhood: a 10-year review. Acta Ophthalmol. 2011 Jun;89(4):396-401. PMID: 20156200; X-4

2975. Ghosh C, Marchi N, Desai NK, et al. Cellular localization and functional significance of CYP3A4 in the human epileptic brain. Epilepsia. 2011 Mar;52(3):562-71. PMID: 21294720; X-1

2976. Ghosh PS, Ghosh D. Infantile intraspinal and extensive cutaneous hemangiomas: excellent response to propranolol. Neurology. 2011 May 17;76(20):1771. PMID: 21576696; X-2

2977. Gidaris D, Economou M, Hatzidemetriou V, et al. Use of propranolol in infantile haemangiomas: Report of five cases and review of the literature. Hippokratia. 2011;15(1):81-3. PMID: 2011057020; X-2

2978. Gonc N, Engiz O, Neumann HP, et al. Two pediatric patients with Von Hippel-Lindau disease type 2b: from patient to screening, from screening to patient. J Pediatr Endocrinol Metab. 2011;24(1-2):109-12. PMID: 21528828; X-1

2979. Goodman SH, Rouse MH, Long Q, et al. Deconstructing antenatal depression: What is it that matters for neonatal behavioral functioning? Infant Ment Health J. 2011 May/June;32(3):339-61. PMID: 2011202018; X-1

2980. Goswamy J, Rothera MP, Bruce IA. Failure of propranolol in the treatment of childhood haemangiomas of the head and neck. J Laryngol Otol. 2011 Nov;125(11):1164-72. PMID: 21846414; X-3, X-4

2981. Greenberger S, Yuan S, Walsh LA, et al. Rapamycin suppresses self-renewal and vasculogenic potential of stem cells isolated from infantile hemangioma. J Invest Dermatol. 2011 Dec;131(12):2467-76. PMID: 21938011; X-1

2982. Greene AK, Liu AS, Mulliken JB, et al. Vascular anomalies in 5,621 patients: guidelines for referral. J Pediatr Surg. 2011 Sep;46(9):1784-9. PMID: 21929990; X-3, X-4

2983. Grimmer JF, Williams MS, Pimentel R, et al. Familial clustering of hemangiomas. Arch Otolaryngol Head Neck Surg. 2011 Aug;137(8):757-60. PMID: 21844408; X-2, X-3

2984. Grover C, Kedar A, Arora P, et al. Efficacy of oral prednisolone use in the treatment of infantile hemangiomas in Indian children. Pediatr Dermatol. 2011 Sep-Oct;28(5):502-6. PMID: 21692837; X-4

2985. Guye E, Chollet-Rivier M, Schroder D, et al. Propranolol treatment for subglottic haemangioma. Arch Dis Child Fetal Neonatal Ed. 2011 Jul;96(4):F263-4. PMID: 21242239; X-2

2986. Haggstrom AN, Skillman S, Garzon MC, et al. Clinical spectrum and risk of PHACE syndrome in cutaneous and airway hemangiomas. Arch Otolaryngol Head Neck Surg. 2011 Jul;137(7):680-7. PMID: 21768412; X-3, X-4

2987. Halilbasic A, Hotic N, Husaric E, et al. Initial experiences with propranolol treatment of infantile hemangiomas: report of three cases. Med Arh. 2011;65(6):380-2. PMID: 22299307; X-3, X-4

2988. Hamidah A, Reena M, Halim AR, et al. Successful treatment of very large congenital infantile fibrosarcoma. Pediatr Int. 2011 Oct;53(5):768-70. PMID: 21955012; X-1

2989. Hammill AM, Wentzel M, Gupta A, et al. Sirolimus for the treatment of complicated vascular anomalies in children. Pediatr Blood Cancer. 2011 Dec 1;57(6):1018-24. PMID: 21445948; X-1

2990. Handra-Luca A, Montgomery E. Vascular malformations and hemangiolymphangiomas of the gastrointestinal tract: morphological features and clinical impact. Int J Clin Exp Pathol. 2011 Jun 20;4(5):430-43. PMID: 21738815; X-1

2991. Hassanein AH, Alomari AI, Schmidt BA, et al. Pilomatrixoma imitating infantile hemangioma. J Craniofac Surg. 2011 Mar;22(2):734-6. PMID: 21415649; X-1

2992. Hermans DJ, van Beynum IM, van der Vijver RJ, et al. Kaposiform hemangioendothelioma with Kasabach-Merritt syndrome: a new indication for propranolol treatment. J Pediatr Hematol Oncol. 2011 May;33(4):e171-3. PMID: 21516018; X-1

2993. Hochman M, Adams DM, Reeves TD. Current knowledge and management of vascular anomalies: I. Hemangiomas. Arch Facial Plast Surg. 2011 May-Jun;13(3):145-51. PMID: 21576660; X-1, X-2

2994. Hoque S, Das BK. Treatment of venous malformations with ethanolamine oleate: a descriptive study of 83 cases. Pediatr Surg Int. 2011 May;27(5):527-31. PMID: 21290138; X-1

2995. Horii KA, Drolet BA, Frieden IJ, et al. Prospective study of the frequency of hepatic hemangiomas in infants with multiple cutaneous infantile hemangiomas. Pediatr Dermatol. 2011 May-Jun;28(3):245-53. PMID: 21517952; X-3

2996. Hospach T, Langendorfer M, Kalle TV, et al. Mimicry of lyme arthritis by synovial hemangioma. Rheumatol Int. 2011 Dec;31(12):1639-43. PMID: 20013264; X-1, X-2

2997. Hou J, Wang M, Tang H, et al. Pingyangmycin sclerotherapy for infantile hemangiomas in oral and maxillofacial regions: an evaluation of 66 consecutive patients. Int J Oral Maxillofac Surg. 2011 Nov;40(11):1246-51. PMID: 21893396; X-3

2998. Hussain K, Makura ZG. Pyriform sinus haemangioma: an unusual presentation of an unusual condition. J Laryngol Otol. 2011 Nov;125(11):1196-8. PMID: 21729438; X-1

2999. Incesoy Ozdemir S, Bozkurt C, Orun UA, et al. Successful treatment of pulmonary arteriovenous malformation and infantile hepatic hemangioendothelioma with alpha-interferon. Anadolu Kardiyol Derg. 2011 Mar;11(2):181-3. PMID: 21362599; X-1, X-2

3000. Itinteang T, Brasch HD, Tan ST, et al. Expression of components of the renin-angiotensin system in proliferating infantile haemangioma may account for the propranolol-induced accelerated involution. J Plast Reconstr Aesthet Surg. 2011 Jun;64(6):759-65. PMID: 20870476; X-1

3001. Jaganathan S, Gamanagatti S, Mukund A, et al. Bleeding scrotal vascular lesions: interventional management with transcatheter embolization. Cardiovasc Intervent Radiol. 2011 Feb;34 Suppl 2:S113-6. PMID: 21052669; X-1

3002. Janmohamed SR, de Waard-van der Spek FB, Madern GC, et al. Scoring the proliferative activity of haemangioma of infancy: the Haemangioma Activity Score (HAS). Clin Exp Dermatol. 2011 Oct;36(7):715-23. PMID: 21933230; X-1, X-2

3003. Janmohamed SR, Madern GC, De Laat PCJ, et al. Haemangioma of infancy: Two case reports with an overdose of propranolol. Case Rep Dermatol. 2011 January-April;3(1):18-21. PMID: 2011292716; X-2

3004. Javia LR, Zur KB, Jacobs IN. Evolving treatments in the management of laryngotracheal hemangiomas: will propranolol supplant steroids and surgery? Int J Pediatr Otorhinolaryngol. 2011 Nov;75(11):1450-4. PMID: 21880377; X-4

3005. Jerjes W, Upile T, Hamdoon Z, et al. Interstitial PDT for vascular anomalies. Lasers Surg Med. 2011 Jul;43(5):357-65. PMID: 21674540; X-1

3006. Jia W, Ma Z, Liu IY, et al. Transcallosal interforniceal approach to pineal region tumors in 150 children. J Neurosurg Pediatr. 2011 Jan;7(1):98-103. PMID: 21194293; X-1

3007. Jiang C, Hu X, Ma G, et al. A prospective self-controlled phase II study of imiquimod 5% cream in the treatment of infantile hemangioma. Pediatr Dermatol. 2011 May-Jun;28(3):259-66. PMID: 21615472; X-3

3008. Jiruska P, Marusic P, Jefferys JG, et al. Sturge-Weber syndrome: a favourable surgical outcome in a case with contralateral seizure onset and myoclonic-astatic seizures. Epileptic Disord. 2011 Mar;13(1):76-81. PMID: 21393095; X-1

3009. Johnson S. as they grow: 0-12 MONTHS. Birthmark Questions. Parents. 2011;86(11):176-9. PMID: X-2

3010. Jones SM, Rahman RS, Bourgeois DJ, 3rd, et al. Hemihyperplasia in a 4-month-old. Clin Pediatr (Phila). 2011 Apr;50(4):367-71. PMID: 21339252; X-1

3011. Jurek T, Czuba M, Smigiel R, et al. Giant heart tumors in infants leading to sudden, unexpected death: description of two cases. Pediatr Int. 2011 Dec;53(6):1090-3. PMID: 22181571; X-1

3012. Kaddah RO, Lotfi U, Haggag M, et al. The role of radiology in the planning management of Klippel Trenaunay Syndrome (KTS). Egyptian Journal of Radiology and Nuclear Medicine. 2011 June;42(2):201-10. PMID: 2011517999; X-1

3013. Khera S, Gupta R. Incidence of thrombocytopenia following phototherapy in hyperbilirubinemic neonates. Med J Armed Forces India. 2011 October;67(4):329-32. PMID: 2011698326; X-1

3014. Kier C, Balluz R, Modi V, et al. Visual diagnosis: respiratory distress: a great masquerader. Pediatr Rev. 2011 Oct;32(10):e95-101. PMID: 21965715; X-2

3015. Kim LH, Hogeling M, Wargon O, et al. Propranolol: useful therapeutic agent for the treatment of ulcerated infantile hemangiomas. J Pediatr Surg. 2011 Apr;46(4):759-63. PMID: 21496551; X-3, X-4

3016. Kim MG, Choi YS, Park SJ, et al. Kaposiform hemangioendothelioma of the breast in an adult female. Clin Breast Cancer. 2011 Apr;11(2):135-7. PMID: 21570000; X-1

3017. Kim YT, Kang SW, Lee JI. Gamma knife radiosurgery for choroidal hemangioma. Int J Radiat Oncol Biol Phys. 2011 Dec 1;81(5):1399-404. PMID: 20950946; X-1

3018. Kirkham FJ, Durnford A, Rodgers W, et al. Inter-rater reliability of engel and ILAE seizure outcome classifications. Epilepsy Curr. 2011;1)PMID: 70831333; X-1

3019. Kivelev J, Laakso A, Niemela M, et al. A proposed grading system of brain and spinal cavernomas. Neurosurgery. 2011 Oct;69(4):807-13; discussion 13-4. PMID: 21508872; X-1

3020. Koay AC, Choo MM, Nathan AM, et al. Combined low-dose oral propranolol and oral prednisolone as first-line treatment in periocular infantile hemangiomas. J Ocul Pharmacol Ther. 2011 Jun;27(3):309-11. PMID: 21542771; X-3, X-4

3021. Kochin IN, Miloh TA, Arnon R, et al. Benign liver masses and lesions in children: 53 cases over 12 years. Isr Med Assoc J. 2011 Sep;13(9):542-7. PMID: 21991714; X-1

3022. Kolokythas A, Al-Ghamian H, Miloro M. Does a difference exist in inferior alveolar canal displacement caused by commonly encountered pathologic entities? An observational study. J Oral Maxillofac Surg. 2011 Jul;69(7):1944-51. PMID: 21419544; X-1

3023. Kosemehmetoglu K, Gedikoglu G, Ruacan S. Morphological and immunohistochemical features of malignant vascular tumors with special emphasis on GLUT1, and FKBP12 expressions. Turk Patoloji Derg. 2011 Jan;27(1):57-67. PMID: 21469428; X-1

3024. Kulungowski AM, Schook CC, Alomari AI, et al. Vascular anomalies of the male genitalia. J Pediatr Surg. 2011 Jun;46(6):1214-21. PMID: 21683225; X-3, X-4

3025. Kuroda T, Kumagai M, Nosaka S, et al. Critical infantile hepatic hemangioma: results of a nationwide survey by the Japanese Infantile Hepatic Hemangioma Study Group. J Pediatr Surg. 2011 Dec;46(12):2239-43. PMID: 22152857; X-3, X-4

3026. Lau K, Massad M, Pollak C, et al. Clinical patterns and outcome in epithelioid hemangioendothelioma with or without pulmonary involvement: insights from an internet registry in the study of a rare cancer. Chest. 2011 Nov;140(5):1312-8. PMID: 21546438; X-1

3027. Lazar DA, Olutoye OO, Moise KJ, Jr., et al. Ex-utero intrapartum treatment procedure for giant neck masses--fetal and maternal outcomes. J Pediatr Surg. 2011 May;46(5):817-22. PMID: 21616233; X-1

3028. Leaute-Labreze C, Prey S, Ezzedine K. Infantile haemangioma: part II. Risks, complications and treatment. J Eur Acad Dermatol Venereol. 2011 Nov;25(11):1254-60. PMID: 21569113; X-1, X-2

3029. Leonardi-Bee J, Batta K, O'Brien C, et al. Interventions for infantile haemangiomas (strawberry birthmarks) of the skin. Cochrane Database Syst Rev. 2011(5)PMID: X-2

3030. Li J, Chen X, Zhao S, et al. Demographic and clinical characteristics and risk factors for infantile hemangioma: a Chinese case-control study. Arch Dermatol. 2011 Sep;147(9):1049-56. PMID: 21576550; X-3

3031. Liang JT, Bao YH, Zhang HQ, et al. Management and prognosis of symptomatic patients with intramedullary spinal cord cavernoma: clinical article. J Neurosurg Spine. 2011 Oct;15(4):447-56. PMID: 21740129; X-1

3032. Lin HK, Wang JD, Fu LS. Recurrent hemarthrosis in a boy with synovial hemangioma: a case report. J Pediatr Orthop B. 2011 Mar;20(2):81-3. PMID: 21088622; X-2

3033. Locke R, Kubba H. The external rhinoplasty approach for congenital nasal lesions in children. Int J Pediatr Otorhinolaryngol. 2011 Mar;75(3):337-41. PMID: 21183230; X-1

3034. Luo Q, Zhao F. How to use bleomycin A5 for infantile maxillofacial haemangiomas: clinical evaluation of 82 consecutive cases. J Craniomaxillofac Surg. 2011 Oct;39(7):482-6. PMID: 20675147; X-3

3035. Luo QF, Zhao FY. The effects of Bleomycin A5 on infantile maxillofacial haemangioma. Head Face Med. 2011;7:11. PMID: 21736714; X-3

3036. Ma J, Shi QL, Jiang SJ, et al. Primary kaposiform hemangioendothelioma of a long bone: two cases in unusual locations with long-term follow up. Pathol Int. 2011 Jun;61(6):382-6. PMID: 21615616; X-1

3037. Mahadevan M, Cheng A, Barber C. Treatment of subglottic hemangiomas with propranolol: initial experience in 10 infants. ANZ J Surg. 2011 Jun;81(6):456-61. PMID: 22295350; X-4

3038. Makdoumi K, Crafoord S. Vasoproliferative retinal tumours in a Swedish population. Acta Ophthalmol. 2011 Feb;89(1):91-4. PMID: 19860770; X-1

3039. Martin MC, Harrington H, Wong WW. Massive congenital kaposiform hemangioendothelioma of the eyelid in a neonate. J Craniofac Surg. 2011 Nov;22(6):e38-41. PMID: 22134318; X-1

3040. Martin TC, Careskey JM, Harle H, et al. Case 1: abdominal pain and coffee ground emesis in a 9-year-old boy. Case 2: vomiting, headache, and seizures in a 7-year-old boy. Case 3: primary amenorrhea in a 15-year-old girl. Pediatr Rev. 2011 May;32(5):209-14. PMID: 21536781; X-1

3041. Mascarenhas R, Guiote V, Agro J, et al. Ulcerated infantile hemangioma treated with imiquimod. Dermatol Online J. 2011;17(9):13. PMID: 21971278; X-2

3042. Masters IB. Stridor in the neonate. Curr Pediatr Rev. 2011 June;7(1):20-32. PMID: 2011249138; X-1

3043. Matsuda S, Sato Y, Marutsuka K, et al. Hemangioma of the umbilical cord with pseudocyst. Fetal Pediatr Pathol. 2011;30(1):16-21. PMID: 21204661; X-1, X-2

3044. Maugans T, Sheridan RM, Adams D, et al. Cutaneous vascular anomalies associated with neural tube defects: nomenclature and pathology revisited. Neurosurgery. 2011 Jul;69(1):112-8; discussion 8. PMID: 21368703; X-3, X-4

3045. Menke J, Schaefer IM. A large liver tumor in a 3-month-old girl. Diagnosis: GLUT1-negative hepatic vascular malformation with capillary proliferation. Gastroenterology. 2011 Jun;140(7):1883, 2151. PMID: 21521642; X-1

3046. Menon G, Gopalakrishnan CV, Rao BR, et al. A single institution series of cavernomas of the brainstem. J Clin Neurosci. 2011 Sep;18(9):1210-4. PMID: 21745743; X-1

3047. Menon RN, Baheti NN, Cherian A, et al. Post-irradiation "acquired cavernous angiomas" with drug resistant seizures. Epilepsy Res. 2011 Sep;96(1-2):161-5. PMID: 21680152; X-1

3048. Mhanna A, Franklin WH, Mancini AJ. Hepatic infantile hemangiomas treated with oral propranolol--a case series. Pediatr Dermatol. 2011 Jan-Feb;28(1):39-45. PMID: 21261702; X-3, X-4

3049. Miebach E, Church H, Cooper A, et al. The craniocervical junction following successful haematopoietic stem cell transplantation for mucopolysaccharidosis type I H (Hurler syndrome). J Inherit Metab Dis. 2011 Jun;34(3):755-61. PMID: 21416193; X-1

3050. Missoi TG, Lueder GT, Gilbertson K, et al. Oral propranolol for treatment of periocular infantile hemangiomas. Arch Ophthalmol. 2011 Jul;129(7):899-903. PMID: 21402978; X-4

3051. Mnif H, Zrig M, Maazoun K, et al. Congenital infantile fibrosarcoma of the forearm. Chir Main. 2011 Apr;30(2):148-51. PMID: 21411358; X-1

3052. Montouris G, Harden C, Alekar S, et al. UCB antiepileptic drug pregnancy Registrykeppra data. Epilepsy Curr. 2011;1)PMID: 70830383; X-1

3053. Morais P, Magina S, Mateus M, et al. Efficacy and safety of propranolol in the treatment of parotid hemangioma. Cutan Ocul Toxicol. 2011 Sep;30(3):245-8. PMID: 21338243; X-2

3054. Morkane C, Gregory JW, Watts P, et al. Adrenal suppression following intralesional corticosteroids for periocular haemangiomas. Arch Dis Child. 2011 Jun;96(6):587-9. PMID: 21321258; X-4

3055. Moskowitz HS, Jaffe R, Hirsch BE. Epithelioid hemangioendothelioma of the middle ear in a child. Am J Otolaryngol. 2011 May-Jun;32(3):259-62. PMID: 20444524; X-1

3056. Mungan S, Turgutalp H, Ersoz S, et al. A rare neoplasm of the testis: capillary hemangioma. Turk Patoloji Derg. 2011 Jan;27(1):80-3. PMID: 21469432; X-1, X-2

3057. Nakamura H, Makino K, Ushio Y, et al. Therapy-associated secondary tumors in patients with non-germinomatous malignant germ cell tumors. J Neurooncol. 2011 Nov;105(2):359-64. PMID: 21533838; X-1

3058. Nale P. Propranolol treatment promising for infantile capillary hemangioma. Ocular Surgery News. 2011;29(10):16-. PMID: X-2

3059. Nandi M, Mondal RK, Chandra PK. A rare case of giant cutaneous and extracutaneous haemangiomas. J Indian Med Assoc. 2011 Jul;109(7):516. PMID: 22315855; X-1, X-2

3060. Navarini S, Bucher B, Pavlovic M, et al. Pulmonary hypertension presenting with apnea, cyanosis, and failure to thrive in a young child. Chest. 2011 Oct;140(4):1086-9. PMID: 21972389; X-1

3061. Nigwekar SP, Nigwekar PV. Atypical presentation of capillary hemangioma of upper eyelid: A case report. Pravara Medical Review. 2011;3(3):34-6. PMID: 2012388372; X-2

3062. Noto R, Maneatis T, Frane J, et al. Intracranial hypertension in pediatric patients treated with recombinant human growth hormone: data from 25 years of the Genentech National Cooperative Growth Study. J Pediatr Endocrinol Metab. 2011;24(9-10):627-31. PMID: 22145447; X-1

3063. Onan B, Haydin S, Onan IS, et al. Giant tumor of the right atrium in infancy. Ann Thorac Surg. 2011 Aug;92(2):737-40. PMID: 21801937; X-2

3064. Oranje AP, Janmohamed SR, Madern GC, et al. Treatment of small superficial haemangioma with timolol 0.5% ophthalmic solution: a series of 20 cases. Dermatology. 2011;223(4):330-4. PMID: 22179543; X-3, X-4

3065. Osifo OD, Evbuomwan I. Hemangiomas in children: Challenges and outcome of surgical management in Benin city, Nigeria. Iran J Pediatr. 2011 Sep;21(3):350-6. PMID: 2011521913; X-3, X-4

3066. Padhi S, Sarangi R, Challa S, et al. A 10-year retrospective study of hemangioblastomas of the central nervous system with reference to von Hippel-Lindau (VHL) disease. J Clin Neurosci. 2011 Jul;18(7):939-44. PMID: 21570297; X-1

3067. Parashette KR, Cuffari C. Sclerotherapy of rectal hemangiomas in a child with Klippel-Trenaunay-Weber syndrome. J Pediatr Gastroenterol Nutr. 2011 Jan;52(1):111-2. PMID: 21057326; X-1

3068. Parhizkar N, Manning SC, Inglis AF, Jr., et al. How airway venous malformations differ from airway infantile hemangiomas. Arch Otolaryngol Head Neck Surg. 2011 Apr;137(4):352-7. PMID: 21242531; X-3, X-4

3069. Pascual-Castroviejo I, Parron Pajares M, Pascual-Pascual SI, et al. Cutaneous, mediastinal and hepatic hemangiomas in a girl followed during 12 years. Neuropediatrics. 2011 Feb;42(1):24-7. PMID: 21557145; X-2

3070. Pastore S, Londero M, Cont G, et al. Refractory iron-deficiency anaemia in a child with portal cavernoma. Gut. 2011 Mar;60(3):317, 77. PMID: 21051450; X-1

3071. Peng Q, Liu W, Zhou F, et al. An experimental study on the therapy of infantile hemangioma with recombinant interferon gamma. J Pediatr Surg. 2011 Mar;46(3):496-501. PMID: 21376199; X-1

3072. Pereira PM, Rodrigues CA, Lima LL, et al. Periorbital hemangiomas: the need for active management - report of two cases. An Bras Dermatol. 2011 May-Jun;86(3):545-8. PMID: 21738973; X-3, X-4

3073. Peridis S, Pilgrim G, Athanasopoulos I, et al. A meta-analysis on the effectiveness of propranolol for the treatment of infantile airway haemangiomas. Int J Pediatr Otorhinolaryngol. 2011 Apr;75(4):455-60. PMID: 21333364; X-1, X-2

3074. Pithon MM, de Andrade AC, de Andrade AP, et al. Sturge-Weber syndrome in an orthodontic patient. Am J Orthod Dentofacial Orthop. 2011 Sep;140(3):418-22. PMID: 21889087; X-1

3075. Prasad R, Johnston LB, Savage MO, et al. Pediatric endocrine screening for von Hippel-Lindau disease: benefits and the challenge of compliance. J Endocrinol Invest. 2011 Apr;34(4):296-9. PMID: 20585202; X-1

3076. Purkait R, Samanta T, Sinhamahapatra T, et al. Overlap of Sturge-Weber syndrome and Klippel-Trenaunay syndrome. Indian J Dermatol. 2011 November-December;56(6):755-7. PMID: 2012063889; X-1

3077. Raiskarami SR, Jafarieh H, Foomani RS, et al. Maffucci's syndrome: A misdiagnosed 9-year-old female patient. Am J Case Rep. 2011;12:35-8. PMID: 2011462481; X-1, X-2

3078. Raol N, Metry D, Edmonds J, et al. Propranolol for the treatment of subglottic hemangiomas. Int J Pediatr Otorhinolaryngol. 2011 Dec;75(12):1510-4. PMID: 21944056; X-3, X-4

3079. Rekhi B, Sethi S, Kulkarni SS, et al. Kaposiform hemangioendothelioma in tonsil of a child associated with cervical lymphangioma: a rare case report. World J Surg Oncol. 2011;9:57. PMID: 21605441; X-1

3080. Remlova E, Dostalova T, Michalusova I, et al. Hemangioma curative effect of PDL, alexandrite, Er:YAG and CO(2) lasers. Photomed Laser Surg. 2011 Dec;29(12):815-25. PMID: 21793735; X-1

3081. Saigal G, Hildoer D, Parra-Herran C, et al. Case report. Unusual presentation of a pancreatic mass in an infant: pancreatic haemangioendotheliomatosis. Br J Radiol. 2011 Dec;84(1008):e232-5. PMID: 22101589; X-1

3082. Sainsbury DC, Kessell G, Fall AJ, et al. Intralesional bleomycin injection treatment for vascular birthmarks: a 5-year experience at a single United Kingdom unit. Plast Reconstr Surg. 2011 May;127(5):2031-44. PMID: 21532430; X-3, X-4

3083. Sakamoto S, Kasahara M, Shigeta T, et al. Living donor liver transplantation for multiple intrahepatic portosystemic shunts after involution of infantile hepatic hemangiomas. J Pediatr Surg. 2011 Jun;46(6):1288-91. PMID: 21683241; X-2

3084. Sanada Y, Mizuta K, Urahashi T, et al. Pediatric living donor liver transplantation using liver allograft with hemangioma. Ann Transplant. 2011 Jan-Mar;16(1):66-9. PMID: 21436777; X-1

3085. Sanz-Marco E, Gallego R, Diaz-Llopis M. Oral propranolol for circumscribed choroidal hemangioma. Case Rep Ophthalmol. 2011 January-April;2(1):84-90. PMID: 2011292884; X-1

3086. Say EA, Shields CL, Bianciotto C, et al. Perilymphatic subcutaneous fat atrophy and cutaneous depigmentation after periocular triamcinolone acetonide injection in a child. J aapos. 2011 Feb;15(1):107-8. PMID: 21397819; X-1

3087. Scheinfeld NS. Dermatologic Look-Alikes. Vascular nodules and papules. Clinical Advisor. 2011;14(7):109-12. PMID: X-2

3088. Schneider D, Lee MS, Harrison AR, et al. Excision of periorbital hemangiomas to correct visual abnormalities. Arch Facial Plast Surg. 2011 May-Jun;13(3):195-8. PMID: 21576666; X-4

3089. Sciveres M, Marrone G, Pipitone S, et al. Successful first-line treatment with propranolol of multifocal infantile hepatic hemangioma with high-flow cardiac overload. J Pediatr Gastroenterol Nutr. 2011 Dec;53(6):693-5. PMID: 21519284; X-2

3090. Sharma J, Hsu D, Weinstein S. Obstructive right ventricular outflow tract hemangioma in an adolescent. Congenit Heart Dis. 2011 Nov-Dec;6(6):657-60. PMID: 21702885; X-1, X-2

3091. Shayan YR, Prendiville JS, Goldman RD. Use of propranolol in treating hemangiomas. Can Fam Physician. 2011 Mar;57(3):302-3. PMID: 21402965; X-2

3092. Shields JA, Mashayekhi A, Kligman BE, et al. Vascular tumors of the conjunctiva in 140 cases. Ophthalmology. 2011 Sep;118(9):1747-53. PMID: 21788081; X-1

3093. Shukla S, Acharya N, Acharya S, et al. Kasabach merrit syndrome in a third trimester pregnancy. Journal of Medicine. 2011;12(1):66-9. PMID: 2011082890; X-1

3094. Singh P, Mishra NK, Dash HH, et al. Treatment of vertebral hemangiomas with absolute alcohol (ethanol) embolization, cord decompression, and single level instrumentation: a pilot study. Neurosurgery. 2011 Jan;68(1):78-84; discussion PMID: 21099721; X-1

3095. Solomon T, Ninnis J, Deming D, et al. Use of propranolol for treatment of hemangiomas in PHACE syndrome. J Perinatol. 2011 Nov;31(11):739-41. PMID: 22037156; X-1, X-2

3096. Soltani AM, Reinisch JF. Algorithmic approach to the management of hemangiomas. J Craniofac Surg. 2011 Mar;22(2):585-8. PMID: 21403532; X-1, X-2

3097. Sood D, Mohan N, Singh A, et al. Living donor liver transplantation for giant cavernous hemangioma of liver in a child. Pediatr Transplant. 2011 Nov;15(7):E135-8. PMID: 20598089; X-1

3098. Steno J, Bizik I, Stenova J, et al. Subtemporal transtentorial resection of cavernous malformations involving the pyramidal tract in the upper pons and mesencephalon. Acta Neurochir (Wien). 2011 Oct;153(10):1955-62; discussion 62. PMID: 21845370; X-1

3099. Suh KY, Rosbe KW, Meyer AK, et al. Extensive airway hemangiomas in two patients without beard hemangiomas. Pediatr Dermatol. 2011 May-Jun;28(3):347-8. PMID: 20561239; X-3, X-4

3100. Tadrous R, Ni Mhuirchteagh R, McCaul C. Anaesthesia for caesarean section in a patient with Sturge-Weber syndrome following acute neurological deterioration. Int J Obstet Anesth. 2011 Jul;20(3):259-62. PMID: 21315576; X-1

3101. Takemoto J, Yamazaki Y, Sakai K. A case of large bladder hemangioma successfully treated with endoscopic yttrium aluminium garnet laser irradiation. Int J Urol. 2011 Dec;18(12):854-6. PMID: 22142464; X-1

3102. Tallen G, Hernaiz Driever P, Degenhardt P, et al. High reliability of scrotal ultrasonography in the management of childhood primary testicular neoplasms. Klin Padiatr. 2011 May;223(3):131-7. PMID: 21462100; X-1

3103. Talmon GA, Stanley SM, Lager DJ. Capillary hemangioma of the testis. Int J Surg Pathol. 2011 Jun;19(3):398-400. PMID: 19147509; X-1, X-2

3104. Tan BH, Leadbitter PH, Aburn NH, et al. Steroid therapy for problematic proliferating haemangioma. N Z Med J. 2011 Feb 11;124(1329):57-65. PMID: 21475361; X-4

3105. Tan ST, Itinteang T, Leadbitter P. Low-dose propranolol for multiple hepatic and cutaneous hemangiomas with deranged liver function. Pediatrics. 2011 Mar;127(3):e772-6. PMID: 21357335; X-2

3106. Tan ST, Itinteang T, Leadbitter P. Low-dose propranolol for infantile haemangioma. J Plast Reconstr Aesthet Surg. 2011 Mar;64(3):292-9. PMID: 20615772; X-4

3107. Tandon A, Jain B, Tandon R, et al. Infantile Hemangioendothelioma of the Parotid Gland: A Sonographic Diagnosis. Journal of Diagnostic Medical Sonography. 2011;27(3):131-4. PMID: X-1

3108. Tang V, Daneman A, Navarro OM, et al. Internal hernias in children: spectrum of clinical and imaging findings. Pediatr Radiol. 2011 Dec;41(12):1559-68. PMID: 21735180; X-1

3109. Tarantino CC, Vercelli A, Canepari E. Angioma of the chest wall: A report of 2 cases. J Ultrasound. 2011 March;14(1):18-21. PMID: 2011117029; X-1

3110. Tlougan BE, Gonzalez ME, Orlow SJ. Abortive segmental perineal hemangioma. Dermatol Online J. 2011;17(10):8. PMID: 22031634; X-1, X-2

3111. Tolar J, Park IH, Xia L, et al. Hematopoietic differentiation of induced pluripotent stem cells from patients with mucopolysaccharidosis type I (Hurler syndrome). Blood. 2011 Jan 20;117(3):839-47. PMID: 21037085; X-1

3112. Tomazic PV, Stammberger H, Habermann W, et al. Intraoperative medialization of medial rectus muscle as a new endoscopic technique for approaching intraconal lesions. Am J Rhinol Allergy. 2011 Sep-Oct;25(5):363-7. PMID: 22186253; X-1

3113. Tsang FH, Lun KS, Cheng LC. Hemangioma of the diaphragm presenting with cardiac tamponade. J Card Surg. 2011 Nov;26(6):620-3. PMID: 22004551; X-1, X-2

3114. Vasaiwala R, Sajja K, Setabutr P. Novel management of the microphthalmic orbit in a patient with PHACE syndrome. Ophthal Plast Reconstr Surg. 2011 Nov-Dec;27(6):e156-8. PMID: 21629142; X-2

3115. Velayudam K, Paolicchi J. Wolf - Hirschhorn syndrome presenting with intractable epilepsy and distinct unilateral cutaneous finding: A case report. Epilepsy Curr. 2011;1)PMID: 70830360; X-1

3116. Verdegaal SH, Bovee JV, Pansuriya TC, et al. Incidence, predictive factors, and prognosis of chondrosarcoma in patients with Ollier disease and Maffucci syndrome: an international multicenter study of 161 patients. Oncologist. 2011;16(12):1771-9. PMID: 22147000; X-1

3117. Vinchon M, Leblond P, Caron S, et al. Radiation-induced tumors in children irradiated for brain tumor: a longitudinal study. Childs Nerv Syst. 2011 Mar;27(3):445-53. PMID: 21234575; X-1

3118. Weibel L. Vascular anomalies in children. Vasa. 2011 Nov;40(6):439-47. PMID: 22090176; X-1, X-2

3119. Weiss I, O TM, Lipari BA, et al. Current treatment of parotid hemangiomas. Laryngoscope. 2011 Aug;121(8):1642-50. PMID: 21766313; X-3, X-4

3120. Wester ST, Johnson TE. Echographic evidence of regression of a periocular infantile capillary hemangioma treated with systemic propranolol. Ophthalmic Surg Lasers Imaging. 2011;42 Online:e18-21. PMID: 21323190; X-2

3121. Williams K, Woolf R, Morrison D. Periocular lesion in an infant. Bmj. 2011;343:d7461. PMID: 22123913; X-2

3122. Wind JJ, Bakhtian KD, Sweet JA, et al. Long-term outcome after resection of brainstem hemangioblastomas in von Hippel-Lindau disease. J Neurosurg. 2011 May;114(5):1312-8. PMID: 20932100; X-1

3123. Winland RD. Something is better than nothing. AGD Impact. 2011;39(6):4-. PMID: X-1

3124. Wou K, Chen MF, Mallozzi A, et al. Pregnancy outcomes and ultrasonographic diagnosis in patients with histologically-proven placental chorioangioma. Placenta. 2011 Sep;32(9):671-4. PMID: 21745690; X-1

3125. Wu J, Tarabishy B, Hu J, et al. Cortical calcification in Sturge-Weber Syndrome on MRI-SWI: relation to brain perfusion status and seizure severity. J Magn Reson Imaging. 2011 Oct;34(4):791-8. PMID: 21769978; X-1

3126. Xu D, O TM, Shartava A, et al. Isolation, characterization, and in vitro propagation of infantile hemangioma stem cells and an in vivo mouse model. J Hematol Oncol. 2011;4:54. PMID: 22192404; X-1

3127. Ye C, Pan L, Huang Y, et al. Somatic mutations in exon 17 of the TEK gene in vascular tumors and vascular malformations. J Vasc Surg. 2011 Dec;54(6):1760-8. PMID: 21962923; X-1

3128. Ye CS, Pan LX, Huang YB, et al. Clinical analysis of vascular anomalies: a hospital-based retrospective study of 592 patients in southeast China. Chin Med J (Engl). 2011 Oct;124(19):3008-12. PMID: 22040545; X-3, X-4

3129. Yeh I, Bruckner AL, Sanchez R, et al. Diffuse infantile hepatic hemangiomas: a report of four cases successfully managed with medical therapy. Pediatr Dermatol. 2011 May-Jun;28(3):267-75. PMID: 21517953; X-3, X-4

3130. Yilmaz KB, Canter HI, Vargel I, et al. Use of three-dimensional MRI-angiography in preoperative evaluation and postoperative management of hemangiomas of head and neck region. J Craniofac Surg. 2011 Sep;22(5):1814-8. PMID: 21959441; X-2

3131. Yousefi P, Cyrus A, Dorreha F, et al. Effect of hydrochlorothiazide on reducing recurrent abdominal pain in girls with idiopathic hypercalciuria. J Res Med Sci. 2011;16(SPEC. ISSUE):433-6. PMID: 2011241671; X-1

3132. Yu L, Yang SJ. Kaposiform hemangioendothelioma of the spleen in an adult: an initial case report. Pathol Oncol Res. 2011 Dec;17(4):969-72. PMID: 21190143; X-1

3133. Yucel E, Akkaya H, Gurkanlar D, et al. Congenital cavernous hemangioma of the skull. Turk Neurosurg. 2011;21(4):645-7. PMID: 22194130; X-1

3134. Zur E. Infantile hemangiomas, part 2: topical treatment with beta blockers. Int J Pharm Compd. 2011;15(6):458-63. PMID: X-1, X-2

3135. Zur E. Infantile Hemangiomas, Part 1: Treatment with Oral Propranolol Hydrochloride. Int J Pharm Compd. 2011;15(5):358-66. PMID: X-2

3136. . Derm Dx. Clinical Advisor. 2012;15(6):53-. PMID: X-5

3137. . Endgames. Bmj. 2012;344(7842):56-46. PMID: X-2

3138. Abdellatif A. Ultrasound-guided ilioinguinal/iliohypogastric nerve blocks versus caudal block for postoperative analgesia in children undergoing unilateral groin surgery. Saudi J Anaesth. 2012 October-December;6(4):367-72. PMID: 2013101537; X-1

3139. Adeyiga AO, Lee EY, Eisenberg RL. Focal hepatic masses in pediatric patients. AJR Am J Roentgenol. 2012 Oct;199(4):W422-40. PMID: 22997391; X-1

3140. Adhisivam B, Femitha P, Joy R, et al. Born with a balloon. J Pediatr. 2012 Aug;161(2):366-.e1. PMID: 22494874; X-1, X-2

3141. Admani S, Krakowski AC, Nelson JS, et al. Beneficial effects of early pulsed dye laser therapy in individuals with infantile hemangiomas. Dermatol Surg. 2012 Oct;38(10):1732-8. PMID: 22776100; X-3, X-4

3142. Ajler P, Goldschmidt E, Bendersky D, et al. Sellar hemangioblastoma mimicking a macroadenoma. Acta Neurol Taiwan. 2012 Dec;21(4):176-9. PMID: 23329549; X-1

3143. Akcay A, Karakas Z, Saribeyoglu ET, et al. Infantile hemangiomas, complications and follow-up. Indian Pediatr. 2012 Oct;49(10):805-9. PMID: 22791668; X-3, X-4

3144. Akhtar S, Shamim AA, Ghaffar S, et al. Adult laryngeal haemangioma; a rare entity. J Pak Med Assoc. 2012 Feb;62(2):173-4. PMID: 22755385; X-1

3145. Albinana V, Recio-Poveda L, Zarrabeitia R, et al. Propranolol as antiangiogenic candidate for the therapy of hereditary haemorrhagic telangiectasia. Thromb Haemost. 2012 Jul;108(1):41-53. PMID: 22552254; X-1

3146. Alcantara Gonzalez J, Boixeda P, Truchuelo Diez MT, et al. Ablative fractional yttrium-scandium-gallium-garnet laser for scarring residual haemangiomas and scars secondary to their surgical treatment. J Eur Acad Dermatol Venereol. 2012 Apr;26(4):477-82. PMID: 21564327; X-4

3147. Aletaha M, Salour H, Bagheri A, et al. Successful treatment of orbital hemangioma with propranolol in a 5-year-old girl. Orbit. 2012 Feb;31(1):18-20. PMID: 22132796; X-1, X-2

3148. Al-Holou WN, O'Lynnger TM, Pandey AS, et al. Natural history and imaging prevalence of cavernous malformations in children and young adults. J Neurosurg Pediatr. 2012 Feb;9(2):198-205. PMID: 22295927; X-1

3149. Alsuwaidan S. PHACES syndrome in association with airway hemangioma: First report from Saudi Arabia and literature review. Ann Thorac Med. 2012 January-March;7(1):44-7. PMID: 2012074391; X-2

3150. Altin H, Alp H, Sap F, et al. PHACE syndrome with growth hormone deficiency and absence of bilateral internal carotid arteries: a case report. Pediatr Dermatol. 2012 May-Jun;29(3):316-9. PMID: 22010790; X-1, X-2

3151. Ammerman RT, Peugh JL, Putnam FW, et al. Predictors of treatment response in depressed mothers receiving in-home cognitive-behavioral therapy and concurrent home visiting. Behav Modif. 2012 Jul;36(4):462-81. PMID: 22718282; X-1

3152. Ang M, Lee SY. Multifocal photodynamic therapy for diffuse choroidal hemangioma. Clin Ophthalmol. 2012 06 Sep;6(1):1467-9. PMID: 2012571309; X-1

3153. Annagur A, Altunhan H, Konak M, et al. Successful use of topical "Ankaferd Blood Stopper" for repetitive bleedings in an infant with infantile hemangioma. Int J Clin Exp Med. 2012 15 Sep;5(4):342-5. PMID: 2012532199; X-2

3154. Attash SM, Ali MS, Al-Nuaimy HA. Isolated cavernous haemangioma of the stomach in a 3-year-old child: an unusual cause of upper GI bleeding. BMJ Case Rep. 2012;2012PMID: 23045447; X-1

3155. Avallone AN, Avallone MA, Share S, et al. Epithelioid hemangioma-a rare scrotal tumor of childhood. Urology. 2012 Sep;80(3):707-9. PMID: 22698477; X-2

3156. Baird C, Blalock S, Bengur R, et al. Right atrial hemangioma in the newborn: Utility of fetal imaging. Ann Pediatr Cardiol. 2012 January-June;5(1):81-4. PMID: 2012177443; X-1

3157. Bartosiewicz K, Tuziak M, Stecewicz I, et al. Klippel-trenaunay syndrome as a cause of the lower extremities enlargement in infants - a diagnostic dilemma

Zespol Klippel-Trenaunay'A Jako Jedna Z Przyczyn Przerostu Konczyn U Niemowla{ogonek}t - Trudnosci Diagnostyczne. Przeglad Pediatryczny. 2012;42(3):157-9. PMID: 2013039267; X-1, X-2

3158. Bauland CG, Smit JM, Scheffers SM, et al. Similar risk for hemangiomas after amniocentesis and transabdominal chorionic villus sampling. J Obstet Gynaecol Res. 2012 Feb;38(2):371-5. PMID: 22229643; X-1, X-3

3159. Behr GG, Fishman SJ, Caty MG, et al. Hepatic mesenchymal hamartoma and infantile hemangioma: a rare association. J Pediatr Surg. 2012 Mar;47(3):448-52. PMID: 22424336; X-1, X-3

3160. Ben-Amitai D, Halachmi S, Zvulunov A, et al. Hemangiomas of the nasal tip treated with propranolol. Dermatology. 2012;225(4):371-5. PMID: 23428617; X-4

3161. Betlloch-Mas I, Martinez-Miravete MT, Lucas-Costa A, et al. Outpatient treatment of infantile hemangiomas with propranolol: a prospective study. Actas Dermosifiliogr. 2012 Nov;103(9):806-15. PMID: 22727954; X-4

3162. Bieniek R, Godzinski J, Bieniek A. The treatment of infantile hemangiomas, Leczenie naczyniakow krwionosnych dzieciecych. [Polish, English]. Przegl Dermatol. 2012;99 (4):420. PMID: 71001876; X-6

3163. Bingham MM, Saltzman B, Vo NJ, et al. Propranolol reduces infantile hemangioma volume and vessel density. Otolaryngol Head Neck Surg. 2012 Aug;147(2):338-44. PMID: 22691693; X-3, X-4

3164. Bonifazi E. Juvenile xanthogranuloma regresses more rapidly than hemangioma. European Journal of Pediatric Dermatology. 2012 July-September;22(3):225. PMID: 2013012370; X-1

3165. Bonniaud B, Martin SP, Bonnet C, et al. Safe treat ment of infantile haemangiomas with propranolol despite baseline bradycardia. European Journal of Pediatric Dermatology. 2012 March;22 (1):38-9. PMID: 70795428; X-4

3166. Bozena DB. HEMANGIOL STUDY: The first worldwide dose-effect study concerning propranolol in infantile hemangiomas, Badanie HEMANGIOL - pierwsze ogolnoswiatowe badanie zaleznosci dawka-efekt dotyczace stosowania propranololu u pacjentow z naczyniakami niemowlecymi. [Polish, English]. Przegl Dermatol. 2012;99 (4):419. PMID: 71001875; X-6

3167. Bruscino N, Bonan P, Cannarozzo G, et al. Laser use in infantile hemangiomas, when and how. Dermatol Ther. 2012 Jul-Aug;25(4):314-21. PMID: 22950558; X-1, X-2

3168. Burroni L, Borsari G, Pichierri P, et al. Preoperative diagnosis of orbital cavernous hemangioma: a 99mTc-RBC SPECT study. Clin Nucl Med. 2012 Nov;37(11):1041-6. PMID: 23047756; X-1

3169. Callahan AB, Yoon MK. Infantile hemangiomas: A review. Saudi J Ophthalmol. 2012 July;26(3):283-91. PMID: 2012477252; X-1, X-2

3170. Cavalli R, Buffon RB, de Souza M, et al. Tumor lysis syndrome after propranolol therapy in ulcerative infantile hemangioma: rare complication or incidental finding? Dermatology. 2012;224(2):106-9. PMID: 22516868; X-2

3171. Chang CS, Wong A, Rohde CH, et al. Management of lip hemangiomas: Minimizing peri-oral scars. J Plast Reconstr Aesthet Surg. 2012 Feb;65(2):163-8. PMID: 21937296; X-3, X-4

3172. Chang YT, Lin JY, Lee JY, et al. Comparative mid-term results between inguinal herniotomy and single-port laparoscopic herniorrhaphy for pediatric inguinal hernia. Surg Laparosc Endosc Percutan Tech. 2012 Dec;22(6):526-31. PMID: 23238381; X-1

3173. Charters L. Beta-blocker explored. Ophthalmology Times. 2012;37(7):22-. PMID: X-1

3174. Chaudry MI, Manzoor MU, Turner RD, et al. Diagnostic imaging of vascular anomalies. Facial Plast Surg. 2012 Dec;28(6):563-74. PMID: 23188683; X-1

3175. Chim H, Armijo BS, Miller E, et al. Propranolol induces regression of hemangioma cells through HIF-1alpha-mediated inhibition of VEGF-A. Ann Surg. 2012 Jul;256(1):146-56. PMID: 22580939; X-1, X-3

3176. Chisholm KM, Chang KW, Truong MT, et al. beta-Adrenergic receptor expression in vascular tumors. Mod Pathol. 2012 Nov;25(11):1446-51. PMID: 22743651; X-1

3177. Chisti M, Banka N, Alfadley A. Pallor sign: an indicator of hemangioma in evolution. J Cutan Med Surg. 2012 Nov-Dec;16(6):451-2. PMID: 23149206; X-2

3178. Chiu YE, Drolet BA, Blei F, et al. Variable response to propranolol treatment of kaposiform hemangioendothelioma, tufted angioma, and Kasabach-Merritt phenomenon. Pediatr Blood Cancer. 2012 Nov;59(5):934-8. PMID: 22648868; X-1

3179. Christou EM, Wargon O. Effect of captopril on infantile haemangiomas: a retrospective case series. Australas J Dermatol. 2012 Aug;53(3):216-8. PMID: 22671578; X-4

3180. Chun YH, Moon CJ, Yoon JS, et al. Successful treatment of infantile subglottic hemangioma with oral propranolol. Clin Pediatr (Phila). 2012 Oct;51(10):983-6. PMID: 21642231; X-3, X-4

3181. Chung SH, Park DH, Jung HL, et al. Successful and safe treatment of hemangioma with oral propranolol in a single institution. Korean J Pediatr. 2012 May;55(5):164-70. PMID: 2012460883; X-4

3182. Cichon K, Schon CA. Influences on the amount of intraperitoneal haemorrhage after blunt liver injury: a retrospective autopsy study. Eur J Gastroenterol Hepatol. 2012 Nov;24(11):1333-40. PMID: 22872075; X-1

3183. Cobb AR, Sebire NJ, Anderson J, et al. Congenital malignant rhabdoid tumor of the scalp. J Craniomaxillofac Surg. 2012 Dec;40(8):e258-60. PMID: 22079123; X-1

3184. Couto RA, Maclellan RA, Zurakowski D, et al. Infantile hemangioma: clinical assessment of the involuting phase and implications for management. Plast Reconstr Surg. 2012 Sep;130(3):619-24. PMID: 22575857; X-3, X-4

3185. Dai Y, Hou F, Buckmiller L, et al. Decreased eNOS protein expression in involuting and propranolol-treated hemangiomas. Arch Otolaryngol Head Neck Surg. 2012 Feb;138(2):177-82. PMID: 22351865; X-1

3186. Dalmonte P, Granata C, Fulcheri E, et al. Intra-articular venous malformations of the knee. J Pediatr Orthop. 2012 Jun;32(4):394-8. PMID: 22584841; X-1

3187. Daramola OO, Chun RH, Kerschner JE. Surgical management of auricular infantile hemangiomas. Arch Otolaryngol Head Neck Surg. 2012 Jan;138(1):72-5. PMID: 22249633; X-4

3188. de Oliveira DA, Valenca MM. The characteristics of head pain in response to an experimental cold stimulus to the palate: An observational study of 414 volunteers. Cephalalgia. 2012 Nov;32(15):1123-30. PMID: 22914815; X-1

3189. Denzer F, Denzer C, Lennerz BS, et al. A case of phace syndrome and acquired hypopituitarism? Int J Pediatr Endocrinol. 2012 30 Jun;2012(1)PMID: 2013284704; X-2

3190. Di Fiore JM, Kaffashi F, Loparo K, et al. The relationship between patterns of intermittent hypoxia and retinopathy of prematurity in preterm infants. Pediatr Res. 2012 Dec;72(6):606-12. PMID: 23037873; X-1

3191. Dilek N, Ustuner P, Saral Y. Solitar Y fa UN tail nevus without spinal dysraphism: A case report. European Journal of Pediatric Dermatology. 2012 March;22 (1):19. PMID: 70795390; X-1

3192. Dinand V, Yadav SP, Bellanne-Chantelot C, et al. Hepatic hemangioendothelioma in an infant with severe congenital neutropenia. J Pediatr Hematol Oncol. 2012 May;34(4):298-300. PMID: 22510773; X-1

3193. Doege C, Pritsch M, Fruhwald MC, et al. An association between infantile haemangiomas and erythropoietin treatment in preterm infants. Arch Dis Child Fetal Neonatal Ed. 2012 Jan;97(1):F45-9. PMID: 21546402; X-3

3194. Drolet BA, Pope E, Juern AM, et al. Gastrointestinal bleeding in infantile hemangioma: a complication of segmental, rather than multifocal, infantile hemangiomas. J Pediatr. 2012 Jun;160(6):1021-6.e3. PMID: 22240112; X-3, X-4

3195. Durr ML, Meyer AK, Huoh KC, et al. Airway hemangiomas in PHACE syndrome. Laryngoscope. 2012 Oct;122(10):2323-9. PMID: 22865344; X-3, X-4

3196. Dyme JL, Thampan A, Han EJ, et al. Propranolol for infantile haemangiomas: initiating treatment on an outpatient basis. Cardiol Young. 2012 Aug;22(4):424-9. PMID: 22166728; X-4

3197. Engelmann C, Mutschler U, Zoller C, et al. Systematic assessment of propranolol therapy of infancy hemangiomas. A new online tool. Monatsschr Kinderheilkd. 2012 August;160:60. PMID: 70915023; X-5

3198. Ercan CM, Coksuer H, Karasahin KE, et al. Combined approach in a large placental chorioangioma case with intratumoral alcohol injection, cordocentesis, IU transfusion, and amnioreduction. Fetal Pediatr Pathol. 2012 Dec;31(6):374-8. PMID: 22432544; X-1

3199. Feng J, Wu Q, Zhang D, et al. Hippocampal impairments are associated with intermittent hypoxia of obstructive sleep apnea. Chin Med J (Engl). 2012 Feb;125(4):696-701. PMID: 22490498; X-1

3200. Feng Y, Ma Z. Transscleral diode photocoagulation of large retinal and choroidal vascular lesions. PLoS One. 2012;7(7):e39340. PMID: 22792170; X-1

3201. Figueiredo LM, Trindade SC, Sarmento VA, et al. Extensive gingival hemangioma in a 10-year-old boy treated by sclerotherapy: a case report. J Oral Maxillofac Surg. 2012 Nov;70(11):2585-9. PMID: 22305874; X-1, X-2

3202. Franchi-Abella S, Gorincour G, Avni F, et al. Hepatic haemangioma-prenatal imaging findings, complications and perinatal outcome in a case series. Pediatr Radiol. 2012 Mar;42(3):298-307. PMID: 21928049; X-3, X-4

3203. Freeman I, Ganesan K, Emmerson AJ. Kasabach-Merritt syndrome in a term neonate. Arch Dis Child Fetal Neonatal Ed. 2012 Mar;97(2):F139-40. PMID: 21697235; X-1, X-2

3204. Fuchimoto Y, Morikawa N, Kuroda T, et al. Vincristine, actinomycin D, cyclophosphamide chemotherapy resolves Kasabach-Merritt syndrome resistant to conventional therapies. Pediatr Int. 2012 Apr;54(2):285-7. PMID: 22507155; X-1

3205. Garcia-Monaco R, Giachetti A, Peralta O, et al. Kaposiform hemangioendothelioma with Kasabach-Merritt phenomenon: successful treatment with embolization and vincristine in two newborns. J Vasc Interv Radiol. 2012 Mar;23(3):417-22. PMID: 22365299; X-1

3206. Garcia-Nieto V, Monge-Zamorano M, Gonzalez-Garcia M, et al. Effect of thiazides on bone mineral density in children with idiopathic hypercalciuria. Pediatr Nephrol. 2012 Feb;27(2):261-8. PMID: 21874585; X-1

3207. Gawrych E, Walecka A, Kwas A, et al. Coexistence of splenic hemangioma and vascular malformation of the lower extremity in a child: a case report. Turk J Pediatr. 2012 Jul-Aug;54(4):436-9. PMID: 23692730; X-1, X-2

3208. Ginat DT, Meyers SP. Intracranial lesions with high signal intensity on T1-weighted MR images: differential diagnosis. Radiographics. 2012 Mar-Apr;32(2):499-516. PMID: 22411945; X-1

3209. Grimmer JF, Williams MS, Pimentel R, et al. Hemangioma is associated with atopic disease. Otolaryngol Head Neck Surg. 2012 Feb;146(2):206-9. PMID: 22031593; X-3

3210. Gross BC, Janus JR, Orvidas LJ. Response of infantile airway and facial hemangiomas to propranolol in a patient with PHACE syndrome. Int J Pediatr Otorhinolaryngol Extra. 2012 December;7(4):183-9. PMID: 2012745994; X-2

3211. Haddy N, Mousannif A, Paoletti C, et al. Radiotherapy as a risk factor for malignant melanoma after childhood skin hemangioma. Melanoma Res. 2012 Feb;22(1):77-85. PMID: 22082956; X-1

3212. Haggstrom AN, Beaumont JL, Lai JS, et al. Measuring the severity of infantile hemangiomas: instrument development and reliability. Arch Dermatol. 2012 Feb;148(2):197-202. PMID: 22351819; X-1

3213. Harjai MM, Jha M. Intralesional bleomycin and sodium tetradecyl sulphate for haemangiomas and lymphangiomas. Afr J Paediatr Surg. 2012 Jan-Apr;9(1):47-51. PMID: 22382104; X-4

3214. Haugen TW, Wood WE, Helwig C. Postcricoid vascular abnormalities: hemangiomas, venous malformations, or anatomic variant. Int J Pediatr Otorhinolaryngol. 2012 Jun;76(6):805-8. PMID: 22424609; X-1

3215. Heah SS, Ng SY, Leong KF, et al. Two cases of congenita l haemangiomas with serious complications. European Journal of Pediatric Dermatology. 2012 March;22 (1):42-3. PMID: 70795437; X-2

3216. Hiraoka K, Mota De Queiroz A, Aparecida Marinho S, et al. Sclerotherapy with monoethanolamine oleate in benign oral vascular lesions. Minerva Stomatol. 2012 Jan-Feb;61(1-2):31-6. PMID: 22274308; X-1

3217. Hom S, Modi V, Chandran L, et al. Stridor in the neonate. Contemp Pediatr. 2012;29(2):42-7. PMID: X-2

3218. Hong E, Fischer G. Propranolol for recalcitrant ulcerated hemangioma of infancy. Pediatr Dermatol. 2012 Jan-Feb;29(1):64-7. PMID: 21854419; X-3, X-4

3219. Hoornweg MJ, Smeulders MJ, Ubbink DT, et al. The prevalence and risk factors of infantile haemangiomas: a case-control study in the Dutch population. Paediatr Perinat Epidemiol. 2012 Mar;26(2):156-62. PMID: 22324502; X-3

3220. Hsu TC, Wang JD, Chen CH, et al. Treatment with propranolol for infantile hemangioma in 13 Taiwanese newborns and young infants. Pediatr Neonatol. 2012 Apr;53(2):125-32. PMID: 22503260; X-4

3221. Imteyaz H, Karnsakul W, Levine MA, et al. Unusual case of hypothyroidism in an infant with hepatic hemangioma. J Pediatr Gastroenterol Nutr. 2012 May;54(5):692-5. PMID: 21716131; X-1, X-2

3222. Jahnel J, Lackner H, Reiterer F, et al. Kaposiform hemangioendothelioma with Kasabach-Merritt phenomenon: from vincristine to sirolimus. Klin Padiatr. 2012 Oct;224(6):395-7. PMID: 23070861; X-1

3223. Jain V, Roychoudhury S, Chadha R, et al. Variable response to propranolol therapy for infantile hemangiomas. Indian J Dermatol. 2012 March-April;57(2):126-7. PMID: 2012255909; X-2

3224. James CA, Schwartz DR, Roberts KE, et al. Childhood Emotional Abuse and Psychological Distress in Gay and Bisexual Men. J Aggress Maltreat Trauma. 2012;21(8):851-69. PMID: X-1

3225. Ji Y, Li K, Xiao X, et al. Effects of propranolol on the proliferation and apoptosis of hemangioma-derived endothelial cells. J Pediatr Surg. 2012 Dec;47(12):2216-23. PMID: 23217879; X-1

3226. Jiang RS, Hu R. Successful treatment of Kasabach-Merritt syndrome arising from kaposiform hemangioendothelioma by systemic corticosteroid therapy and surgery. Int J Clin Oncol. 2012 Oct;17(5):512-6. PMID: 21947597; X-1

3227. Kalicki B, Jung A, Ring F, et al. Infrared thermography assessment of infantile hemangjoma treatment by propanolol. Thermology International. 2012 July;22 (3):102-3. PMID: 70892439; X-3, X-4

3228. Kalicki B, Jung A, Rustecka A, et al. Evaluation of skin changes using infrared thermography. Thermology International. 2012 April;22 (2):69-70. PMID: 70824527; X-5

3229. Kalicki B, Jung A, Rustecka A, et al. Infantile hemangiomas - The possibility of using infrared thermography in the assessment of propranolol efficacy-preliminary study. Thermology International. 2012 April;22 (2):71. PMID: 70824529; X-5

3230. Katona G, Csakanyi Z, Gacs E, et al. Propranolol for infantile haemangioma: striking effect in the first weeks. Int J Pediatr Otorhinolaryngol. 2012 Dec;76(12):1746-50. PMID: 22944359; X-4

3231. Keating LJ, Soares GM, Muratore CS. Rapidly involuting congenital hemangioma. Med Health R I. 2012 May;95(5):149, 52. PMID: 22808633; X-1

3232. Kelly JB, 3rd, Makkar HS. Ethics in pediatric dermatology. Clin Dermatol. 2012 Sep-Oct;30(5):471-5. PMID: 22902215; X-1

3233. Kerl K, Nowacki M, Leuschner I, et al. Infantile fibrosarcoma - an important differential diagnosis of congenital vascular tumors. Pediatr Hematol Oncol. 2012 Sep;29(6):545-8. PMID: 22812410; X-1

3234. Khan SN, Sepahdari AR. Orbital masses: CT and MRI of common vascular lesions, benign tumors, and malignancies. Saudi J Ophthalmol. 2012 October;26(4):373-83. PMID: 2012721702; X-2

3235. Kim DH, Choi JH, Lee JH, et al. PHACE association with intracranial, oropharyngeal hemangiomas, and an atypical patent ductus arteriosus arising from the tortuous left subclavian artery in a premature infant. Korean J Pediatr. 2012 January;55(1):29-33. PMID: 2012460880; X-2

3236. Kim KH, Chung SB, Kong DS, et al. Neurocutaneous melanosis associated with Dandy-Walker complex and an intracranial cavernous angioma. Childs Nerv Syst. 2012 Feb;28(2):309-14. PMID: 22134415; X-1

3237. Kiratli H, Uzun S, Tarlan B, et al. Recurrent subconjunctival hemorrhage due to cavernous hemangioma of the conjunctiva. Can J Ophthalmol. 2012 Jun;47(3):318-20. PMID: 22687315; X-1

3238. Kivelev J, Koskela E, Setala K, et al. Long-term visual outcome after microsurgical removal of occipital lobe cavernomas. J Neurosurg. 2012 Aug;117(2):295-301. PMID: 22702480; X-1

3239. Kleber CJ, Spiess A, Kleber JB, et al. Urinary matrix metalloproteinases-2/9 in healthy infants and haemangioma patients prior to and during propranolol therapy. Eur J Pediatr. 2012 Jun;171(6):941-6. PMID: 22203431; X-2

3240. Knott EM, Valusek PA, St Peter SD. Laparoscopic excision of a giant splenic vascular tumor. J Pediatr Surg. 2012 Jul;47(7):E21-3. PMID: 22813826; X-1, X-2

3241. Koike T, Yanagimachi N, Ishiguro H, et al. High incidence of radiation-induced cavernous hemangioma in long-term survivors who underwent hematopoietic stem cell transplantation with radiation therapy during childhood or adolescence. Biol Blood Marrow Transplant. 2012 Jul;18(7):1090-8. PMID: 22198541; X-1

3242. Kota SK, Meher LK, Kota SK, et al. Sturge-Weber syndrome: presentation with partial hypopituitarism. J Pediatr Endocrinol Metab. 2012;25(7-8):785-9. PMID: 23155711; X-1

3243. Kotecha UH, Movva S, Puri RD, et al. Trichohepatoenteric syndrome: Founder mutation in Asian Indians. Molecular Syndromology. 2012 August;3(2):89-93. PMID: 2012496369; X-1

3244. Kulungowski AM, Alomari AI, Chawla A, et al. Lessons from a liver hemangioma registry: subtype classification. J Pediatr Surg. 2012 Jan;47(1):165-70. PMID: 22244411; X-3

3245. Kupeli S. Use of propranolol for infantile hemangiomas. Pediatr Hematol Oncol. 2012 Apr;29(3):293-8. PMID: 22303875; X-4

3246. Kupeli S, Cimen D, Kupeli BY. Successful treatment with propranolol in a patient with a segmental hemangioma: A case report

Segmental Hemanjiyomun propranolol ile Basari{dotless}li{dotless} Tedavisi: Bir Olgu Sunumu. Turk J Haematol. 2012;29(2):170-3. PMID: 2012344251; X-2

3247. Lanoel A, Tosi V, Bocian M, et al. Perianal ulcers on a segmental hemangioma with minimal or arrested growth. Actas Dermosifiliogr. 2012 Nov;103(9):820-3. PMID: 22421500; X-2

3248. Lauren C, Garzon MC. Treatment of infantile hemangiomas. Pediatr Ann. 2012 Aug;41(8):1-7. PMID: 22881415; X-1, X-2

3249. Leavitt DA, Hottinger DG, Reed RC, et al. A case series of genital vascular anomalies in children and their management: lessons learned. Urology. 2012 Oct;80(4):914-8. PMID: 22951002; X-3, X-4

3250. Lee JJ, Lin LY, Hsieh SW, et al. Successful treatment of Kasabach-Merritt phenomenon with intralesional corticosteroid injections: a case series. Ann Plast Surg. 2012 Dec;69(6):627-32. PMID: 23154333; X-1

3251. Lee N, Isenstein A, Zedek D, et al. A case of childhood subcutaneous pyogenic granuloma (lobular capillary hemangioma). Clin Pediatr (Phila). 2012 Jan;51(1):88-90. PMID: 21196416; X-1, X-2

3252. Lembo S, Balato A, Raimondo A, et al. A preterm infant with benign neonatal hemangiomatosis and persistent patent ductus arteriosus: a curious comorbidity. G Ital Dermatol Venereol. 2012 Jun;147(3):321-4. PMID: 22648333; X-1, X-3

3253. Levy ML. Propranolol for infantile hemangiomas. Glob Adv Health Med. 2012;1(2):14-6. PMID: 2013138427; X-2

3254. Liu C, Qin ZP, Fan ZN, et al. New treatment strategy for granulomatous epulis: intralesional injection of propranolol. Med Hypotheses. 2012 Feb;78(2):327-9. PMID: 22133559; X-1

3255. Liu Y, Huang ZH, Xu SQ, et al. Value of histopathologic examination in differential diagnosis of infantile cholestasis. World Chinese Journal of Digestology. 2012;20(23):2200-4. PMID: 2012508499; X-1

3256. Mankowski B, Osmola-Mankowska A, Olszanski R, et al. Squamous cell carcinoma as a long-term effect after skin vascular malformation radiotherapy. Postepy Dermatol Alergol. 2012;29(6):471-4. PMID: 2013006868; X-1

3257. Mao XH, Wang JY, Yan JL. Topical imiquimod treatment of cutaneous vascular disorders in pediatric patients: clinical evaluation on the efficacy and safety. J Zhejiang Univ Sci B. 2012 Sep;13(9):745-50. PMID: 22949365; X-4

3258. Martens D, Oster I, Gottschlling S, et al. Cerebral MRI and EEG studies in the initial management of pediatric headaches. Swiss Med Wkly. 2012;142:w13625. PMID: 22782255; X-1

3259. Martinez-Escaname M, Castillo-Martinez C, Torres-Alvarez B, et al. Diffuse neonatal hemangiomatosis: a case report. Int J Dermatol. 2012 Oct;51(10):1228-30. PMID: 21470219; X-1, X-2

3260. Masnari O, Landolt MA, Roessler J, et al. Self- and parent-perceived stigmatisation in children and adolescents with congenital or acquired facial differences. J Plast Reconstr Aesthet Surg. 2012 Dec;65(12):1664-70. PMID: 22770573; X-3

3261. Matuszczak E, Reszec J, Debek W, et al. Is littoral cell angioma of the spleen as rare as previously believed in the pediatric population? Folia Histochem Cytobiol. 2012;50(3):480-5. PMID: 23042283; X-1

3262. Mavrogenis AF, Rossi G, Calabro T, et al. The role of embolization for hemangiomas. Musculoskelet Surg. 2012 Aug;96(2):125-35. PMID: 22684541; X-1, X-2

3263. McCanlies EC, Fekedulegn D, Mnatsakanova A, et al. Parental occupational exposures and autism spectrum disorder. J Autism Dev Disord. 2012 Nov;42(11):2323-34. PMID: 22399411; X-1

3264. McMahon P, Oza V, Frieden IJ. Topical timolol for infantile hemangiomas: putting a note of caution in "cautiously optimistic". Pediatr Dermatol. 2012 Jan-Feb;29(1):127-30. PMID: 22256996; X-1, X-2

3265. Mikhail MA, Ng J, Mathew J, et al. Von Hippel Lindau disease: keep it in the family. BMJ Case Rep. 2012;2012PMID: 23242101; X-1

3266. Mills SA, Oh MC, Rutkowski MJ, et al. Supratentorial hemangioblastoma: clinical features, prognosis, and predictive value of location for von Hippel-Lindau disease. Neuro Oncol. 2012 Aug;14(8):1097-104. PMID: 22723428; X-1

3267. Moon SB, Jung SM, Kwon CH, et al. Posteromedial diaphragmatic hernia following pediatric liver transplantation. Pediatr Transplant. 2012 Jun;16(4):E106-9. PMID: 21235708; X-1

3268. Moreira Guimaraes Penido MG, de Sousa Tavares M, Campos Linhares M, et al. Longitudinal study of bone mineral density in children with idiopathic hypercalciuria. Pediatr Nephrol. 2012 Jan;27(1):123-30. PMID: 21779854; X-1

3269. Moss HB, Sines DT, Blatt J, et al. Epithelioid hemangioma responsive to oral propranolol. Ophthal Plast Reconstr Surg. 2012 Jul-Aug;28(4):e88-90. PMID: 22186982; X-1

3270. Murthy GJ, Goswami M. Management of adult onset orbital hemangioma by oral propranalol: a case report. Orbit. 2012 Oct;31(5):373-5. PMID: 22877318; X-1

3271. Nolan M, Hartin CW, Jr., Pierre J, et al. Life-threatening hemorrhage from a congenital hemangioma caused by birth trauma. J Pediatr Surg. 2012 May;47(5):1016-8. PMID: 22595593; X-1

3272. Ogawa A, Miyaji K, Yamadori I, et al. Safety and efficacy of epoprostenol therapy in pulmonary veno-occlusive disease and pulmonary capillary hemangiomatosis. Circ J. 2012;76(7):1729-36. PMID: 22481098; X-1

3273. Ozsahin M, Uslu M, Inanmaz E, et al. Intramuscular hemangioma of flexor digitorum brevis muscle. Am J Phys Med Rehabil. 2012 Oct;91(10):910. PMID: 21904191; X-1

3274. Parlak AH, Atasoy HI, Polat M, et al. Is there a potential role of photo herapy for development of infantile hemangiomas: A case report. European Journal of Pediatric Dermatology. 2012 March;22 (1):41. PMID: 70795433; X-2

3275. Patiroglu T, Sarici D, Unal E, et al. Cerebellar hemangioblastoma associated with diffuse neonatal hemangiomatosis in an infant. Childs Nerv Syst. 2012 Oct;28(10):1801-5. PMID: 22820755; X-1

3276. Peralta L, Rocha G, Morais P, et al. Skin disorders in the neonatal intensive care unit of a central hospital. Eur J Dermatol. 2012 Jan-Feb;22(1):88-92. PMID: 22157797; X-1

3277. Phi JH, Kim SK, Cho A, et al. Intracranial capillary hemangioma: extra-axial tumorous lesions closely mimicking meningioma. J Neurooncol. 2012 Aug;109(1):177-85. PMID: 22544652; X-1

3278. Pompa V, Brauner E, Bresadola L, et al. Treatment of facial vascular malformations with embolisation and surgical resection. Eur Rev Med Pharmacol Sci. 2012 Mar;16(3):407-13. PMID: 22530359; X-1

3279. Portnow LH, Scott M, Morris CG, et al. Fractionated radiotherapy in the management of benign vascular tumors. Am J Clin Oncol. 2012 Dec;35(6):557-61. PMID: 21659831; X-1

3280. Potts MB, Chang EF, Young WL, et al. Transsylvian-transinsular approaches to the insula and basal ganglia: operative techniques and results with vascular lesions. Neurosurgery. 2012 Apr;70(4):824-34; discussion 34. PMID: 21937930; X-1

3281. Powell J, Blouin MM, David M, et al. Bleeding in congenital hemangiomas: crusting as a clinical predictive sign and usefulness of tranexamic acid. Pediatr Dermatol. 2012 Mar-Apr;29(2):182-5. PMID: 21995591; X-1

3282. Raches D, Hiscock M, Chapieski L. Behavioral and academic problems in children with Sturge-Weber syndrome: differences between children with and without seizures. Epilepsy Behav. 2012 Nov;25(3):457-63. PMID: 23000106; X-1

3283. Rai P, Shab SIA, Das D. Outcome of low dose intralesional steroid injections in Superficial Infantile Capillary Hemangioma (SICH) of eyelid. Medical Forum Monthly. 2012 November;23(11):32-4. PMID: 2013054269; X-5

3284. Rajewska J, Gawrych E, Fischer K, et al. Estimation of vascular endothelial growth factor and placental growth factor serum levels' in infant with hemangioma and population of healthy infants. Ann Acad Med Stetin. 2012;58(2):5-10. PMID: 23767175; X-2

3285. Rapp M, Rapp M, Berg C, et al. Prenatal suspicion of Kaposiform hemangioendo-thelioma in siblings: different clinical manifestation and emergency relief. Klin Padiatr. 2012 Oct;224(6):390-1. PMID: 23143766; X-1

3286. Roach EE, Chakrabarti R, Park NI, et al. Intrinsic regulation of hemangioma involution by platelet-derived growth factor. Cell Death Dis. 2012;3:e328. PMID: 22717583; X-1

3287. Roebuck D. RICH depuis la lettre. Pediatr Radiol. 2012 Mar;42(3):296-7. PMID: 22207138; X-1

3288. Roebuck D, Sebire N, Lehmann E, et al. Rapidly involuting congenital haemangioma (RICH) of the liver. Pediatr Radiol. 2012 Mar;42(3):308-14. PMID: 22302317; X-1

3289. Ryan E, Warren L. Birthmarks--identification and management. Aust Fam Physician. 2012 May;41(5):274-7. PMID: 22558616; X-1, X-2

3290. Sakamoto N, Ishikawa E, Nakai Y, et al. Preoperative endovascular embolization for hemangioblastoma in the posterior fossa. Neurol Med Chir (Tokyo). 2012;52(12):878-84. PMID: 23269042; X-1

3291. Schramm J, Kuczaty S, Sassen R, et al. Pediatric functional hemispherectomy: outcome in 92 patients. Acta Neurochir (Wien). 2012 Nov;154(11):2017-28. PMID: 22941395; X-1

3292. Segura Palacios JM, Boixeda P, Rocha J, et al. Laser treatment for verrucous hemangioma. Lasers Med Sci. 2012 May;27(3):681-4. PMID: 21975688; X-1

3293. Seirafi H, Ehsani A, Jesri S, et al. Treatment of infantile hemangioma with topical imiquimod 5% cream. Iranian Journal of Dermatology. 2012;15(62):117-21. PMID: 2013309261; X-4

3294. Seo S, Takahashi T, Marusasa T, et al. Management of inguinal hernia in children can be enhanced by closer follow-up by consultant pediatric surgeons. Pediatr Surg Int. 2012 Jan;28(1):33-6. PMID: 22033770; X-1

3295. Shapiro E, Guler OE, Rudser K, et al. An exploratory study of brain function and structure in mucopolysaccharidosis type I: long term observations following hematopoietic cell transplantation (HCT). Mol Genet Metab. 2012 Sep;107(1-2):116-21. PMID: 22867884; X-1

3296. Shepherd D, Adams S, Wargon O, et al. Childhood wheeze while taking propranolol for treatment of infantile hemangiomas. Pediatr Pulmonol. 2012 Jul;47(7):713-5. PMID: 22170856; X-3, X-4

3297. Sheu GL, Hammer Y, Kirsch AJ. Testicular capillary hemangioma presenting as an incidental contralateral lesion in a child with cryptorchidism. Urology. 2012 Nov;80(5):1135-7. PMID: 22990059; X-1

3298. Shi CB, Yuan B, Lu JR, et al. Continuous low-dose-rate radiation of radionuclide phosphorus-32 for hemangiomas. Cancer Biother Radiopharm. 2012 Apr;27(3):198-203. PMID: 22364418; X-3

3299. Shiau T, Armogan N, Yan DB, et al. The role of episcleral venous pressure in glaucoma associated with Sturge-Weber syndrome. J aapos. 2012 Feb;16(1):61-4. PMID: 22370668; X-1

3300. Shukla S, Acharya S, Bhola N, et al. Central haemangioma (intraosseous) of jaw. Journal of Medicine (Bangladesh). 2012;13(2):222-6. PMID: 2012741756; X-1, X-2

3301. Siklos K, Sapy Z, Szalai Z. Infantile myofibroma: Report of two patients. European Journal of Pediatric Dermatology. 2012 March;22 (1):79. PMID: 70795523; X-1

3302. Simonini VM, Lodi L. Encephalofacial angiomatosis (Sturge-Weber syndrome): report of three cases. Acta Clin Croat. 2012 Dec;51 Suppl 1:91-8. PMID: 23431731; X-1

3303. Slowinska M, Rakowska A, Maj M, et al. Dermoscopy of proliferative lesions of the scalp-12 years of experience, Dermoskopia zmian rozrostowych skory owlosionej glowy - podsumowanie 12 lat doswiadczen. [Polish, English]. Przegl Dermatol. 2012;99 (4):461. PMID: 71001917; X-1

3304. Smadja DM, Mulliken JB, Bischoff J. E-selectin mediates stem cell adhesion and formation of blood vessels in a murine model of infantile hemangioma. Am J Pathol. 2012 Dec;181(6):2239-47. PMID: 23041613; X-1

3305. Smit DP, Meyer D. Intralesional bleomycin for the treatment of periocular capillary hemangiomas. Indian J Ophthalmol. 2012 Jul;60(4):326-8. PMID: 22824608; X-3, X-4

3306. Soldado F, Fontecha CG, Haddad S, et al. Composite vascularized fibular epiphyseo-osteo-periosteal transfer for hip reconstruction after proximal femoral tumoral resection in a 4-year-old child. Microsurgery. 2012 Sep;32(6):489-92. PMID: 22511340; X-1

3307. Sondhi V, Kurkure PA, Vora T, et al. Successful management of multi-focal hepatic infantile hemangioendothelioma using TACE/surgery followed by maintenance metronomic therapy. BMJ Case Rep. 2012;2012PMID: 22605610; X-1

3308. Song JN, Jung SL, Lee SH, et al. A case of large auricular lymphangioma. Int J Pediatr Otorhinolaryngol Extra. 2012 September;7(3):100-2. PMID: 2012745969; X-1

3309. Spierer O, Neudorfer M, Leibovitch I, et al. Colour Doppler ultrasound imaging findings in paediatric periocular and orbital haemangiomas. Acta Ophthalmol. 2012 Dec;90(8):727-32. PMID: 21457487; X-3

3310. Stiles J, Amaya C, Pham R, et al. Propranolol treatment of infantile hemangioma endothelial cells: A molecular analysis. Exp Ther Med. 2012;4(4):594-604. PMID: 2012500005; X-1, X-3

3311. Strand M, Smidt AC. Pain management for ulcerated infantile hemangiomas. Pediatr Dermatol. 2012 Jan-Feb;29(1):124-6. PMID: 22256995; X-2

3312. Takahashi H, Nagatoshi Y, Kato M, et al. Multifocal skin lesions and melena with thrombocytopenia in an infant. J Pediatr. 2012 Mar;160(3):524-.e1. PMID: 22074937; X-1

3313. Tan ST, Itinteang T, Day DJ, et al. Treatment of infantile haemangioma with captopril. Br J Dermatol. 2012 Sep;167(3):619-24. PMID: 22533490; X-4

3314. Taylor SRJ, Singh J, Sagoo MS, et al. Clinical and molecular features associated with cystic visceral lesions in von hippel-lindau disease. Open J Ophthalmol. 2012;6:83-5. PMID: 2012556370; X-1

3315. Tchidjou HK, Vescio F, Avellis L, et al. An atypical case of multifocal infantile haemangioma in a child after Highly Active Antiretroviral Therapy (HAART) during pregnancy. Clin Neurol Neurosurg. 2012 Oct;114(8):1161-3. PMID: 22763192; X-2

3316. Templeton C, Harnett D. Successful use of atenolol in the treatment of a severe infantile hemangioma. European Journal of Pediatric Dermatology. 2012 July-September;22(3):179-81. PMID: 2013012351; X-2

3317. Thomas MW, Burkhart CN, Vaghani SP, et al. Failure to thrive in infants with complicated facial hemangiomas. Pediatr Dermatol. 2012 Jan-Feb;29(1):49-52. PMID: 21950618; X-3, X-4

3318. Thompson CV, Wells JM, Bowen C, et al. Intra-abdominal Kaposiform hemangioendothelioma and the benefits of laparoscopic surveillance. Pediatr Blood Cancer. 2012 Jun;58(6):992-3. PMID: 22431247; X-1

3319. Thoumazet F, Leaute-Labreze C, Colin J, et al. Efficacy of systemic propranolol for severe infantile haemangioma of the orbit and eyelid: a case study of eight patients. Br J Ophthalmol. 2012 Mar;96(3):370-4. PMID: 21673014; X-4

3320. Tollefson MM, Frieden IJ. Early growth of infantile hemangiomas: what parents' photographs tell us. Pediatrics. 2012 Aug;130(2):e314-20. PMID: 22826568; X-3

3321. Traivaree C, Lumkul R, Torcharus K, et al. Outcome of Kasabach-Merritt phenomenon: the role of vincristine as monotherapy: report of a case. J Med Assoc Thai. 2012 May;95 Suppl 5:S181-5. PMID: 22934467; X-1

3322. Tu JB, Dong Q, Hu XY, et al. Proteomic analysis of mitochondria from infantile hemangioma endothelial cells treated with sodium morrhuate and its liposomal formulation. J Biochem Mol Toxicol. 2012 Sep;26(9):374-80. PMID: 22987598; X-1

3323. Ueba T, Abe H, Matsumoto J, et al. Efficacy of indocyanine green videography and real-time evaluation by FLOW 800 in the resection of a spinal cord hemangioblastoma in a child: case report. J Neurosurg Pediatr. 2012 Apr;9(4):428-31. PMID: 22462710; X-1

3324. Veras TN, Benvenutti RC, Hornburg G, et al. Subglottic hemangiome in childhood. Braz J Otorhinolaryngol. 2012 Feb;78(1):143. PMID: 22392255; X-2

3325. Vergine G, Marsciani A, Pedini A, et al. Efficacy of propranolol treatment in thyroid dysfunction associated with severe infantile hepatic hemangioma. Horm Res Paediatr. 2012;78(4):256-60. PMID: 22907522; X-2

3326. Vigone MC, Cortinovis F, Rabbiosi S, et al. Difficult treatment of consumptive hypothyroidism in a child with massive parotid hemangioma. J Pediatr Endocrinol Metab. 2012;25(1-2):153-5. PMID: 22570966; X-2

3327. Virbalas JM, Bent JP, Parikh SR. Pediatric nasal lobular capillary hemangioma. Case Rep Med. 2012;2012(769630)PMID: 2012539243; X-1, X-2

3328. Virginia C, Florentina F, Sabina ZA, et al. Study of clinical and dermoscopic features in acquired hemangioma for a correct therapeutic attitude. Therapeutics, Pharmacology and Clinical Toxicology. 2012 June;16(2):101-5. PMID: 2013302523; X-1

3329. Vitoria Minana I. Most common skin disorders of the newborn and infant. Diaper rash Trastornos cutaneos mas frecuentes del recien nacido y del lactante. Dermatitis del panal. Pediatria Integral. 2012 April;16(3):195-208. PMID: 2012403733; X-1, X-2

3330. Vladareanu R, Zvanca M, Andrei C. Pathology of the fetal neck. Donald School Journal of Ultrasound in Obstetrics and Gynecology. 2012 January-March;6(1):55-65. PMID: 2012351656; X-1

3331. Wang YJ, Zhang ZW, Yu J, et al. Hemangioendothelioma of the right atrial appendage associated with pericardial effusion in an infant. World J Pediatr. 2012 Feb;8(1):83-5. PMID: 22282383; X-1

3332. Watson T, Martinez E, Crabbe D, et al. Renal lymphangiomatosis, interrupted IVC with persistent primitive hepatic venous plexus and multiple anomalous venous channels: parts of an overlap syndrome? Pediatr Radiol. 2012 Feb;42(2):253-6. PMID: 21773796; X-1

3333. Weibel L, Scheer HS, Barysch M, et al. Topical betablo-ckers for infantile hemangiomas are effective but systemically absorbed. European Journal of Pediatric Dermatology. 2012 March;22 (1):10-1. PMID: 70795377; X-2

3334. Weissenstein A, Straeter A, Villalon G, et al. Topical timolol for small infantile hemangioma: a new therapy option. Turk J Pediatr. 2012 Mar-Apr;54(2):156-8. PMID: 22734302; X-4

3335. Weissenstein A, Villalon G, Luchter E, et al. Children's haemangiomas: use of new topical therapies. Br J Nurs. 2012 Mar 8-21;21(5):274. PMID: 22398997; X-4

3336. Wittig M, Fischer M, Baur MO, et al. A newborn infant with sepsis-like clinical picture and petechial bleeding (case presentation). Acta Paediatr. 2012 Jul;101(7):685-6, 792-3. PMID: 22672692; X-1

3337. Wong A, Hardy KL, Kitajewski AM, et al. Propranolol accelerates adipogenesis in hemangioma stem cells and causes apoptosis of hemangioma endothelial cells. Plast Reconstr Surg. 2012 Nov;130(5):1012-21. PMID: 23096601; X-1

3338. Wu JC, Chen YC, Liu L, et al. Younger boys have a higher risk of inguinal hernia after ventriculo-peritoneal shunt: a 13-year nationwide cohort study. J Am Coll Surg. 2012 May;214(5):845-51. PMID: 22520694; X-1

3339. Wu S, Liu G, Chen R, et al. Role of ultrasound in the assessment of benignity and malignancy of parotid masses. Dentomaxillofac Radiol. 2012 Feb;41(2):131-5. PMID: 22116132; X-1

3340. Xie WM, Dai HP, Jin ML, et al. Clinical features and imaging findings in pulmonary capillary hemangiomatosis: report of two cases and a pooled analysis. Chin Med J (Engl). 2012 Sep;125(17):3069-73. PMID: 22932183; X-1

3341. Yan J, Zhou S, Li Y. Benign orbital tumors with bone destruction in children. PLoS One. 2012;7(2):e32111. PMID: 22384155; X-1, X-2

3342. Yu Y, Sanderson SR, Reyes M, et al. Novel NaPi-IIc mutations causing HHRH and idiopathic hypercalciuria in several unrelated families: long-term follow-up in one kindred. Bone. 2012 May;50(5):1100-6. PMID: 22387237; X-1

3343. Yuen NS, Wong IY. Congenital glaucoma from Sturge-Weber syndrome: a modified surgical approach. Korean J Ophthalmol. 2012 Dec;26(6):481-4. PMID: 23204808; X-1

3344. Zaidi SN, Fathaddin AA. Testicular capillary hemangioma--a case report of a rare tumor. Indian J Pathol Microbiol. 2012 Oct-Dec;55(4):557-9. PMID: 23455806; X-1

3345. Zakaria Z, Kaliaperumal C, Caird J, et al. Unilateral facial palsy in an infant: an unusual presentation of familial multiple cerebral cavernous malformation. BMJ Case Rep. 2012;2012PMID: 23203183; X-1

3346. Zavras N, Christianakis E, Ereikat K, et al. Intracranial hypertension secondary to abdominal compartment syndrome in a girl with giant ovarian cystic mass. Indian J Pediatr. 2012 Apr;79(4):541-2. PMID: 21842281; X-1

3347. Zhang H, Luo J, Feng X. Kaposiform hemangioendothelioma in the uterine cervix of a 5-year girl. Fetal Pediatr Pathol. 2012 Oct;31(5):273-7. PMID: 22432747; X-1

3348. Zheng SP, Ju Y, You C. Giant intracranial capillary hemangioma in a 3-year-old child: case report and literature review. Clin Neurol Neurosurg. 2012 Nov;114(9):1270-3. PMID: 22425365; X-1

3349. . Carefully consider the best approach when treating infantile haemangiomas. Drugs and Therapy Perspectives. 2013 October;29(10):314-9. PMID: 2013633583; X-1, X-2

3350. . Birthmark Check. Parents. 2013;88(3):62-. PMID: X-1

3351. Ajitsaria R, Quinn E, Mew RC, et al. Rare tumour presenting in a newborn infant. Arch Dis Child. 2013 May;98(5):362. PMID: 23178397; X-1

3352. Al Masalmeh O, Shaikh R, Chaudry G, et al. Transjugular retrograde cannulation of the portal vein via patent ductus venosus: alternative access for endovascular hepatic interventions. J Vasc Interv Radiol. 2013 Jan;24(1):81-4. PMID: 23273700; X-1

3353. Al-Breiki S, Shaikh L. An extensive bilateral cervicofacial hemangioma managed successfully with propranolol, a case report and literature review. Journal of the Saudi Society of Dermatology and Dermatologic Surgery. 2013 July;17(2):65-8. PMID: 2013549079; X-2

3354. Alcantara-Gonzalez J, Boixeda P, Truchuelo-Diez MT, et al. Infantile hemangiomas treated by sequential application of pulsed dye laser and Nd:YAG laser radiation: a retrospective study. Actas Dermosifiliogr. 2013 Jul-Aug;104(6):504-11. PMID: 23522740; X-4

3355. Altomare M, La Vignera S, Asero P, et al. High prevalence of thyroid dysfunction in pregnant women. J Endocrinol Invest. 2013 Jun;36(6):407-11. PMID: 23095459; X-1

3356. Amato MC, Madureira JF, Oliveira RS. Intracranial cavernous malformation in children: a single-centered experience with 30 consecutive cases. Arq Neuropsiquiatr. 2013 Apr;71(4):220-8. PMID: 23588283; X-1

3357. Ammerman RT, Putnam FW, Altaye M, et al. A clinical trial of in-home CBT for depressed mothers in home visitation. Behav Ther. 2013 Sep;44(3):359-72. PMID: 23768664; X-1

3358. Ammerman RT, Putnam FW, Altaye M, et al. Treatment of depressed mothers in home visiting: impact on psychological distress and social functioning. Child Abuse Negl. 2013 Aug;37(8):544-54. PMID: 23623623; X-1

3359. Anderson de Moreno LC, Matt BH, Montgomery G, et al. Propranolol in the treatment of upper airway hemangiomas. Ear Nose Throat J. 2013 Apr-May;92(4-5):209-14. PMID: 23599104; X-4

3360. Anderson JC, Brown KK. Masson tumor arising in a congenital vascular anomaly. Pediatr Dermatol. 2013;30(6):745-7. PMID: 24033678; X-1, X-3

3361. Arica DA, Arica IE, Yayli S, et al. Spitz nevus arising upon a congenital glomuvenous malformation. Pediatr Dermatol. 2013 May-Jun;30(3):e25-6. PMID: 22304367; X-1

3362. Aslan H, Dural O, Yildirim G, et al. Prenatal diagnosis of a liver cavernous hemangioma. Fetal Pediatr Pathol. 2013 Oct;32(5):341-5. PMID: 23421545; X-1, X-2

3363. Avagyan S, Klein M, Kerkar N, et al. Propranolol as a first-line treatment for diffuse infantile hepatic hemangioendothelioma. J Pediatr Gastroenterol Nutr. 2013 Mar;56(3):e17-20. PMID: 22331019; X-1

3364. Avolio L, Rispoli GA, Morbini P, et al. Intralobar pulmonary sequestration associated with hemangioma. Am J Respir Crit Care Med. 2013 Jun 15;187(12):1388-9. PMID: 23767903; X-2

3365. Aziz AS, Hui D, Chinnappa V, et al. Successful pregnancy, epidural anaesthesia, labour, and delivery in a woman with Sturge-Weber syndrome and previous hemispherectomy. J Obstet Gynaecol Can. 2013 Oct;35(10):917-9. PMID: 24165060; X-1

3366. Bajaj Y, Kapoor K, Ifeacho S, et al. Great Ormond Street Hospital treatment guidelines for use of propranolol in infantile isolated subglottic haemangioma. J Laryngol Otol. 2013 Mar;127(3):295-8. PMID: 23369213; X-1

3367. Bayer ML, Frommelt PC, Blei F, et al. Congenital cardiac, aortic arch, and vascular bed anomalies in PHACE syndrome (from the International PHACE Syndrome Registry). Am J Cardiol. 2013 Dec 15;112(12):1948-52. PMID: 24079520; X-3, X-4

3368. Berk DR, Culican SM, Bayliss SJ. Scleral hemangioma: case report and response to propranolol. Pediatr Dermatol. 2013 May-Jun;30(3):e16-7. PMID: 22486338; X-2

3369. Bertozzi M, Melissa B, Magrini E, et al. Laparoscopic herniorrhaphy in the pediatric age group: what about the learning curve? J Endourol. 2013 Jul;27(7):840-4. PMID: 23384349; X-1

3370. Biggs S, Nixon G, Davey M, et al. Slow wave activity in children with excessive daytime sleepiness: A potential role in identification of narcolepsy. Sleep Biol Rhythms. 2013 October;11:39-40. PMID: 71226664; X-1

3371. Bilodi AKS, Singh S, Ebenezer DA, et al. Capillary haemangioma of the right elbow and forearm in new born child. J Clin Diagn Res. 2013 15 Dec;7(12):2941-2. PMID: 2013804019; X-2

3372. Blanke K, Dahnert I, Salameh A. Role of connexins in infantile hemangiomas. Front Pharmacol. 2013;4 APR(Article 41)PMID: 2013563389; X-1, X-2

3373. Block SL, Blackmon L. Treating infantile hemangiomatosis: a case study. Pediatr Ann. 2013 Jun 1;42(6):230-3. PMID: 23718244; X-2

3374. Boscolo E, Mulliken JB, Bischoff J. Pericytes from infantile hemangioma display proangiogenic properties and dysregulated angiopoietin-1. Arterioscler Thromb Vasc Biol. 2013 Mar;33(3):501-9. PMID: 23288163; X-1, X-3

3375. Boucek RJ, Jr., Kirsh AL, Majesky MW, et al. Propranolol responsiveness in vascular tumors is not determined by qualitative differences in adrenergic receptors. Otolaryngol Head Neck Surg. 2013 Nov;149(5):772-6. PMID: 24009211; X-1

3376. Burch EA, Garzon MC, Parikh A, et al. A 65-year-old woman diagnosed with PHACE syndrome. Pediatr Dermatol. 2013;30(6):e153-6. PMID: 23278462; X-1

3377. Burgemeister AL, Behnecke A, Pietz J, et al. PHACES syndrome-a case with Moya-Moya-like vasculopathy. Medizinische Genetik. 2013 March;25 (1):115. PMID: 71009604; X-2

3378. Calvo M, Garcia-Millan C, Villegas C, et al. Topical timolol for infantile hemangioma of the eyelid. Int J Dermatol. 2013 May;52(5):603-4. PMID: 22417222; X-2

3379. Capone F, Profice P, Pilato F, et al. Spinal hemangioblastoma presenting with low back pain in pregnancy. Spine J. 2013 Dec;13(12):e27-9. PMID: 24051331; X-1

3380. Causse S, Aubert H, Saint-Jean M, et al. Propranolol-resistant infantile haemangiomas. Br J Dermatol. 2013 Jul;169(1):125-9. PMID: 23659587; X-4

3381. Cavalli R, Novotna V, Buffon RB, et al. Multiple cutaneous and hepatic infantile hemangiomas having a successful response to propranolol as monotherapy at neonatal period. G Ital Dermatol Venereol. 2013 October;148(5):525-30. PMID: 2013761238; X-2

3382. Chachad S, Khan A. Klippel-TrÃ©naunay-Weber Syndrome. Consultant. 2013;53(6):470-. PMID: X-1

3383. Chaithirayanon S, Boonyaleephan S, Treesirichod A, et al. Early onset and rapid progression of glaucoma in a neonate with Sturge-Weber syndrome. J Med Assoc Thai. 2013 Mar;96(3):374-7. PMID: 23539944; X-1

3384. Chan S, Cassarino DS. Rapidly enlarging "bruise" on the back of an infant. Kaposiform hemangioendothelioma complicated by Kasabach-Merritt syndrome. JAMA Dermatol. 2013 Nov;149(11):1337-8. PMID: 24005816; X-1

3385. Chantasart D, Hao J, Li SK. Evaluation of skin permeation of beta-blockers for topical drug delivery. Pharm Res. 2013 Mar;30(3):866-77. PMID: 23208385; X-1

3386. Chaudhry TA, Kamal M, Ahmad K. Periocular infantile haemangioma and the role of propranolol. J Coll Physicians Surg Pak. 2013 Aug;23(8):593-5. PMID: 23930881; X-2

3387. Chavala SH, Williamson JF. Bilateral exudative retinal detachments in Sturge-Weber syndrome. Lancet. 2013 Jul 20;382(9888):259. PMID: 23375876; X-1

3388. Chen LF, Yang Y, Yu XG, et al. Operative management of brainstem hemangioblastomas. J Clin Neurosci. 2013 Dec;20(12):1727-33. PMID: 24055208; X-1

3389. Chen XD, Ma G, Chen H, et al. Maternal and perinatal risk factors for infantile hemangioma: a case-control study. Pediatr Dermatol. 2013 Jul-Aug;30(4):457-61. PMID: 23278441; X-1, X-3

3390. Chen XD, Ma G, Huang JL, et al. Serum-level changes of vascular endothelial growth factor in children with infantile hemangioma after oral propranolol therapy. Pediatr Dermatol. 2013 Sep-Oct;30(5):549-53. PMID: 23909679; X-3, X-4

3391. Cho BS, Hahn WH, Cheong HI, et al. A nationwide study of mass urine screening tests on Korean school children and implications for chronic kidney disease management. Clin Exp Nephrol. 2013 Apr;17(2):205-10. PMID: 23135862; X-1

3392. Chu MB, Searcy G, Siegfried E. Efficacy of topical brimonidine-timolol for haemangioma of infancy and perils of off-label prescribing. BMJ Case Rep. 2013;2013PMID: 23598940; X-2

3393. Cloke A, Lim LT, Blaikie A. Capillary haemangioma successfully treated with oral beta-blocker in Dar es Salaam, Tanzania: a case report. Semin Ophthalmol. 2013 Jan;28(1):32-3. PMID: 23305438; X-1, X-2

3394. Cohen-Barak E, Rozenman D, Shani Adir A. Infantile haemangiomas and quality of life. Arch Dis Child. 2013 Sep;98(9):676-9. PMID: 23864355; X-3, X-4

3395. Consiglieri GD, Killory BD, Germain RS, et al. Utility of the CO2 laser in the microsurgical resection of cavernous malformations. World Neurosurg. 2013 May-Jun;79(5-6):714-8. PMID: 22381271; X-1

3396. Croteau SE, Liang MG, Kozakewich HP, et al. Kaposiform hemangioendothelioma: atypical features and risks of Kasabach-Merritt phenomenon in 107 referrals. J Pediatr. 2013 Jan;162(1):142-7. PMID: 22871490; X-1

3397. DelRosso LM, Chesson AL, Jr., Hoque R. Characterization of REM sleep without atonia in patients with narcolepsy and idiopathic hypersomnia using AASM scoring manual criteria. J Clin Sleep Med. 2013 Jul 15;9(7):675-80. PMID: 23853561; X-1

3398. Du W, Gerald D, Perruzzi CA, et al. Vascular tumors have increased p70 S6-kinase activation and are inhibited by topical rapamycin. Lab Invest. 2013 Oct;93(10):1115-27. PMID: 23938603; X-1

3399. Eisengart JB, Rudser KD, Tolar J, et al. Enzyme replacement is associated with better cognitive outcomes after transplant in Hurler syndrome. J Pediatr. 2013 Feb;162(2):375-80.e1. PMID: 22974573; X-1

3400. El Essawy R, Galal RE. Parenteral corticosteroids followed by early surgical resection of large amblyogenic eyelid hemangiomas in infants. Clin Ophthalmol. 2013 27 May;7:955-8. PMID: 2013347426; X-4

3401. Eladl T, Elassal M, Dabbour A, et al. Dynamic contrast enhanced MRI versus histology in diagnosis of hepatocellular tumors. Hepatol Int. 2013 June;7:S685-S6. PMID: 71309348; X-1

3402. Ercan TE, Oztunc F, Celkan T, et al. Macrocephaly-capillary malformation syndrome in a newborn with tetralogy of fallot and sagittal sinus thrombosis. J Child Neurol. 2013 Jan;28(1):115-9. PMID: 22451530; X-1

3403. Erdem E, Gokdemir Y, Unal F, et al. Flexible bronchoscopy as a valuable tool in the evaluation of infants with stridor. Eur Arch Otorhinolaryngol. 2013 Jan;270(1):21-5. PMID: 22639201; X-1

3404. Falardeau J, Lobb BM, Golden S, et al. The use of acetazolamide during pregnancy in intracranial hypertension patients. J Neuroophthalmol. 2013 Mar;33(1):9-12. PMID: 22635167; X-1

3405. Fernandez-Pineda I, Lopez-Gutierrez JC, Chocarro G, et al. Long-term outcome of vincristine-aspirin-ticlopidine (VAT) therapy for vascular tumors associated with Kasabach-Merritt phenomenon. Pediatr Blood Cancer. 2013 Sep;60(9):1478-81. PMID: 23609996; X-1

3406. Fisher MM, Palomo P, Zapatta F. INDEX OF SUSPICION. Case 2: Hematochezia in a Neonate. Pediatrics. 2013:280-3. PMID: X-1

3407. Francisco T, Goncalves RM, Borges C, et al. Multiple haemangiomas, diaphragmatic eventration and Beckwith-Wiedemann syndrome: an unusual association. BMJ Case Rep. 2013;2013PMID: 23964040; X-1, X-2

3408. Friedman BJ, Shah KN, Taylor JA, et al. Congenital myofibroma masquerading as an ulcerated infantile hemangioma in a neonate. Pediatr Dermatol. 2013;30(6):e248-9. PMID: 22276856; X-1, X-3

3409. Gaines SA, Blum C, Chiu ES. Nasal tip infantile hemangioma, a case of mistaken identity. J La State Med Soc. 2013 Sep-Oct;165(5):269-72. PMID: 24350527; X-1

3410. Gallarreta FW, Pieroni KA, Mantovani CP, et al. Oral changes stemming from hemangioma of the tongue. Pediatr Dent. 2013 Mar-Apr;35(2):E75-8. PMID: 23635974; X-2

3411. Giron-Vallejo O, Lopez-Gutierrez JC, Fernandez-Pineda I. Diagnosis and treatment of Parkes Weber syndrome: a review of 10 consecutive patients. Ann Vasc Surg. 2013 Aug;27(6):820-5. PMID: 23880459; X-1

3412. Gold RS, Correa M, Fox C, et al. Systemic propranolol effective in infantile capillary hemangiomas of eyelid... including commentary by Gold RS. Ocular Surgery News. 2013;31(6):30-. PMID: X-2

3413. Gomulka J, Siegel DH, Drolet BA. Dramatic shift in the infantile hemangioma treatment paradigm at a single institution. Pediatr Dermatol. 2013;30(6):751-2. PMID: 24117504; X-3, X-4

3414. Goswamy J, Aggarwal R, Bruce IA, et al. Kasabach-Merritt syndrome in a child with upper airway compromise and spontaneous periorbital bruising. Ear Nose Throat J. 2013 Jun;92(6):E16. PMID: 23780597; X-1, X-2

3415. Gunes M, Keles MO, N.S CI, et al. Cavernous hemangioma of the scrotum treated with local steroid: Case report

Lokal steroid ile tedavi edilen skrotumun kavernoz hemanjiyomu. Turkiye Klinikleri Journal of Medical Sciences. 2013;33(1):241-3. PMID: 2013020459; X-1, X-2

3416. Hackett BC, Phelan E, Ryan A, et al. Use of systemic corticosteroids in management of a large congenital haemangioma of the scalp. Pediatr Dermatol. 2013;30(6):e121-4. PMID: 23004357; X-1

3417. Hasan M, Rahman M, Hoque S, et al. Propranolol for hemangiomas. Pediatr Surg Int. 2013 Mar;29(3):257-62. PMID: 23247833; X-3

3418. Hassan Y, Osman AK, Altyeb A. Noninvasive management of hemangioma and vascular malformation using intralesional bleomycin injection. Ann Plast Surg. 2013 Jan;70(1):70-3. PMID: 23249476; X-3, X-4

3419. Herschthal J, Wulkan A, George M, et al. Additive effect of propranolol and pulsed dye laser for infantile hemangioma. Dermatol Online J. 2013 Jun;19(6):18570. PMID: 24011319; X-2

3420. Hery G, Quarello E, Gorincour G, et al. Extrahepatic vitelline vein aneurysm: prenatal diagnosis and follow up. J Pediatr Surg. 2013 Aug;48(8):e1-4. PMID: 23932633; X-1

3421. Higashino M, Kawata R, Haginomori S, et al. Novel differential diagnostic method for superficial/deep tumor of the parotid gland using ultrasonography. Head Neck. 2013 Aug;35(8):1153-7. PMID: 22907914; X-1

3422. Hou F, Dai Y, Dornhoffer JR, et al. Expression of endoglin (CD105) and endothelial nitric oxide synthase in head and neck arteriovenous malformations. JAMA Otolaryngol Head Neck Surg. 2013 Mar;139(3):237-43. PMID: 23657220; X-1

3423. Howell CM, Davis MS, Callanan DL. Stepping outside the box: an adolescent with a new-onset seizure. Pediatr Emerg Care. 2013 Sep;29(9):1011-2. PMID: 24201984; X-1

3424. Hynes S, Narasimhan K, Courtemanche DJ, et al. Complicated infantile hemangioma of the lip: outcomes of early versus late resection. Plast Reconstr Surg. 2013 Mar;131(3):373e-9e. PMID: 23446587; X-4

3425. Izadpanah A, Izadpanah A, Kanevsky J, et al. Propranolol versus corticosteroids in the treatment of infantile hemangioma: a systematic review and meta-analysis. Plast Reconstr Surg. 2013 Mar;131(3):601-13. PMID: 23142941; X-2

3426. Jakubowski LA, Chun RH, Drolet BA, et al. Misdiagnosed as infantile hemangioma: Early presentation of small vessel-rich AVM. Int J Pediatr Otorhinolaryngol Extra. 2013 September;8(3):71-4. PMID: 2013541818; X-1

3427. Jashari H, Hyseni N, Llullaku S, et al. Hemangiomas of the anterior urethra - Presentation and treatment in children. Eur Urol. 2013 October;12 (4):e1184. PMID: 71275180; X-2

3428. Javvaji S, Frieden IJ. Response of tufted angiomas to low-dose aspirin. Pediatr Dermatol. 2013 Jan-Feb;30(1):124-7. PMID: 22429045; X-1

3429. Jennings S, Tharion J, Jones P, et al. Bronchial haemangioma: exceptionally rare cause of haemoptysis. Heart Lung Circ. 2013 Dec;22(12):1030-2. PMID: 24314894; X-1

3430. Jia H, Huang Q, Lu J, et al. Microdebrider removal under suspension laryngoscopy: an alternative surgical technique for subglottic hemangioma. Int J Pediatr Otorhinolaryngol. 2013 Sep;77(9):1424-9. PMID: 23845535; X-4

3431. Kagami S, Kuwano Y, Shibata S, et al. Propranolol is more effective than pulsed dye laser and cryosurgery for infantile hemangiomas. Eur J Pediatr. 2013 Nov;172(11):1521-6. PMID: 23812512; X-3, X-4

3432. Kanno H, Kuratsu J, Nishikawa R, et al. Clinical features of patients bearing central nervous system hemangioblastoma in von Hippel-Lindau disease. Acta Neurochir (Wien). 2013 Jan;155(1):1-7. PMID: 23080552; X-1

3433. Karpe A, Suganeswari G. Spontaneous vitreous hemorrhage in a case of retinal cavernous hemangioma: a rare presentation. JAMA Ophthalmol. 2013 Jul;131(7):897. PMID: 23846203; X-1

3434. Kasapoglu F, Ozdemircan T, Erisen L. Laryngeal plexiform neurofibroma in a child. Ear Nose Throat J. 2013 Jun;92(6):E31. PMID: 23780601; X-1

3435. Kaushik SB, Kwatra SG, McLean TW, et al. Segmental ulcerated perineal hemangioma of infancy: a complex case of PELVIS syndrome successfully treated using a multidisciplinary approach. Pediatr Dermatol. 2013;30(6):e257-8. PMID: 23278237; X-1, X-2

3436. Kawano R, Takemoto S, Shimamatsu K, et al. Fetomaternal hemorrhage with intraplacental chorioangioma. J Obstet Gynaecol Res. 2013 Feb;39(2):583-7. PMID: 22925543; X-1

3437. Kaylani S, Theos AJ, Pressey JG. Treatment of infantile hemangiomas with sirolimus in a patient with PHACE syndrome. Pediatr Dermatol. 2013;30(6):e194-7. PMID: 23316753; X-2

3438. Khalatbari MR, Hamidi M, Moharamzad Y. Acute presentation of solitary spinal epidural cavernous angioma in a child. J Coll Physicians Surg Pak. 2013 May;23(5):364-6. PMID: 23673181; X-1

3439. Kim YH, Lee GH, Lee SH, et al. An acquired tufted angioma of the nasal cavity. Auris Nasus Larynx. 2013 Dec;40(6):581-3. PMID: 23518006; X-1

3440. Kryvenko ON, Epstein JI. Testicular hemangioma: a series of 8 cases. Am J Surg Pathol. 2013 Jun;37(6):860-6. PMID: 23665824; X-1

3441. Kumar GV, Deenadayalan M, Hemalatha, et al. Kaposiform hemangioendothelioma in a 3 month old infant-a case report. Indian J Hematol Blood Transfus. 2013 December;29 (4):332. PMID: 71223203; X-1

3442. Kumar S, Taneja B, Saxena KN, et al. Anaesthetic management of a neonate with Kasabach-Merritt syndrome. Indian J Anaesth. 2013 May-June;57(3):292-4. PMID: 2013477142; X-1

3443. Kumbhar S, Saraf R, Limaye U. Middle ear and mastoid hemangioma treated by neurointerventional techniques. Indian J Otolaryngol. 2013 April-June;19(2):85-7. PMID: 2013420557; X-2

3444. Kwon CS, Sheth SA, Walcott BP, et al. Long-term seizure outcomes following resection of supratentorial cavernous malformations. Clin Neurol Neurosurg. 2013 Nov;115(11):2377-81. PMID: 24075713; X-1

3445. Laing EL, Brasch HD, Steel R, et al. Verrucous hemangioma expresses primitive markers. J Cutan Pathol. 2013 Apr;40(4):391-6. PMID: 23379586; X-1

3446. Lance EI, Sreenivasan AK, Zabel TA, et al. Aspirin use in Sturge-Weber syndrome: side effects and clinical outcomes. J Child Neurol. 2013 Feb;28(2):213-8. PMID: 23112247; X-1

3447. Leaute-Labreze C. Beta-blockers: An unexpected but beneffcial effect on infantile hemangiomas

Les betabloquants: Un effet inattendu mais benefique sur l'evolution des hemangiomes infantiles. Sang Thrombose Vaisseaux. 2013 March-June;25(3):149-54. PMID: 2013465529; X-6

3448. Lee NY, Cho HK, Kim KH, et al. A girl with sternal malformation/vascular dysplasia association. Korean J Pediatr. 2013;56(3):135-8. PMID: 2013181362; X-2

3449. Li D, Yang Y, Hao SY, et al. Hemorrhage risk, surgical management, and functional outcome of brainstem cavernous malformations. J Neurosurg. 2013 Oct;119(4):996-1008. PMID: 23952884; X-1

3450. Loizzi M, De Palma A, Pagliarulo V, et al. Propranolol as first-line treatment of a severe subglottic haemangioma. Eur J Cardiothorac Surg. 2013 Jan;43(1):187-9. PMID: 23045296; X-2

3451. Luke RR, Malik SI, Hernandez AW, et al. Atypical imaging evolution of sturge-weber syndrome without facial nevus. Pediatr Neurol. 2013 Feb;48(2):143-5. PMID: 23337009; X-1

3452. Mahelkova G, Filous A, Odehnal M, et al. Corneal changes assessed using confocal microscopy in patients with unilateral buphthalmos. Invest Ophthalmol Vis Sci. 2013 Jun;54(6):4048-53. PMID: 23696604; X-1

3453. Mai HM, Zheng JW, Wang YA, et al. CD133 selected stem cells from proliferating infantile hemangioma and establishment of an in vivo mice model of hemangioma. Chin Med J (Engl). 2013 Jan;126(1):88-94. PMID: 23286484; X-1, X-3

3454. Mai JC, Ramanathan D, Kim LJ, et al. Surgical resection of cavernous malformations of the brainstem: evolution of a minimally invasive technique. World Neurosurg. 2013 May-Jun;79(5-6):691-703. PMID: 23017589; X-1

3455. Maleki M, Farhat AS, Nahidi Y, et al. A prevalence survey of pigmented and vascular birthmarks in 1000 newborns from the Northeast of Iran. Iranian Journal of Dermatology. 2013;16(64):64-8. PMID: 2013654416; X-2

3456. Marqueling AL, Oza V, Frieden IJ, et al. Propranolol and infantile hemangiomas four years later: a systematic review. Pediatr Dermatol. 2013 Mar-Apr;30(2):182-91. PMID: 23405852; X-1, X-2

3457. Martin K, Blei F, Chamlin SL, et al. Propranolol treatment of infantile hemangiomas: anticipatory guidance for parents and caretakers. Pediatr Dermatol. 2013 Jan-Feb;30(1):155-9. PMID: 23316721; X-2

3458. Maruani A, Brown S, Lorette G, et al. Lack of effect of propranolol in the treatment of lymphangioma in two children. Pediatr Dermatol. 2013 May-Jun;30(3):383-5. PMID: 23005572; X-1

3459. Masetti R, Colecchia A, Rondelli R, et al. Benign hepatic nodular lesions after treatment for childhood cancer. J Pediatr Gastroenterol Nutr. 2013 Feb;56(2):151-5. PMID: 22922376; X-1

3460. Matuszczak E, Oksiuta M, Debek W, et al. Topical timolol gel for the treatment of residual facial hemangioma previously treated with propranolol. Pediatr Pol. 2013 February;88(1):116-9. PMID: 2013111225; X-2

3461. Maya J, Blanco G, Maldonado R. Diffuse neonatal hemangiomatosis. Bol Med Hosp Infant Mex. 2013;70(1):35-40. PMID: 2013286733; X-1, X-2

3462. Mayer M, Minichmayr A, Klement F, et al. Tocolysis with the beta-2-sympathomimetic hexoprenaline increases occurrence of infantile haemangioma in preterm infants. Arch Dis Child Fetal Neonatal Ed. 2013 Mar;98(2):F108-11. PMID: 22611112; X-3

3463. McGee P, Miller S, Black C, et al. Propranolol for infantile haemangioma: a review of current dosing regime in a regional paediatric hospital. Ulster Med J. 2013 Jan;82(1):16-20. PMID: 23620625; X-4

3464. McMahon P, Goddard D, Frieden IJ. Pediatric dermatology inpatient consultations: a retrospective study of 427 cases. J Am Acad Dermatol. 2013 Jun;68(6):926-31. PMID: 23352278; X-1

3465. Melo JN, Rotter A, Rivitti-Machado MC, et al. Propranolol for treatment of infantile hemangiomas. An Bras Dermatol. 2013 Nov-Dec;88(6 Suppl 1):220-3. PMID: 24346925; X-3, X-4

3466. Mendiratta V, Varghese B, Chander R, et al. Successful management of airway hemangioma with propranolol. Int J Dermatol. 2013 Jun;52(6):750-2. PMID: 23679882; X-2

3467. Mendoza-Cruz AC, Wargon O, Adams S, et al. Hypothalamic-pituitary-adrenal axis recovery following prolonged prednisolone therapy in infants. J Clin Endocrinol Metab. 2013 Dec;98(12):E1936-40. PMID: 24081733; X-3, X-4

3468. Metwalley KA, Farghaly HS. Consumptive hypothyroidism in an Egyptian baby with benign neonatal hemangiomatosis: A case report. J Med Case Rep. 2013;7(48)PMID: 2013135930; X-1

3469. Mezhir JJ, Fourman LT, Do RK, et al. Changes in the management of benign liver tumours: an analysis of 285 patients. HPB (Oxford). 2013 Feb;15(2):156-63. PMID: 23297727; X-1

3470. Mirza B, Shi WY, Phadke R, et al. Strawberries on the brain--intracranial capillary hemangioma: two case reports and systematic literature review in children and adults. World Neurosurg. 2013 Dec;80(6):900.e13-21. PMID: 23247022; X-1

3471. Miura A, Akagi S, Nakamura K, et al. Different sizes of centrilobular ground-glass opacities in chest high-resolution computed tomography of patients with pulmonary veno-occlusive disease and patients with pulmonary capillary hemangiomatosis. Cardiovasc Pathol. 2013 Jul-Aug;22(4):287-93. PMID: 23312620; X-1

3472. Moehrle M, Leaute-Labreze C, Schmidt V, et al. Topical timolol for small hemangiomas of infancy. Pediatr Dermatol. 2013 Mar-Apr;30(2):245-9. PMID: 22471694; X-4

3473. Mohindra S, Sodhi HS, Rane S. Tumefactive presentation of a supratentorial cavernous hemangioma: A report of two cases. J Pediatr Neurosci. 2013 September-December;8(3):232-4. PMID: 2014027375; X-1

3474. Mullen M, Rabban J, Frieden IJ. Sacrococcygeal teratoma masquerading as congenital hemangioma. Pediatr Dermatol. 2013 Jan-Feb;30(1):112-6. PMID: 22353016; X-1

3475. Murphy RK, Reynolds MR, Mansur DB, et al. Gamma knife surgery for a hemangioma of the cavernous sinus in a child. J Neurosurg Pediatr. 2013 Jan;11(1):74-8. PMID: 23082966; X-1

3476. Najafi Sani M. Fatty liver disease in children. Iran J Pediatr. 2013 October;23:S17. PMID: 71257066; X-1

3477. Nakagawa T, Watanabe H, Nakazato K, et al. Periodic appearance and disappearance of a chest wall (serratus anterior development) cavernous hemangioma that was finally resected in a child. Gen Thorac Cardiovasc Surg. 2013 Aug;61(8):469-72. PMID: 23011518; X-1

3478. Nanduri J. Epigenetic factors and the pathophysiological manifestation of sleep apnea. Somnologie. 2013 October;17:18. PMID: 71336340; X-1

3479. Neri I, Piccolo V, Russo T, et al. Congenital primarily ulcerated hemangioma mimicking cleft lip. J Pediatr. 2013 Apr;162(4):882-.e1. PMID: 23375363; X-1, X-2

3480. Nieuwenhuis K, de Laat PC, Janmohamed SR, et al. Infantile hemangioma: treatment with short course systemic corticosteroid therapy as an alternative for propranolol. Pediatr Dermatol. 2013 Jan-Feb;30(1):64-70. PMID: 22958179; X-4

3481. Nikoubashman O, Wiesmann M, Tournier-Lasserve E, et al. Natural history of cerebral dot-like cavernomas. Clin Radiol. 2013 Aug;68(8):e453-9. PMID: 23663874; X-1

3482. Niwald A, Lewandowska M, Moll A, et al. The rare case of periocular vascular malformations

Rzadki przypadek malformacji naczyniowej umiejscowionej w okolicy okologalkowej. Family Medicine and Primary Care Review. 2013 April\June;15(2):275-7. PMID: 2013788065; X-1

3483. Niwald A, Lewandowska M, Orawiec B, et al. Interdisciplinary collaboration in the treatment of infantile hemangiomas

Wielospecjalistyczna wspolpraca medyczna w leczeniu naczyniakow wczesnodziecie{ogonek}cych. Family Medicine and Primary Care Review. 2013 July/September;15(3):502-3. PMID: 2013787994; X-2

3484. O TM, Scheuermann-Poley C, Tan M, et al. Distribution, clinical characteristics, and surgical treatment of lip infantile hemangiomas. JAMA Facial Plast Surg. 2013 Jul-Aug;15(4):292-304. PMID: 23752875; X-3, X-4

3485. Osaki TH, Jakobiec FA, Mendoza PR, et al. Immunohistochemical investigations of orbital infantile hemangiomas and adult encapsulated cavernous venous lesions (malformation versus hemangioma). Ophthal Plast Reconstr Surg. 2013 May-Jun;29(3):183-95. PMID: 23584448; X-1, X-2

3486. Osorio MJ, Gajardo OP, Tapia MC. Propranolol for the treatment of subglotic hemangioma- A new therapeutic alternative

Hemangioma subglotico tratado con propranolol. Una nueva alternativa terapeutica. Caso clinico. Rev Chil Pediatr. 2013 April;84(2):182-8. PMID: 2013581309; X-2

3487. Ozcan KM, Ozdas T, Baran H, et al. Hemolacria: case report. Int J Pediatr Otorhinolaryngol. 2013 Jan;77(1):137-8. PMID: 23040961; X-1

3488. Ozdemir T, Arikan A. Postoperative apnea after inguinal hernia repair in formerly premature infants: impacts of gestational age, postconceptional age and comorbidities. Pediatr Surg Int. 2013 Aug;29(8):801-4. PMID: 23780479; X-1

3489. Ozeki M, Kanda K, Kawamoto N, et al. Propranolol as an alternative treatment option for pediatric lymphatic malformation. Tohoku J Exp Med. 2013;229(1):61-6. PMID: 23257321; X-1

3490. Ozkiris M, Aydin R, Seckin S, et al. A rare cause of pediatric nasal obstruction and epistaxis: Nasal septal mixed hemangioma. Int J Pediatr Otorhinolaryngol Extra. 2013 September;8(3):104-7. PMID: 2013541808; X-1, X-2

3491. Parikh SR, Darrow DH, Grimmer JF, et al. Propranolol use for infantile hemangiomas: American Society of Pediatric Otolaryngology Vascular Anomalies Task Force practice patterns. JAMA Otolaryngol Head Neck Surg. 2013 Feb;139(2):153-6. PMID: 23429945; X-1

3492. Partanen TA, Vuola P, Jauhiainen S, et al. Neuropilin-2 and vascular endothelial growth factor receptor-3 are up-regulated in human vascular malformations. Angiogenesis. 2013 Jan;16(1):137-46. PMID: 22961441; X-1

3493. Patil A, Pattanshetti C, Varekar A, et al. Oral capillary haemangioma mimicking pyogenic granuloma: a challenge for diagnosis and management. BMJ Case Rep. 2013;2013PMID: 23417375; X-1, X-2

3494. Phung J, Krogstad P, Mathern GW. Etiology associated with developing posthemispherectomy hydrocephalus after resection-disconnection procedures. J Neurosurg Pediatr. 2013 Nov;12(5):469-75. PMID: 24011367; X-1

3495. Popescu E, Trandafir V, Negru D, et al. Hemangioma of the parotid gland: case report. Rev Med Chir Soc Med Nat Iasi. 2013 Jan-Mar;117(1):227-32. PMID: 24505920; X-2

3496. Pride HB, Tollefson M, Silverman R. What's new in pediatric dermatology?: part II. Treatment. J Am Acad Dermatol. 2013 Jun;68(6):899.e1-11; quiz 910-2. PMID: 23680205; X-2

3497. Qiu Y, Ma G, Lin X, et al. Treating protruding infantile hemangiomas with topical imiquimod 5% cream caused severe local reactions and disfiguring scars. Pediatr Dermatol. 2013 May-Jun;30(3):342-7. PMID: 23046440; X-4

3498. Quintard B, Gana K, Constant A, et al. Social isolation in parents of children with hemangiomas: effects of coping styles and emotional distress. Psychol Health Med. 2013;18(6):698-704. PMID: 23387298; X-1

3499. Radvany MG, Rigamonti D, Gailloud P. Angiographic detection of cerebral cavernous malformations with C-arm cone beam CT imaging in three patients. BMJ Case Rep. 2013;2013PMID: 23704473; X-1

3500. Raigani S, Agamanolis D, Soldes OS, et al. Intra-abdominal (Type IV) sacrococcygeal teratoma presenting with buttock hemangioma. Pediatr Surg Int. 2013 Dec;29(12):1341-4. PMID: 24057924; X-2

3501. Rees A. CME/CE. CASE #1. Red scalp plaque with painful ulceration. Clinical Advisor. 2013;16(2):55-7. PMID: 2012015007; X-1

3502. Restrepo R. Multimodality imaging of vascular anomalies. Pediatr Radiol. 2013 Mar;43 Suppl 1:S141-54. PMID: 23478930; X-2

3503. Robbins K. CME/CE Dermatologic Look A-likes. Vascular papules. Clinical Advisor. 2013;16(7):77-80. PMID: X-1

3504. Rodriguez-Ayala G, de la Vega A, Correa-Rivas M, et al. Chorioangioma: an uncommon cause of hydramnios and consequent preterm labor in second trimester of pregnancy. Bol Asoc Med P R. 2013;105(1):36-9. PMID: 23767383; X-1

3505. Rosler J, Laute-Labreze C, Adams D. Medical therapy for vascular anomalies: From propranolol for infantile hemangioma to sirolimus for lymphangiomatosis. Monatsschr Kinderheilkd. 2013 November;161 (11):1077. PMID: 71345238; X-1, X-2

3506. Rossler J, Haubold M, Gilsbach R, et al. beta1-Adrenoceptor mRNA level reveals distinctions between infantile hemangioma and vascular malformations. Pediatr Res. 2013 Apr;73(4 Pt 1):409-13. PMID: 23370410; X-1, X-3

3507. Saia M, Mantoan D, Buja A, et al. Increased rate of day surgery use for inguinal and femoral hernia repair in a decade of hospital admissions in the Veneto Region (north-east Italy): a record linkage study. BMC Health Serv Res. 2013;13:349. PMID: 24028397; X-1

3508. Sajan JA, Tibesar R, Jabbour N, et al. Assessment of pulsed-dye laser therapy for pediatric cutaneous vascular anomalies. JAMA Facial Plast Surg. 2013 Nov-Dec;15(6):434-8. PMID: 24008312; X-4

3509. Savku E, Gunduz K. Our treatment results of circumscribed and diffuse choroidal hemangiomas

Si{dotless}ni{dotless}rli{dotless} ve difuz koroid hemanjiomlari{dotless}nda tedavi sonuclari{dotless}mi{dotless}z. Turk Oftalmoloiji Dergisi. 2013;43(4):216-20. PMID: 2013594497; X-1

3510. Schwartz C, Grillhosl A, Schichor C, et al. Symptomatic cavernous malformations of the brainstem: functional outcome after microsurgical resection. J Neurol. 2013 Nov;260(11):2815-22. PMID: 23974645; X-1

3511. Sharma P, Williams R, Monaghan A. Spontaneous mandibular regeneration: another option for mandibular reconstruction in children? Br J Oral Maxillofac Surg. 2013 Jul;51(5):e63-6. PMID: 22578705; X-1

3512. Shatriah I, Norazizah MA, Wan-Hitam WH, et al. Extensive facial and orbital infantile hemangiomas associated with high intraocular pressure. Pediatr Dermatol. 2013 Jan-Feb;30(1):151-4. PMID: 22329437; X-2

3513. Shehata N, Powell J, Dubois J, et al. Late rebound of infantile hemangioma after cessation of oral propranolol. Pediatr Dermatol. 2013 Sep-Oct;30(5):587-91. PMID: 24016283; X-4

3514. Shields CL, Kaliki S, Al-Dahmash S, et al. Retinal vasoproliferative tumors: comparative clinical features of primary vs secondary tumors in 334 cases. JAMA Ophthalmol. 2013 Mar;131(3):328-34. PMID: 23494037; X-1

3515. Shirol SS, Nimbaragi G, Choukimath SM, et al. Lobular capillary hemangioma in a post-burn scar. Eur J Plast Surg. 2013 May;36(5):323-6. PMID: 2013314888; X-1, X-2

3516. Siddique L, Sreenivasan A, Comi AM, et al. Importance of utilizing a sensitive free thyroxine assay in Sturge-Weber syndrome. J Child Neurol. 2013 Feb;28(2):269-74. PMID: 23112245; X-1

3517. Singla A, Brace O'Neill JE, Smith E, et al. Cavernous malformations of the brain after treatment for acute lymphocytic leukemia: presentation and long-term follow-up. J Neurosurg Pediatr. 2013 Feb;11(2):127-32. PMID: 23215773; X-1

3518. Siri L, Giordano L, Accorsi P, et al. Clinical features of Sturge-Weber syndrome without facial nevus: five novel cases. Eur J Paediatr Neurol. 2013 Jan;17(1):91-6. PMID: 22819211; X-1

3519. Smith SC, Patel RM, Lucas DR, et al. Sinonasal lobular capillary hemangioma: a clinicopathologic study of 34 cases characterizing potential for local recurrence. Head Neck Pathol. 2013 Jun;7(2):129-34. PMID: 23184353; X-1

3520. Soejima Y, Shirabe K, Yoshizumi T, et al. Rex shunt for portal vein thrombosis after adult living donor liver transplantation. Fukuoka Igaku Zasshi. 2013 Nov;104(11):464-8. PMID: 24620643; X-1

3521. Soomro MZ, Arshad M, Ahmad S, et al. New arsenal for infantile haemangioma. Pakistan Journal of Medical and Health Sciences. 2013;7(2):578. PMID: 2013643487; X-2

3522. Sorrell J, Chamlin SL. Topical timolol 0.5% gel-forming solution for small deep facial infantile hemangiomas. Pediatr Dermatol. 2013 Sep-Oct;30(5):592-4. PMID: 23889228; X-3, X-4

3523. Sreenivasan AK, Bachur CD, Lanier KE, et al. Urine vascular biomarkers in Sturge-Weber syndrome. Vasc Med. 2013 Jun;18(3):122-8. PMID: 23720035; X-1

3524. Steiner F, FitzJohn T, Tan ST. Surgical treatment for venous malformation. J Plast Reconstr Aesthet Surg. 2013 Dec;66(12):1741-9. PMID: 24012651; X-1

3525. Stiles JM, Amaya C, Rains S, et al. Targeting of beta adrenergic receptors results in therapeutic efficacy against models of hemangioendothelioma and angiosarcoma. PLoS One. 2013;8(3):e60021. PMID: 23555867; X-1

3526. Stiles JM, Rowntree RK, Amaya C, et al. Gene expression analysis reveals marked differences in the transcriptome of infantile hemangioma endothelial cells compared to normal dermal microvascular endothelial cells. Vasc Cell. 2013;5(1)PMID: 2013315270; X-1

3527. Su IC, Krishnan P, Rawal S, et al. Magnetic resonance evolution of de novo formation of a cavernoma in a thrombosed developmental venous anomaly: a case report. Neurosurgery. 2013 Oct;73(4):E739-44; discussion E45. PMID: 23728455; X-1

3528. Sullivan CT, Christian SL, Shieh JTC, et al. X chromosome-inactivation patterns in 31 individuals with PHACE syndrome. Molecular Syndromology. 2013 March;4(3):114-8. PMID: 2013239825; X-1

3529. Szavay P, Kurth R, Schaefer J, et al. A rare cause for extrahepatic biliary tract obstruction: juvenile hepatic hilar hemangioma. Eur J Pediatr Surg. 2013 Oct;23(5):415-7. PMID: 23093433; X-2

3530. Takasugi M, Fujii S, Shinohara Y, et al. Parenchymal hypointense foci associated with developmental venous anomalies: evaluation by phase-sensitive MR Imaging at 3T. AJNR Am J Neuroradiol. 2013 Oct;34(10):1940-4. PMID: 23598832; X-1

3531. Tanabe H, Sahashi K, Kitano T, et al. Effects of oral propranolol on circumscribed choroidal hemangioma: a pilot study. JAMA Ophthalmol. 2013 Dec;131(12):1617-22. PMID: 24158615; X-1

3532. Tanriverdi S, Terek D, Koroglu OA, et al. Neonatal status epilepticus controlled with levetiracetam at Sturge Weber syndrome. Brain Dev. 2013 Apr;35(4):367-71. PMID: 22804835; X-1

3533. Taran K, Bojanowska E, Przewratil P, et al. Childhood vascular lesions

Zmiany naczyniowe wieku rozwojowego. Family Medicine and Primary Care Review. 2013 April\June;15(2):181-2. PMID: 2013788036; X-2, X-3

3534. Tarchichi T, Wong K, Fisher MM, et al. Index of suspicion. Pediatr Rev. 2013 Jun;34(6):280-4. PMID: 23729777; X-1

3535. Thaivalappil S, Bauman N, Saieg A, et al. Propranolol-mediated attenuation of MMP-9 excretion in infants with hemangiomas. JAMA Otolaryngol Head Neck Surg. 2013 Oct;139(10):1026-31. PMID: 24135743; X-3

3536. Thakral A, Sharma SM. Cervicofacial hemangiomas: pattern, clinical management, and treatment outcomes. Oral Surg Oral Med Oral Pathol Oral Radiol. 2013 Dec;116(6):e457-64. PMID: 22901655; X-4

3537. Todorovich SM, Khan ZA. Elevated T-box 2 in infantile hemangioma stem cells maintains an adipogenic differentiation-competent state. Dermatoendocrinol. 2013 June-December;5(3):352-7. PMID: 2014186039; X-1

3538. Tongsong T, Luewan S, Srisupundit K, et al. Hemodynamic assessment of indomethacin-induced fetal heart failure in high-output state. J Clin Ultrasound. 2013 Sep;41(7):438-40. PMID: 23712591; X-1

3539. Tsutsumi S, Ogino I, Miyajima M, et al. Genomic causes of multiple cerebral cavernous malformations in a Japanese population. J Clin Neurosci. 2013 May;20(5):667-9. PMID: 23485406; X-1

3540. Tu JB, Ma RZ, Dong Q, et al. Induction of apoptosis in infantile hemangioma endothelial cells by propranolol. Exp Ther Med. 2013 August;6(2):574-8. PMID: 2013417723; X-1, X-3

3541. Vassallo P, Forte R, Di Mezza A, et al. Treatment of infantile capillary hemangioma of the eyelid with systemic propranolol. Am J Ophthalmol. 2013 Jan;155(1):165-70.e2. PMID: 22967870; X-4

3542. Wang L, Liu L, Wang G, et al. Congenital disseminated tufted angioma. J Cutan Pathol. 2013 Apr;40(4):405-8. PMID: 23373432; X-1

3543. Wang X, Tao Z, You C, et al. Extended resection of hemosiderin fringe is better for seizure outcome: a study in patients with cavernous malformation associated with refractory epilepsy. Neurol India. 2013 May-Jun;61(3):288-92. PMID: 23860150; X-1

3544. Watanabe Y, Kanamori Y, Uchida K, et al. Isolated hypoganglionosis: results of a nationwide survey in Japan. Pediatr Surg Int. 2013 Nov;29(11):1127-30. PMID: 23975018; X-1

3545. Wilmanska D, Antosik-Biernacka A, Przewratil P, et al. The role of MRI in diagnostic algorithm of cervicofacial vascular anomalies in children. Pol J Radiol. 2013;78(2):7-14. PMID: 2013376203; X-4

3546. Wiseman DH, Mercer J, Tylee K, et al. Management of mucopolysaccharidosis type IH (Hurler's syndrome) presenting in infancy with severe dilated cardiomyopathy: a single institution's experience. J Inherit Metab Dis. 2013 Mar;36(2):263-70. PMID: 22718273; X-1

3547. Wu CH, Tsai TM, Liau JY, et al. Expansile kaposiform hemangioendothelioma deformed thoracic cage in an adult. Ann Thorac Surg. 2013 Nov;96(5):1854-7. PMID: 24182473; X-1

3548. Xie W, Xie H, Liu F, et al. Propranolol induces apoptosis of human umbilical vein endothelial cells through downregulation of CD147. Br J Dermatol. 2013 Apr;168(4):739-48. PMID: 23528058; X-1

3549. Yang GZ, Li J, Jin H. Giant mesenteric hemangioma of cavernous and venous mixed type: a rare case report. BMC Surg. 2013;13:50. PMID: 24168418; X-1

3550. Yao Q, Hu X, Huang G, et al. A case of diaphragmatic infantile hemangioma. J Perinatol. 2013 Jul;33(7):576-7. PMID: 23803680; X-2

3551. Yasui N, Koh K, Kato M, et al. Kasabach-Merritt phenomenon: a report of 11 cases from a single institution. J Pediatr Hematol Oncol. 2013 Oct;35(7):554-8. PMID: 23389504; X-1

3552. Yen KG, Hussein MA. Oral propranolol in the management of periocular capillary hemangiomas. Int Ophthalmol Clin. 2013 Summer;53(3):143-51. PMID: 23751438; X-2

3553. Yeo KK, Puscasiu E, Keating RF, et al. Durable response of intracranial cellular hemangioma to bevacizumab and temozolomide. J Neurosurg Pediatr. 2013 Jun;11(6):682-6. PMID: 23540527; X-1

3554. Yin J, Li H, Yin N, et al. Autologous fat grafting in lip reconstruction following hemangioma treatment. J Craniofac Surg. 2013 Mar;24(2):346-9. PMID: 23524690; X-3, X-4

3555. Yonekawa Y, MacDonald SM, Shildkrot Y, et al. Standard fractionation low-dose proton radiotherapy for diffuse choroidal hemangiomas in pediatric Sturge-Weber syndrome. J aapos. 2013 Jun;17(3):318-22. PMID: 23618630; X-1

3556. Yonekawa Y, Orbach DB, Trief D, et al. Intra-arterial chemotherapy for group C retinoblastoma with adjacent high-flow infantile hemangioma. Ophthalmic Surg Lasers Imaging. 2013 September-October;44(5):490-2. PMID: 2013620040; X-2

3557. Yonekawa Y, Orbach DB, Trief D, et al. Intra-arterial chemotherapy for group C retinoblastoma with adjacent high-flow infantile hemangioma. Ophthalmic Surg Lasers Imaging Retina. 2013 Sep-Oct;44(5):490-2. PMID: 24044714; X-3

3558. Young PC, Korgenski K, Buchi KF. Early readmission of newborns in a large health care system. Pediatrics. 2013 May;131(5):e1538-44. PMID: 23569092; X-1

3559. Yuan SM, Hong ZJ, Chen HN, et al. Kaposiform hemangioendothelioma complicated by Kasabach-Merritt phenomenon: ultrastructural observation and immunohistochemistry staining reveal the trapping of blood components. Ultrastruct Pathol. 2013 Dec;37(6):452-5. PMID: 24134598; X-1

3560. Zhang L, Mai HM, Zheng J, et al. Preliminary study on plasma RPN concentration of patients with infantile hemangioma treated with propranolol. Int J Clin Exp Med. 2013 01 Jun;6(5):342-5. PMID: 2013332209; X-2, X-3

3561. Zhang P, Liu L, Cao Y, et al. Cerebellar cavernous malformations with and without associated developmental venous anomalies. BMC Neurol. 2013;13:134. PMID: 24088363; X-1

3562. Zhou SY, Li HB, Mao YM, et al. Successful treatment of Kasabach-Merritt syndrome with transarterial embolization and corticosteroids. J Pediatr Surg. 2013 Mar;48(3):673-6. PMID: 23480932; X-1, X-2

3563. Zoller B, Ji J, Sundquist J, et al. Shared and nonshared familial susceptibility to surgically treated inguinal hernia, femoral hernia, incisional hernia, epigastric hernia, and umbilical hernia. J Am Coll Surg. 2013 Aug;217(2):289-99.e1. PMID: 23870221; X-1

3564. Zou HX, Jia J, Zhang WF, et al. Propranolol inhibits endothelial progenitor cell homing: a possible treatment mechanism of infantile hemangioma. Cardiovasc Pathol. 2013 May-Jun;22(3):203-10. PMID: 23151525; X-1

3565. Adini I, Ghosh K, Adini A, et al. Melanocyte-secreted fibromodulin promotes an angiogenic microenvironment. J Clin Invest. 2014 Jan 2;124(1):425-36. PMID: 24355922; X-1

3566. Angelini A, Mavrogenis AF, Gambarotti M, et al. Surgical treatment and results of 62 patients with epithelioid hemangioendothelioma of bone. J Surg Oncol. 2014 Jun;109(8):791-7. PMID: 24643837; X-1

3567. Canty KM, Horii KA, Ahmad H, et al. Multiple cutaneous and hepatic hemangiomas in infants. South Med J. 2014 Mar;107(3):159-64. PMID: 24937333; X-3, X-4

3568. Charles E, Milroy C, Goldstraw NK, et al. A 3 month old infant with a "strawberry" red mass on her nose. Bmj. 2014;348:g3810. PMID: 24923589; X-2

3569. Croteau SE, Kozakewich HP, Perez-Atayde AR, et al. Kaposiform lymphangiomatosis: a distinct aggressive lymphatic anomaly. J Pediatr. 2014 Feb;164(2):383-8. PMID: 24252784; X-1

3570. de Graaf M, Knol MJ, Totte JE, et al. E-learning enables parents to assess an infantile hemangioma. J Am Acad Dermatol. 2014 May;70(5):893-8. PMID: 24524882; X-1

3571. Demertzis JL, Kyriakos M, Loomans R, et al. Synovial hemangioma of the hip joint in a pediatric patient. Skeletal Radiol. 2014 Jan;43(1):107-13. PMID: 24061493; X-1

3572. Frischer JM, Gatterbauer B, Holzer S, et al. Microsurgery and radiosurgery for brainstem cavernomas: effective and complementary treatment options. World Neurosurg. 2014 Mar-Apr;81(3-4):520-8. PMID: 24440458; X-1

3573. Funk T, Prok L, Brown LD, et al. Multifocal vascular tumors and fetal hydrops. J Pediatr. 2014 May;164(5):1214-8. PMID: 24433827; X-1, X-2

3574. Gordillo GM, Biswas A, Khanna S, et al. Dicer knockdown inhibits endothelial cell tumor growth via microRNA 21a-3p targeting of Nox-4. J Biol Chem. 2014 Mar 28;289(13):9027-38. PMID: 24497637; X-1

3575. Han EC, Kim SH, Kim HY, et al. Gastrointestinal hemangioma in childhood: A rare cause of gastrointestinal bleeding. Korean J Pediatr. 2014 May;57(5):245-9. PMID: 2014347954; X-1, X-2

3576. Hussain S, Butt IH, Ali S. Treatment of bleeding nasal polyp. Pakistan Journal of Medical and Health Sciences. 2014 January-March;8(1):25-7. PMID: 2014311986; X-1

3577. Inal FY, Celebi S, Uysal AI, et al. Comparison of the effects of laparoscopic and open repair techniques on postoperative pain and analgesic consumption in pediatric unilateral inguinal hernia

Tek tarafli{dotless} Inguinal herni operasyonu uygulanan cocuklarda aci{dotless}k ve laparoskopik cerrahi tekniklerinin anestezi suresi, postoperatif agri{dotless} ve analjezik tuketimi uzerine etkilerinin karsi{dotless}lasti{dotless}ri{dotless}lmasi{dotless}. Haseki Tip Bulteni. 2014;52(2):84-8. PMID: 2014407500; X-1

3578. Kai L, Wang Z, Yao W, et al. Sirolimus, a promising treatment for refractory Kaposiform hemangioendothelioma. J Cancer Res Clin Oncol. 2014 Mar;140(3):471-6. PMID: 24464150; X-1

3579. Kamath MP, Bhojwani KM, Bhandarkar AM, et al. Angiolymphoid hyperplasia with eosinophilia of root of nose: A rare phenomenon. J Clin Diagn Res. 2014 15 Mar;8(3):144-5. PMID: 2014202932; X-1

3580. Lee PW, Frieden IJ, Streicher JL, et al. Characteristics of noninvoluting congenital hemangioma: a retrospective review. J Am Acad Dermatol. 2014 May;70(5):899-903. PMID: 24630000; X-1, X-3

3581. Li D, Hao SY, Tang J, et al. Surgical management of pediatric brainstem cavernous malformations. J Neurosurg Pediatr. 2014 May;13(5):484-502. PMID: 24679081; X-1

3582. Li D, Hao SY, Tang J, et al. Clinical course of untreated pediatric brainstem cavernous malformations: hemorrhage risk and functional recovery. J Neurosurg Pediatr. 2014 May;13(5):471-83. PMID: 24635136; X-1, X-3

3583. Lonser RR, Butman JA, Huntoon K, et al. Prospective natural history study of central nervous system hemangioblastomas in von Hippel-Lindau disease. J Neurosurg. 2014 May;120(5):1055-62. PMID: 24579662; X-1

3584. Mikati AG, Tan H, Shenkar R, et al. Dynamic permeability and quantitative susceptibility: related imaging biomarkers in cerebral cavernous malformations. Stroke. 2014 Feb;45(2):598-601. PMID: 24302484; X-1

3585. Nakajima M, Sugano H, Iimura Y, et al. Sturge-Weber syndrome with spontaneous intracerebral hemorrhage in childhood. J Neurosurg Pediatr. 2014 Jan;13(1):90-3. PMID: 24160667; X-1

3586. Nguyen R, Kim J, Shet N, et al. A 2-year-old boy with knee pain, fever, and multiple birthmarks. Clin Pediatr (Phila). 2014 Jan;53(1):98-100. PMID: 24317699; X-2

3587. Piccillo GA, Saitta R, Mondati EGM, et al. The dramatic and unforgettable story of Eusebio and his children. Italian Journal of Medicine. 2014 May;8:102. PMID: 71506399; X-1

3588. Puri A, Pruthi M, Gulia A. Outcomes after limb sparing resection in primary malignant pelvic tumors. Eur J Surg Oncol. 2014 Jan;40(1):27-33. PMID: 24239184; X-1

3589. Rehder KJ, Cheifetz IM, Willson DF, et al. Perceptions of 24/7 in-hospital intensivist coverage on pediatric housestaff education. Pediatrics. 2014 Jan;133(1):88-95. PMID: 24323998; X-1

3590. Rhein LM, Dobson NR, Darnall RA, et al. Effects of caffeine on intermittent hypoxia in infants born prematurely: a randomized clinical trial. JAMA Pediatr. 2014 Mar;168(3):250-7. PMID: 24445955; X-1

3591. Rodgaard JC, Foged T, Bjerre JV, et al. Treatment of infantile hemangiomas before and after the introduction of propranolol: A retrospective study. Eur J Plast Surg. 2014 April;37(4):195-200. PMID: 2014198264; X-3, X-4

3592. Schneider C, Hidalgo ET, Schmitt-Mechelke T, et al. Quality of life after surgical treatment of primary intramedullary spinal cord tumors in children. J Neurosurg Pediatr. 2014 Feb;13(2):170-7. PMID: 24359210; X-1

3593. Shields JA, Pellegrini M, Kaliki S, et al. Retinal vasoproliferative tumors in 6 patients with neurofibromatosis type 1. JAMA Ophthalmol. 2014 Feb;132(2):190-6. PMID: 24357334; X-1

3594. Singh A, Pugh A, Sharif K, et al. A preterm infant with progressive abdominal distension. Infant. 2014;10(2):65-8. PMID: X-1

3595. Singh J, Priyadarshi S, Yadav SS, et al. Large labial hemangioma presenting as lower urinary tract symptom: A Case Report. Indian J Urol. 2014 January;30:S143. PMID: 71491336; X-1

3596. Sugano H, Nakanishi H, Nakajima M, et al. Posterior quadrant disconnection surgery for Sturge-Weber syndrome. Epilepsia. 2014 May;55(5):683-9. PMID: 24621276; X-1

3597. Sun J, Karmazyn B, Lin J, et al. Newborn with an underrecognized triad: skin lesion, abdominal distention, and hypothyroidism. J Pediatr. 2014 Feb;164(2):419-20. PMID: 24183208; X-2

3598. Verma SB, Wollina U. Infantile perianal pyramidal protrusion with coexisting perineal and perianal hemangiomas: A fortuitous association or incomplete PELVIS syndrome? Indian J Dermatol. 2014 January-February;59(1):71-4. PMID: 2014027276; X-1, X-2

3599. von der Brelie C, Kuczaty S, von Lehe M. Surgical management and long-term outcome of pediatric patients with different subtypes of epilepsy associated with cerebral cavernous malformations. J Neurosurg Pediatr. 2014 Jun;13(6):699-705. PMID: 24702617; X-1

3600. Zhu Y, Tuerxun A, Hui Y, et al. Effects of propranolol and isoproterenol on infantile hemangioma endothelial cells in vitro. Exp Ther Med. 2014 August;8(2):647-51. PMID: 2014416670; XAppendix D. Methods for Meta-Analysis

Appendix D. Methods for Meta-Analysis

Using data extracted by the systematic review, we conducted a multi-intervention meta-analysis to estimate the effectiveness of several corticosteroids and beta blockers for the treatment of infantile hemangioma. Of particular interest was the estimation of the efficacy of propranolol, a beta blocker that was used in a large number of studies in the review. To this end, we estimated the expected clearance of IH following intervention based on outcomes from 17 unique studies obtained from the systematic review. This set included outcomes for 4 different non-control pharmacologic interventions: propranolol, timolol, triamcinolone, and oral steroids.

A challenge for meta-analyzing these outcomes is the diversity in outcome reporting among the constituent studies. Though most used some measure of the reduction in the original IH at end of treatment, typically results were reported as counts of subjects achieving some arbitrary minimum clearance threshold, such as 50% or 75%. An approach to analyzing outcomes reported in this way is via a binomial model. For this model, the response variable is the number of individuals in study *j* under intervention *k* that achieve the clearance threshold:

$$y_{jk} = \sum_{i=1}^{n_{jk}} I_i(above\ clearance\ threshold)$$

where *I* is the indicator function, returning 1 if the argument is true, or 0 otherwise. This outcome can then modeled as a binomial response:

$$y_{jk} \sim Bin(n_{jk}, \pi_{jk})$$

where π_{jk} is the probability of a positive response for study *j* under intervention *k*. To allow for heterogeneity in this probability across studies, we can specify it as a random effect:

$$logit(\pi_{jk}) = \theta_{jk}$$
$$\theta_{jk} \sim Normal(\mu_k, \sigma_k)$$

where μ_k, σ_k are the parameters of a normal distribution (which, inverse logit-transformed, models quantities on the [0,1] interval).

However, the use of an arbitrary cutoff value as a threshold of success is an unsatisfactory modeling choice because there is an inherent loss of information in the dichotomization or discretization of continuous variables, and this loss is magnified here by having to discard data from studies that use a different response threshold than the adopted value (e.g. 75%). Since the clearance rate is a continuous measure, one can hypothesize a latent, continuous probability distribution that each study reports relative to specific quantiles: 50%, 75%, etc. If there is sufficient information, one may use a Bayesian approach to attempt to reconstruct this latent distribution, which would allow for more of the available information to be used in the meta-analytic procedure.

Under treatment *k*, one can consider a notional distribution of hemangioma clearance rates, from no effect (0) to complete clearance (1)—for our purposes, we will not consider IH enlargement, other than assigning it a "no effect" outcome. As a matter of convenience in a particular study *j*, researchers chose a clearance threshold c_j, only reporting whether a particular subject occupied one side or the other of this threshold. We can characterize the true, latent response distribution by estimating the parameters via the following identity:

$$\pi_{jk} = 1 - \Phi(c_j | \mu_k, \sigma_k)$$

where $\Phi(x)$ is the cumulative distribution function of the normal distribution under parameters evaluated at x. The resulting probability is the same as specified above, and can be used in the same binomial likelihood:

$$y_{jk} \sim Bin(n_{jk}, \pi_{jk})$$

This can be readily generalized to studies that report multiple thresholds, simply by dividing the distribution of π_{jk} into regions corresponding to each threshold. This corresponds to a multinomial, rather than binomial, likelihood.

In principle, one may incorporate covariates to improve the prediction of intervention effectiveness. For example, the mode of delivery (oral, intralesional, topical), dose, or the hemangioma location may be predictive of intervention effectiveness. In this work, only propanolol had a sufficient number of studies to estimate covariate effects; we included an indicator variable for intralesional mode of delivery, relative to the oral mode that was used as a baseline. The logit-expected value of treatment k from study j was modeled as:

$$\theta_{jk} = \mu + \beta_k + \psi z_j + \epsilon_j$$

where μ is the baseline (control) clearance rate, β_k is the relative effect of treatment k, z_j is an indicator for the use of intralesional propranolol, and ψ the associated relative intralesional effect. Finally, ϵ_j is a study random effect that is assigned to all treatment arms of study j, which accounts for the lack of independence within-study. This random effect was assumed to be normally distributed with zero mean and variance σ^2 that was estimated from the data.

A handful of studies, rather than reporting threshold counts, reported summary statistics of VAS scores for each study arm. Using the latent variable framework described above under a Bayesian estimation approach, this information can also be brought to bear on the estimation of the model parameters. This required the transformation of the reported outcomes from the VAS scale (0-100) to values on the real line (*i.e.* a logit transformation), including the reported standard deviation, which was transformed using the delta method. The resulting transformed values can then be used to inform the expected outcome for the corresponding intervention via a normal likelihood:

$$logit(VAS_{jk}) \sim N(\theta_k, s_{jk}^{\delta})$$

where s_j^{δ} is the transformed standard deviation for the outcome.

Finally, one study (Qiu 2013) reported individual patient data in the form of VAS scores. This data was integrated into the study via the same method as for the summarized VAS score output outlined above, except that the delta transformation was not necessary, since the data were used directly.

This model was implemented in the PyMC package for Bayesian analysis in Python (Patil et al. 2010). Parameter estimates were obtained using Markov chain Monte Carlo (MCMC, Brooks et al. 2011) methods. Sampling was carried out for 200,000 iterations, with the first 190,000 conservatively discarded as burn-in to ensure convergence of the sampler.

Model Results

The expected efficacy of control arms was estimated to be 0.01 (95% Bayesian credible interval = [0.00, 0.05]). All non-control treatments were estimated to have a larger expected clearance than control (Figure 1). The largest mean estimate was oral propranolol (0.95, 95% BCI = [0.86, 1.00]), followed by timolol (0.64, 95% BCI = [0.31, 0.90]) and triamcinolone (0.53, 95% BCI = [0.14, 0.97]). Oral steroids had a mean clearance estimate of 0.29 (95% BCI = [0.09, 0.50]).

We calculated the probability that each of the non-control interventions is the best treatment, based on expected clearance rate. This was estimated from the MCMC simulation that tallied the number of iterations that each intervention had the highest expected value, and calculating the proportion for each intervention as an estimate of the probability of being best. Oral propranolol had the highest probability (98%), followed by triamcinolone (2%); all others had probabilities less than 1% combined.

Propanolol was estimated to have the largest variability in clearance rate (Figure 2, σ=2.6, 95% BCI = [2.2, 2.9]) though triamcinolone obtained a very similar estimate (σ=2.3, 95% BCI = [1.8, 2.9]). Oral steroids were estimated to be the least variable (σ=1.3, 95% BCI = [1.1, 1.6]), followed by timilol (σ=1.5, 95% BCI = [1.4, 1.6]).

Table D-1. Posterior estimates of effect size

	Mean	SE	95% Credible interval
Oral propranolol	7.1	0.8	[5.6 8.4]
Timolol	4.5	0.6	[3.0 5.6]
Triamcinolone	4.0	1.2	[1.3 6.4]
Oral steroid	2.9	0.4	[2.1 3.9]

Note: Posterior estimates of effect size, on logit scale, relative to control, along with standard error and 95% credible interval. Positive values indicate increased clearance relative to control, negative indicate decreased clearance.

Figure D-1. Estimates of expected IH clearance

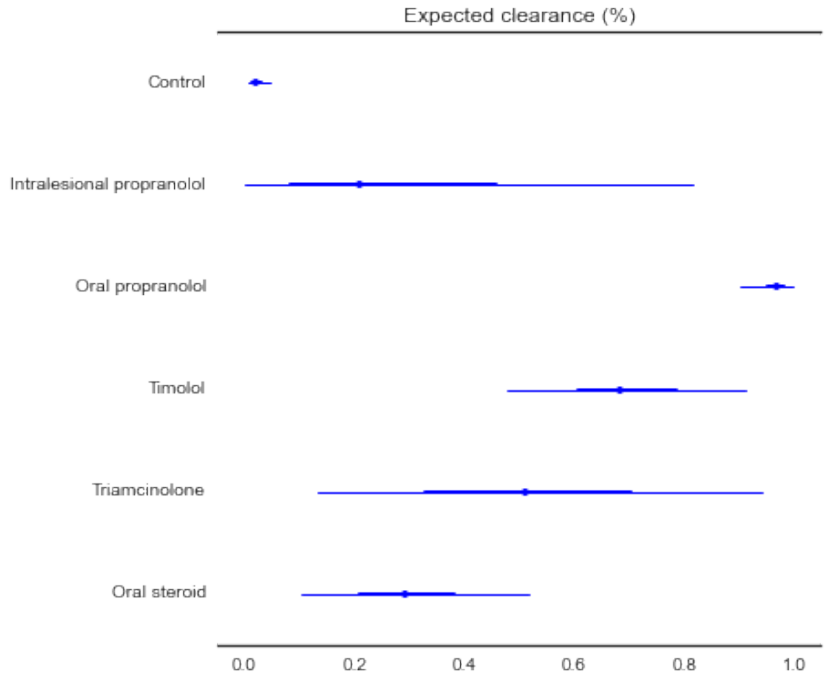

Note: Estimates of expected IH clearance (expressed as percent clearance relative to initial condition) for each treatment, along with associated posterior interquartile range (thick lines) and 95% credible interval (thin lines).

Figure D-2. Estimates of the variation of each treatment

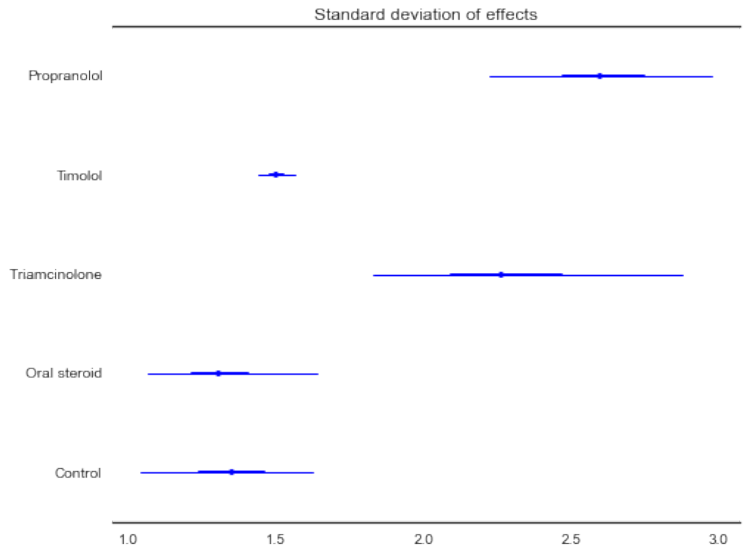

Note: Estimates of the variation of each treatment, expressed as standard deviation, along with associated posterior interquartile range (thick lines) and 95% credible interval (thin lines).

References

1. Patil A, Huard D, Fonnesbeck CJ. PyMC: Bayesian Stochastic Modelling in Python. *J Stat Softw*. 2010;35(4):1-81.
2. Brooks S, Gelman A, Jones G, Meng X-L. *Handbook of Markov Chain Monte Carlo*. CRC Press; 2011.

Appendix E. Study Design Classification Algorithm

Figure E-1. Study design algorithm

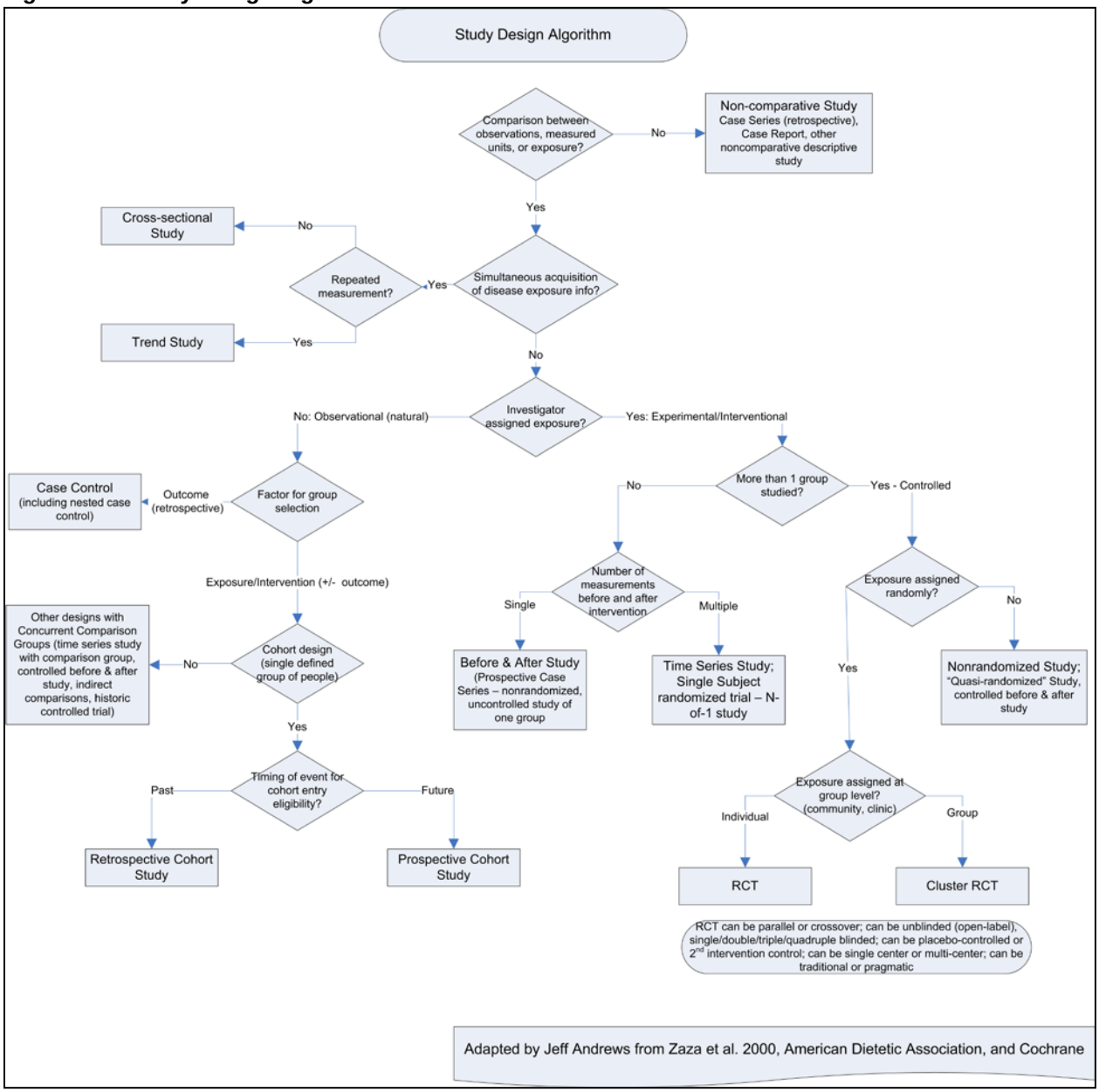

Appendix F. Quality/Risk of Bias Ratings

Table F-1. Quality assessment of randomized controlled trials

Author, Year	Allocation Sequence Generated Adequately	Allocation Treatment Adequately Concealed	Participants Analyzed In Groups Originally Assigned	Design Account for Confounding	Rule Out Impact from Concurrent Intervention or Unintended Exposure	Fidelity Maintained to Intervention Protocol	If Attrition, Were Missing Data Handled Appropriately	Difference in Length of Follow-up Between Groups	Outcome Assessors Blinded	Interventions/ Exposures Assessed Clearly	Outcomes Assessed Clearly	Potential Outcomes Prespecified	All Prespecified Outcomes Reported	Risk of Bias Rating for Outcome
Leaute-Labreze 2015[1]	Yes	Yes	Yes	Yes	Yes	Yes	Yes	No	Yes	Yes	Yes	Yes	Yes	GOOD
Abarzua-Araya 2014[2]	Unclear	Unclear	Yes	No	No	Unclear	Yes	No	Yes	Yes	Yes	Yes	Yes	FAIR
Bauman 2014[3]	Yes	Yes	Yes	Yes	Yes	Yes	Unclear	No	Yes	Yes	Yes	Yes	Yes	GOOD
Chan 2013[4]	Yes	Yes	Yes	Yes	Unclear	Yes	Yes	No	Yes	Yes	Yes	Yes	Yes	GOOD
Kessels 2013[5]	Yes	Yes	Yes	Yes	Yes	Yes	Yes	No	Yes	Yes	No	Yes	Yes	GOOD
Zaher 2013[6]	Unclear	Unclear	yes	No	Yes	Yes	Yes	Unclear	Unclear	Yes	Yes	Yes	Yes	FAIR
Hogeling 2011[7]	Yes	Yes	Yes	Yes	No	Yes	Yes	No	Yes	Yes	Unclear	Yes	Yes	GOOD
Pandey 2010[8]	Unclear	Unclear	Yes	Yes	Unclear	Unclear	Yes	No	Unclear	Yes	Yes	Yes	Yes	FAIR
Pope 2007[9]	Yes	Yes	Yes	Yes	Unclear	No	Yes	No	Yes	Yes	Yes	Yes	Yes	GOOD

Author, Year	Allocation Sequence Generated Adequately	Allocation Treatment Adequately Concealed	Participants Analyzed In Groups Originally Assigned	Design Account for Confounding	Rule Out Impact from Concurrent Intervention or Unintended Exposure	Fidelity Maintained to Intervention Protocol	If Attrition, Were Missing Data Handled Appropriately	Difference in Length of Follow-up Between Groups	Outcome Assessors Blinded	Interventions/ Exposures Assessed Clearly	Outcomes Assessed Clearly	Potential Outcomes Prespecified	All Prespecified Outcomes Reported	Risk of Bias Rating for Outcome
Jalil 2006[10]	Unclear	No	Yes	Unclear	Unclear	Unclear	Yes	No	Unclear	Yes	Yes	Yes	Yes	POOR
Kono 2006[11]	Unclear	Unclear	Yes	Yes	Yes	Unclear	Yes	No	Yes	Yes	No	Yes	Yes	FAIR
Batta 2002[12]	Yes	Yes	Yes	Yes	Unclear	No	Yes	No	No	Yes	Yes	Yes	Yes	FAIR

Table F-2. Quality assessment of cohort studies

Author, Year	Representative-ness of exposed cohort	Selection of non-exposed cohort	Ascertainment of exposure	Outcome of interest not present at start of study	Comparability of cohorts	Assessment of outcome	Follow-up long enough	Adequacy of follow-up of cohorts	Quality Rating
Perkins 2014[13]	Truly representative	Drawn from same community	Secure record	Yes	Controls for age	Record linkage	Yes	Complete follow-up	Fair
de Graaf 2013[14, #3503, #486]	Somewhat representative	Drawn from same community	Secure record	Yes	Controls for age	Independent blind assessment	Yes	Complete follow-up	Fair
Qiu 2013[15]	Truly representative	Drawn from same community	Secure record	Yes	Controls for other factors	Record linkage	Yes	Complete follow-up	Fair
Reddy 2013[16]	Somewhat representative	Drawn from same community	Secure record	Yes	Controls for other factors	Independent blind assessment	Yes	Complete follow-up	Fair
Sondhi 2013[17]	Truly representative	Drawn from same community	Secure record	Yes	Cohorts not comparable	Independent blind assessment	Yes	Subjects lost to follow up unlikely to introduce bias	Fair
Yu 2013[18]	Truly representative	Drawn from same community	No description	Yes	Controls for age	No description	Yes	Complete follow-up	Poor
Chambers 2012[19]	Somewhat representative	Drawn from same community	Secure record	Yes	Controls for age	Independent blind assessment	Yes	Complete follow-up	Fair
Pope 2012[20]	Truly representative	Drawn from same community	Secure record	Yes	Controls for other factors	Independent blind assessment	No	No statement	Poor
Tay 2012[21]	Truly representative	Drawn from same community	Secure record	Yes	Controls for age	Record linkage	Yes	Complete follow-up	Fair
Thayal 2012[22]	Somewhat representative	No description of derivation of non-exposed cohort	Secure record	Yes	Cohorts not comparable	Record linkage	Yes	Subjects lost to follow up unlikely to introduce bias	Poor
Awadein 2011[23]	Truly representative	Drawn from same	Structured interview	Yes	Controls for age	Independent blind	No	Complete follow-up	Fair

Author, Year	Representative-ness of exposed cohort	Selection of non-exposed cohort	Ascertainment of exposure	Outcome of interest not present at start of study	Comparability of cohorts	Assessment of outcome	Follow-up long enough	Adequacy of follow-up of cohorts	Quality Rating
		community				assessment			
Bertrand 2011[24]	Truly representative	Drawn from same community	Secure record	Yes	Controls for age	Independent blind assessment	Yes	Complete follow-up	Fair
Hermans 2011[25]	Truly representative	Drawn from same community	Secure record	Yes	Controls for other factors	Record linkage	Yes	Complete follow-up	Fair
Price 2011[26]	Somewhat representative	Drawn from same community	Secure record	Yes	Controls for other factors	Record linkage	Yes	Complete follow-up	Fair
Nicolai 2005[27]	Truly representative	Drawn from same community	Secure record	Yes	Cohorts not comparable	Self report	Yes	Subjects lost to follow up unlikely to introduce bias	Poor
Vlachakis 2004[28]	Truly representative	Drawn from same community	Secure record	Yes	Cohorts not comparable	Record linkage	Yes	Complete follow-up	Fair
Akyuz 2001[29]	Truly representative	Drawn from same community	Secure record	Yes	Controls for age	Record linkage	Yes	Complete follow-up	Fair
Chang 2001[30]	No description of the derivation of cohort	Drawn from same community	Secure record	Yes	Cohorts not comparable	Independent blind assessment	Yes	Complete follow-up	Poor
Raulin 2001[31]	No description of the derivation of cohort	Drawn from same community	Secure record	Yes	Cohorts not comparable	Record linkage	Yes	Subjects lost to follow up unlikely to introduce bias	Poor
Achauer 1997[32]	Truly representative	Drawn from same community	Secure record	Yes	Cohorts not comparable	Record linkage	No	Complete follow-up	Poor
Achauer 1989[33]	Selected group	Drawn from same community	Secure record	Yes	Cohorts not comparable	Record linkage	Yes	Subjects lost to follow up unlikely to introduce bias	Poor

Table F-3. Quality assessment of studies reporting harms

Author, Year	Were the harms predefined using standardized or precise definitions?	Were all pre-specified harms reported?	Did the author(s) use STANDARD scale(s) or checklist(s) for harms collection?	Were the statistical methods used to assess the main harm or adverse event outcomes adequate?	Rating
Leaute-Labreze 2015[1]	Yes	Yes	Yes	Yes	GOOD
Abarzua-Araya 2014[2]	partial	unclear	partial	yes	POOR
Bauman 2014[3]	yes	yes	Yes	Yes	GOOD
Hassan 2014[34]	Partial	Unclear	Partial	Yes	POOR
Jian 2014[35]	Partial	Unclear	No	Yes	POOR
Kwon 2014[36]	Yes	Yes	Yes	Yes	GOOD
Park 2014[37]	Partial	Unclear	Partial	Yes	POOR
Szychta 2014[38]	No	Unclear	Unclear	Yes	POOR
Bonifazi 2013[39]	No	Unclear	Unclear	Yes	POOR
Chan 2013[4]	Yes	Yes	Yes	Yes	GOOD
de Graaf 2013[14, #3503, #486]	Unclear	Unclear	Unclear	Yes	POOR
Gan 2013[40]	Partial	Unclear	Partial	No	POOR
Hermans 2013[41]	Partial	Unclear	Partial	Yes	POOR

Author, Year	Were the harms predefined using standardized or precise definitions?	Were all pre-specified harms reported?	Did the author(s) use STANDARD scale(s) or checklist(s) for harms collection?	Were the statistical methods used to assess the main harm or adverse event outcomes adequate?	Rating
Hong 2013[42]	Partial	Unclear	Partial	Yes	POOR
Kessels 2013[5]	No	Unclear	Unclear	Yes	POOR
Liu 2013[43]	Partial	Unclear	Partial	Yes	POOR
Ma 2013[44]	Yes	Yes	Yes	Yes	GOOD
Puttgen 2013[45]	Yes	Yes	Yes	Yes	GOOD
Qiu 2013[15]	Yes	Yes	Yes	Yes	GOOD
Reddy 2013[16]	No	Unclear	Unclear	Yes	POOR
Sadykov 2013[46, #541]	Partial	Unclear	Partial	Yes	POOR
Semkova 2013[47]	No	Unclear	No	Yes	POOR
Sondhi 2013[17]	Partial	Unclear	Partial	Yes	POOR
Vercellino 2013[48]	Unclear	Unclear	Unclear	Yes	POOR
Xiao 2013[49]	Partial	Unclear	Partial	Yes	POOR
Yu 2013[18]	Unclear	Unclear	Unclear	Yes	POOR
Yuan 2013[50]	Unclear	Unclear	Unclear	Yes	POOR

Author, Year	Were the harms predefined using standardized or precise definitions?	Were all pre-specified harms reported?	Did the author(s) use STANDARD scale(s) or checklist(s) for harms collection?	Were the statistical methods used to assess the main harm or adverse event outcomes adequate?	Rating
Zaher 2013[6]	Partial	Unclear	Partial	Yes	POOR
Balma-Mena 2012[51]	No	Unclear	Unclear	Yes	POOR
Bertrand 2012[52]	No	Unclear	Unclear	Yes	POOR
Celik 2012[53]	Partial	Unclear	Partial	Yes	POOR
Chakkittakandiyil 2012[54]	No	Unclear	Unclear	Yes	POOR
Chambers 2012[19]	No	Unclear	Unclear	Yes	POOR
Georgountzou 2012[55]	Partial	Unclear	Partial	Yes	POOR
Janmohamed 2012[56]	No	Unclear	Unclear	Yes	POOR
Kunzi-Rapp 2012[57]	Partial	Unclear	Partial	Yes	POOR
Lv 2012[58]	Partial	Unclear	Partial	Yes	POOR
Phillips 2012[59]	No	Unclear	No	Yes	POOR
Pope 2012[20]	Unclear	Unclear	Unclear	Yes	POOR
Talaat 2012[60]	Partial	Unclear	Partial	Yes	POOR
Tay 2012[21]	No	Unclear	Unclear	Yes	POOR

Author, Year	Were the harms predefined using standardized or precise definitions?	Were all pre-specified harms reported?	Did the author(s) use STANDARD scale(s) or checklist(s) for harms collection?	Were the statistical methods used to assess the main harm or adverse event outcomes adequate?	Rating
Thayal 2012[22]	Partial	Unclear	Partial	Unclear	POOR
Xu 2012[61]	Yes	Yes	Yes	Yes	GOOD
Zegpi-Trueba 2012[62]	Unclear	Unclear	Unclear	Yes	POOR
Awadein 2011[23]	No	Unclear	Unclear	Yes	POOR
Bertrand 2011[24]	No	Unclear	Unclear	Yes	POOR
Blatt 2011[63]	No	Unclear	Unclear	Yes	POOR
Chang 2011[64]	Unclear	Unclear	Unclear	Yes	POOR
Cushing 2011[65]	Yes	Yes	Yes	Unclear	FAIR
Daramola 2011[66]	No	Unclear	Unclear	Yes	POOR
Di Maio 2011[67]	Yes	Yes	Yes	No	FAIR
Fuchsmann 2011[68]	Yes	Yes	Yes	Yes	GOOD
Greene 2011[69]	No	Unclear	Unclear	Yes	POOR
Hermans 2011[25]	No	Unclear	Unclear	Yes	POOR
Hogeling 2011[7]	Partial	Unclear	Partial	Yes	POOR

Author, Year	Were the harms predefined using standardized or precise definitions?	Were all pre-specified harms reported?	Did the author(s) use STANDARD scale(s) or checklist(s) for harms collection?	Were the statistical methods used to assess the main harm or adverse event outcomes adequate?	Rating
Holmes 2011[70]	Partial	Unclear	Partial	Yes	POOR
Kulbersh 2011[71]	No	Unclear	Unclear	Yes	POOR
Li 2011[72]	No	Unclear	Unclear	Yes	POOR
Price 2011[26]	No	Unclear	Unclear	Yes	POOR
Saint-Jean 2011[73]	Partial	Unclear	Partial	Yes	POOR
Schiestl 2011[74]	Partial	Unclear	Partial	Yes	POOR
Schupp 2011[75]	Partial	Unclear	Partial	Yes	POOR
Snir 2011[76]	Partial	Unclear	Partial	Yes	POOR
Zaher 2011[77]	Partial	Unclear	Partial	Unclear	POOR
Zvulunov 2011[78]	No	Unclear	No	Yes	POOR
Arneja 2010[79]	No	Unclear	No	Yes	POOR
Hamou 2010[80]	No	Unclear	No	Yes	POOR
Li 2010[81]	No	Unclear	Unclear	No	POOR
Pandey 2010[8]	No	Unclear	Unclear	Yes	POOR

Author, Year	Were the harms predefined using standardized or precise definitions?	Were all pre-specified harms reported?	Did the author(s) use STANDARD scale(s) or checklist(s) for harms collection?	Were the statistical methods used to assess the main harm or adverse event outcomes adequate?	Rating
Chen 2009[82]	No	Unclear	Unclear	Yes	POOR
Pandey 2009[83]	No	Unclear	Unclear	Yes	POOR
Rizzo 2009[84]	No	Unclear	No	Yes	POOR
Sans 2009[85]	Partial	Unclear	Partial	Yes	POOR
Wu 2009[86]	No	Unclear	No	Yes	POOR
Chantharatanapiboon 2008[87]	No	Unclear	Unclear	Yes	POOR
Chen 2008[88]	No	Unclear	Unclear	Yes	POOR
Claude 2008[89]	No	Unclear	Unclear	Yes	POOR
Rossler 2008[90]	Partial	Unclear	Partial	Yes	POOR
Baraldini 2007[91]	No	Unclear	Unclear	Yes	POOR
Pope 2007[9]	Yes	Yes	Yes	Yes	GOOD
Jalil 2006[10]	Yes	Yes	Yes	Yes	GOOD
Kono 2006[11]	Unclear	Unclear	Unclear	Yes	POOR
McHeik 2005[92]	No	Unclear	No	Yes	POOR

Author, Year	Were the harms predefined using standardized or precise definitions?	Were all pre-specified harms reported?	Did the author(s) use STANDARD scale(s) or checklist(s) for harms collection?	Were the statistical methods used to assess the main harm or adverse event outcomes adequate?	Rating
Nicolai 2005[27]	No	Unclear	Unclear	Yes	POOR
Waldschmidt 2005[93]	No	Unclear	Unclear	Yes	POOR
Vlachakis 2004[28]	No	Unclear	Unclear	Unclear	POOR
David 2003[94]	No	Unclear	Unclear	Unclear	POOR
Vlachakis 2003[95]	No	Unclear	No	Yes	POOR
Batta 2002[12]	Yes	Yes	Yes	Yes	GOOD
Akyuz 2001[29]	No	Unclear	Unclear	Unclear	POOR
Chang 2001[30]	No	Unclear	Unclear	Unclear	POOR
Demiri 2001[96]	No	Unclear	Unclear	Yes	POOR
Raulin 2001[31]	Yes	Yes	Yes	Yes	GOOD
Chen 2000[97]	No	Unclear	No	Yes	POOR
Poetke 2000[98]	No	Unclear	Unclear	Yes	POOR
Boon 1999[99]	No	Unclear	Unclear	Yes	POOR
Achauer 1997[32]	No	Unclear	Unclear	Yes	POOR

Author, Year	Were the harms predefined using standardized or precise definitions?	Were all pre-specified harms reported?	Did the author(s) use STANDARD scale(s) or checklist(s) for harms collection?	Were the statistical methods used to assess the main harm or adverse event outcomes adequate?	Rating
Zide 1997[100]	No	Unclear	Unclear	Yes	POOR
Gangopadhyay 1996[101]	No	Unclear	Unclear	Yes	POOR
Sadan 1996[102]	No	Unclear	Unclear	Yes	POOR
Chang 1995[103]	No	Unclear	Unclear	Yes	POOR
Chowdri 1994[104]	No	Unclear	No	Yes	POOR
Morelli 1994[105]	No	Unclear	Unclear	Yes	POOR
Preeyanont 1994[106]	No	Unclear	No	No	POOR
Morrell 1991[107]	No	Unclear	No	Yes	POOR
Achauer 1989[33]	Yes	Yes	Yes	Yes	GOOD
Sloan 1989[108]	No	Unclear	No	Yes	POOR
Kushner 1985[109]	No	Unclear	No	No	POOR
Healy 1984[110]	No	Unclear	No	Yes	POOR
Sharma 1983[111]	No	Unclear	Unclear	Yes	POOR

References

1. Léauté-Labrèze C, Hoeger P, Mazereeuw-Hautier J, et al. A Randomized, Controlled Trial of Oral Propranolol in Infantile Hemangioma. New England Journal of Medicine 2015;372(8):735-46. PMID: 25693013.
2. Abarzua-Araya A, Navarrete-Dechent CP, Heusser F, et al. Atenolol versus propranolol for the treatment of infantile hemangiomas: a randomized controlled study. J Am Acad Dermatol 2014 Jun;70(6):1045-9. PMID: 24656727.
3. Bauman NM, McCarter RJ, Guzzetta PC, et al. Propranolol vs prednisolone for symptomatic proliferating infantile hemangiomas: a randomized clinical trial. JAMA Otolaryngol Head Neck Surg 2014 Apr;140(4):323-30. PMID: 24526257.
4. Chan H, McKay C, Adams S, et al. RCT of timolol maleate gel for superficial infantile hemangiomas in 5- to 24-week-olds. Pediatrics 2013 Jun;131(6):e1739-47. PMID: 23650294.
5. Kessels JP, Hamers ET, Ostertag JU. Superficial hemangioma: pulsed dye laser versus wait-and-see. Dermatol Surg 2013 Mar;39(3 Pt 1):414-21. PMID: 23279058.
6. Zaher H, Rasheed H, Esmat S, et al. Propranolol and infantile hemangiomas: different routes of administration, a randomized clinical trial. Eur J Dermatol 2013 Sep-Oct;23(5):646-52. PMID: 24135427.
7. Hogeling M, Adams S, Wargon O. A randomized controlled trial of propranolol for infantile hemangiomas. Pediatrics 2011 Aug;128(2):e259-66. PMID: 21788220.
8. Pandey A, Gangopadhyay AN, Sharma SP, et al. Evaluation of topical steroids in the treatment of superficial hemangioma. Skinmed 2010 Jan-Feb;8(1):9-11. PMID: 20839418.
9. Pope E, Krafchik BR, Macarthur C, et al. Oral versus high-dose pulse corticosteroids for problematic infantile hemangiomas: a randomized, controlled trial. Pediatrics 2007 Jun;119(6):e1239-47. PMID: 17485449.
10. Jalil S, Akhtar J, Ahmed S. Corticosteroids therapy in the management of infantile cutaneous hemangiomas. J Coll Physicians Surg Pak 2006 Oct;16(10):662-5. PMID: 17007757.
11. Kono T, Sakurai H, Groff WF, et al. Comparison study of a traditional pulsed dye laser versus a long-pulsed dye laser in the treatment of early childhood hemangiomas. Lasers Surg Med 2006 Feb;38(2):112-5. PMID: 16374781.
12. Batta K, Goodyear HM, Moss C, et al. Randomised controlled study of early pulsed dye laser treatment of uncomplicated childhood haemangiomas: results of a 1-year analysis. Lancet 2002 Aug 17;360(9332):521-7. PMID: 12241656.
13. Perkins JA, Chen BS, Saltzman B, et al. Propranolol therapy for reducing the number of nasal infantile hemangioma invasive procedures. JAMA Otolaryngol Head Neck Surg 2014 Mar;140(3):220-7. PMID: 24557492.
14. de Graaf M, Raphael MF, Breugem CC, et al. Treatment of infantile haemangiomas with atenolol: comparison with a historical propranolol group. J Plast Reconstr Aesthet Surg 2013 Dec;66(12):1732-40. PMID: 24011909.
15. Qiu Y, Ma G, Yang J, et al. Imiquimod 5% cream versus timolol 0.5% ophthalmic solution for treating superficial proliferating infantile haemangiomas: a retrospective study. Clin Exp Dermatol 2013 Dec;38(8):845-50. PMID: 23627540.
16. Reddy KK, Blei F, Brauer JA, et al. Retrospective study of the treatment of infantile hemangiomas using a combination of propranolol and pulsed dye laser. Dermatol Surg 2013 Jun;39(6):923-33. PMID: 23458381.
17. Sondhi V, Patnaik SK. Propranolol for infantile hemangioma (PINCH): an open-label trial to assess the efficacy of propranolol for treating infantile hemangiomas and for determining the decline in heart rate to predict response to propranolol. J Pediatr Hematol Oncol 2013 Oct;35(7):493-9. PMID: 23929318.
18. Yu L, Li S, Su B, et al. Treatment of superficial infantile hemangiomas with timolol: Evaluation of short-term efficacy and safety in infants. Exp Ther Med 2013 August;6(2):388-90. PMID: 2013417689.

19. Chambers CB, Katowitz WR, Katowitz JA, et al. A controlled study of topical 0.25% timolol maleate gel for the treatment of cutaneous infantile capillary hemangiomas. Ophthal Plast Reconstr Surg 2012 Mar-Apr;28(2):103-6. PMID: 22410658.

20. Pope E, Chakkittakandiyil A, Lara-Corrales I, et al. Expanding the therapeutic repertoire of infantile haemangiomas: cohort-blinded study of oral nadolol compared with propranolol. Br J Dermatol 2013 Jan;168(1):222-4. PMID: 22762503.

21. Tay YK, Tan SK. Treatment of infantile hemangiomas with the 595-nm pulsed dye laser using different pulse widths in an Asian population. Lasers Surg Med 2012 Feb;44(2):93-6. PMID: 22241650.

22. Thayal PK, Bhandari PS, Sarin YK. Comparison of efficacy of intralesional bleomycin and oral propanolol in management of hemangiomas. Plast Reconstr Surg 2012 Apr;129(4):733e-5e. PMID: 22456397.

23. Awadein A, Fakhry MA. Evaluation of intralesional propranolol for periocular capillary hemangioma. Clin Ophthalmol 2011;5(1):1135-40. PMID: 2011458331.

24. Bertrand J, McCuaig C, Dubois J, et al. Propranolol versus prednisone in the treatment of infantile hemangiomas: a retrospective comparative study. Pediatr Dermatol 2011 Nov-Dec;28(6):649-54. PMID: 21995756.

25. Hermans DJ, van Beynum IM, Schultze Kool LJ, et al. Propranolol, a very promising treatment for ulceration in infantile hemangiomas: a study of 20 cases with matched historical controls. J Am Acad Dermatol 2011 May;64(5):833-8. PMID: 21353329.

26. Price CJ, Lattouf C, Baum B, et al. Propranolol vs corticosteroids for infantile hemangiomas: a multicenter retrospective analysis. Arch Dermatol 2011 Dec;147(12):1371-6. PMID: 21844428.

27. Nicolai T, Fischer-Truestedt C, Reiter K, et al. Subglottic hemangioma: a comparison of CO2 laser, Neodym-Yag laser, and tracheostomy. Pediatr Pulmonol 2005 Mar;39(3):233-7. PMID: 15635618.

28. Vlachakis I, Arbiros I, Velaoras K, et al. Different modes cooling the epidermis with ice during Nd:YAG laser treatment of hemangiomas in children. Med Laser Appl 2004 May;19(1):19-23. PMID: 2004263916.

29. Akyuz C, Yaris N, Kutluk MT, et al. Management of cutaneous hemangiomas: a retrospective analysis of 1109 cases and comparison of conventional dose prednisolone with high-dose methylprednisolone therapy. Pediatr Hematol Oncol 2001 Jan-Feb;18(1):47-55. PMID: 11205840.

30. Chang CJ, Kelly KM, Nelson JS. Cryogen spray cooling and pulsed dye laser treatment of cutaneous hemangiomas. Ann Plast Surg 2001 Jun;46(6):577-83. PMID: 11405354.

31. Raulin C, Greve B. Retrospective clinical comparison of hemangioma treatment by flashlamp-pumped (585 nm) and frequency-doubled Nd:YAG (532 nm) lasers. Lasers Surg Med 2001;28(1):40-3. PMID: 11430441.

32. Achauer BM, Chang CJ, Vander Kam VM. Management of hemangioma of infancy: review of 245 patients. Plast Reconstr Surg 1997 Apr;99(5):1301-8. PMID: 9105356.

33. Achauer BM, Vander Kam VM. Capillary hemangioma (strawberry mark) of infancy: comparison of argon and Nd:YAG laser treatment. Plast Reconstr Surg 1989 Jul;84(1):60-9; discussion 70. PMID: 2734405.

34. Hassan BA, Shreef KS. Propranolol in treatment of huge and complicated infantile hemangiomas in egyptian children. Dermatol Res Pract 2014;2014(541810)PMID: 2014377871.

35. Jian D, Chen X, Babajee K, et al. Adverse effects of propranolol treatment for infantile hemangiomas in China. J Dermatolog Treat 2014 Oct;25(5):388-90. PMID: 23216314.

36. Kwon SH, Choi JW, Byun SY, et al. Effect of early long-pulse pulsed dye laser treatment in infantile hemangiomas. Dermatol Surg 2014 Apr;40(4):405-11. PMID: 24460784.

37. Park YW, Yeom KB, Choi JW, et al. Effect of propranolol on the treatment of infantile hemangiomas: a single tertiary center 3-year experience. J Dermatolog Treat 2014 Oct;25(5):391-5. PMID: 23273264.

38. Szychta P, Stewart K, Anderson W. Treatment of infantile hemangiomas with propranolol: clinical guidelines. Plast Reconstr Surg 2014 Apr;133(4):852-62. PMID: 24352207.

39. Bonifazi E, Milano A, Colonna V. Evaluation of safety and efficacy of a galenic preparation of 1% propranolol in 89 cases of cutaneous infantile hemangioma. European Journal of Pediatric Dermatology 2013 April-June;23(2):93-104. PMID: 2013553280.

40. Gan LQ, Ni SL, Tan Q, et al. A retrospective study of propranolol therapy in 109 infants with infantile hemangioma. Pediatr Dermatol 2013 Mar-Apr;30(2):270-2. PMID: 23252446.

41. Hermans DJ, Bauland CG, Zweegers J, et al. Propranolol in a case series of 174 patients with complicated infantile haemangioma: indications, safety and future directions. Br J Dermatol 2013 Apr;168(4):837-43. PMID: 23278381.

42. Hong P, Tammareddi N, Walvekar R, et al. Successful discontinuation of propranolol for infantile hemangiomas of the head and neck at 12 months of age. Int J Pediatr Otorhinolaryngol 2013 Jul;77(7):1194-7. PMID: 23706952.

43. Liu LS, Sokoloff D, Antaya RJ. Twenty-four-hour hospitalization for patients initiating systemic propranolol therapy for infantile hemangiomas--is it indicated? Pediatr Dermatol 2013 Sep-Oct;30(5):554-60. PMID: 23829941.

44. Ma X, Zhao T, Xiao Y, et al. Preliminary experience on treatment of infantile hemangioma with low-dose propranolol in China. Eur J Pediatr 2013 May;172(5):653-9. PMID: 23340697.

45. Puttgen KB, Summerer B, Schneider J, et al. Cardiovascular and blood glucose parameters in infants during propranolol initiation for treatment of symptomatic infantile hemangiomas. Ann Otol Rhinol Laryngol 2013 Sep;122(9):550-4. PMID: 24224397.

46. Sadykov RR, Podmelle F, Sadykov RA, et al. Use of propranolol for the treatment infantile hemangiomas in the maxillofacial region. Int J Oral Maxillofac Surg 2013 Jul;42(7):863-7. PMID: 23618833.

47. Semkova K, Kazandjieva J. Topical timolol maleate for treatment of infantile haemangiomas: preliminary results of a prospective study. Clin Exp Dermatol 2013 Mar;38(2):143-6. PMID: 22731954.

48. Vercellino N, Romanini MV, Pelegrini M, et al. The use of propranolol for complicated infantile hemangiomas. Int J Dermatol 2013 Sep;52(9):1140-6. PMID: 23829783.

49. Xiao Q, Li Q, Zhang B, et al. Propranolol therapy of infantile hemangiomas: efficacy, adverse effects, and recurrence. Pediatr Surg Int 2013 Jun;29(6):575-81. PMID: 23519547.

50. Yuan WL, Jin ZL, Wei JJ, et al. Propranolol given orally for proliferating infantile haemangiomas: analysis of efficacy and serological changes in vascular endothelial growth factor and endothelial nitric oxide synthase in 35 patients. Br J Oral Maxillofac Surg 2013 Oct;51(7):656-61. PMID: 23291092.

51. Balma-Mena A, Chakkittakandiyil A, Weinstein M, et al. Propranolol in the management of infantile hemangiomas: clinical response and predictors. J Cutan Med Surg 2012 May-Jun;16(3):169-73. PMID: 22713439.

52. Bertrand J, Sammour R, McCuaig C, et al. Propranolol in the treatment of problematic infantile hemangioma: review of 35 consecutive patients from a vascular anomalies clinic. J Cutan Med Surg 2012 Sep-Oct;16(5):317-23. PMID: 22971306.

53. Celik A, Tiryaki S, Musayev A, et al. Propranolol as the first-line therapy for infantile hemangiomas: preliminary results of two centers. J Drugs Dermatol 2012 Jul;11(7):808-11. PMID: 22777220.

54. Chakkittakandiyil A, Phillips R, Frieden IJ, et al. Timolol maleate 0.5% or 0.1% gel-forming solution for infantile hemangiomas: a retrospective, multicenter, cohort study. Pediatr Dermatol 2012 Jan-Feb;29(1):28-31. PMID: 22150436.

55. Georgountzou A, Karavitakis E, Klimentopoulou A, et al. Propranolol treatment for severe infantile hemangiomas: a single-centre 3-year experience. Acta Paediatr 2012 Oct;101(10):e469-74. PMID: 22804809.

56. Janmohamed SR, Madern GC, Nieuwenhuis K, et al. Evaluation of intra-lesional corticosteroids in the treatment of peri-ocular haemangioma of infancy: still an alternative besides propranolol. Pediatr Surg Int 2012 Apr;28(4):393-8. PMID: 22200732.

57. Kunzi-Rapp K. Topical propranolol therapy for infantile hemangiomas. Pediatr Dermatol 2012 Mar-Apr;29(2):154-9. PMID: 22141326.

58. Lv MM, Fan XD, Su LX. Propranolol for problematic head and neck hemangiomas: an analysis of 37 consecutive patients. Int J Pediatr Otorhinolaryngol 2012 Apr;76(4):574-8. PMID: 22326207.

59. Phillips RJ, Penington AJ, Bekhor PS, et al. Use of propranolol for treatment of infantile haemangiomas in an outpatient setting. J Paediatr Child Health 2012 Oct;48(10):902-6. PMID: 22897120.

60. Talaat AA, Elbasiouny MS, Elgendy DS, et al. Propranolol treatment of infantile hemangioma: clinical and radiologic evaluations. J Pediatr Surg 2012 Apr;47(4):707-14. PMID: 22498385.

61. Xu G, Lv R, Zhao Z, et al. Topical propranolol for treatment of superficial infantile hemangiomas. J Am Acad Dermatol 2012 Dec;67(6):1210-3. PMID: 22516113.

62. Zegpi-Trueba MS, Abarzua-Araya A, Silva-Valenzuela S, et al. Oral propranolol for treating infantile hemangiomas: a case series of 57 patients. Actas Dermosifiliogr 2012 Oct;103(8):708-17. PMID: 22853960.

63. Blatt J, Morrell DS, Buck S, et al. beta-blockers for infantile hemangiomas: a single-institution experience. Clin Pediatr (Phila) 2011 Aug;50(8):757-63. PMID: 21525081.

64. Chang CJ. Long term follow-up of intralesional laser photocoagulation (ILP) for hemangioma patients. Laser Therapy 2011;20(4):255-63. PMID: 2012497794.

65. Cushing SL, Boucek RJ, Manning SC, et al. Initial experience with a multidisciplinary strategy for initiation of propranolol therapy for infantile hemangiomas. Otolaryngol Head Neck Surg 2011 Jan;144(1):78-84. PMID: 21493392.

66. Daramola OO, Chun RH, Nash JJ, et al. Surgical treatment of infantile hemangioma in a multidisciplinary vascular anomalies clinic. Int J Pediatr Otorhinolaryngol 2011 Oct;75(10):1271-4. PMID: 21803434.

67. Di Maio L, Baldi A, Dimaio V, et al. Use of flashlamp-pumped pulsed dye laser in the treatment of superficial vascular malformations and ulcerated hemangiomas. In Vivo 2011 Jan-Feb;25(1):117-23. PMID: 21282744.

68. Fuchsmann C, Quintal MC, Giguere C, et al. Propranolol as first-line treatment of head and neck hemangiomas. Arch Otolaryngol Head Neck Surg 2011 May;137(5):471-8. PMID: 21576558.

69. Greene AK, Couto RA. Oral prednisolone for infantile hemangioma: efficacy and safety using a standardized treatment protocol. Plast Reconstr Surg 2011 Sep;128(3):743-52. PMID: 21572374.

70. Holmes WJ, Mishra A, Gorst C, et al. Propranolol as first-line treatment for rapidly proliferating infantile haemangiomas. J Plast Reconstr Aesthet Surg 2011 Apr;64(4):445-51. PMID: 20797926.

71. Kulbersh J, Hochman M. Serial excision of facial hemangiomas. Arch Facial Plast Surg 2011 May-Jun;13(3):199-202. PMID: 21576667.

72. Li WY, Chaudhry O, Reinisch JF. Guide to early surgical management of lip hemangiomas based on our experience of 214 cases. Plast Reconstr Surg 2011 Nov;128(5):1117-24. PMID: 21738083.

73. Saint-Jean M, Leaute-Labreze C, Mazereeuw-Hautier J, et al. Propranolol for treatment of ulcerated infantile hemangiomas. J Am Acad Dermatol 2011 May;64(5):827-32. PMID: 21353332.

74. Schiestl C, Neuhaus K, Zoller S, et al. Efficacy and safety of propranolol as first-line treatment for infantile hemangiomas. Eur J Pediatr 2011 Apr;170(4):493-501. PMID: 20936416.

75. Schupp CJ, Kleber JB, Gunther P, et al. Propranolol therapy in 55 infants with infantile hemangioma: dosage, duration, adverse effects, and outcome. Pediatr Dermatol 2011 Nov-Dec;28(6):640-4. PMID: 21995836.

76. Snir M, Reich U, Siegel R, et al. Refractive and structural changes in infantile periocular capillary haemangioma treated with propranolol. Eye (Lond) 2011 Dec;25(12):1627-34. PMID: 21921959.

77. Zaher H, Rasheed H, Hegazy RA, et al. Oral propranolol: an effective, safe treatment for infantile hemangiomas. Eur J Dermatol 2011 Jul-Aug;21(4):558-63. PMID: 21697036.

78. Zvulunov A, McCuaig C, Frieden IJ, et al. Oral propranolol therapy for infantile hemangiomas beyond the proliferation phase: a multicenter retrospective study. Pediatr Dermatol 2011 Mar-Apr;28(2):94-8. PMID: 21362031.

79. Arneja JS, Mulliken JB. Resection of amblyogenic periocular hemangiomas: indications and outcomes. Plast Reconstr Surg 2010 Jan;125(1):274-81. PMID: 20048618.

80. Hamou C, Diner PA, Dalmonte P, et al. Nasal tip haemangiomas: guidelines for an early surgical approach. J Plast Reconstr Aesthet Surg 2010 Jun;63(6):934-9. PMID: 19540825.

81. Li DN, Gold MH, Sun ZS, et al. Treatment of infantile hemangioma with optimal pulse technology. J Cosmet Laser Ther 2010 Jun;12(3):145-50. PMID: 20482239.

82. Chen WL, Zhang B, Li JS, et al. Liquid nitrogen cryotherapy of lip mucosa hemangiomas under inhalation general anesthesia with sevoflurane in early infancy. Ann Plast Surg 2009 Feb;62(2):154-7. PMID: 19158525.

83. Pandey A, Gangopadhyay AN, Gopal SC, et al. Twenty years' experience of steroids in infantile hemangioma--a developing country's perspective. J Pediatr Surg 2009 Apr;44(4):688-94. PMID: 19361627.

84. Rizzo C, Brightman L, Chapas AM, et al. Outcomes of childhood hemangiomas treated with the pulsed-dye laser with dynamic cooling: a retrospective chart analysis. Dermatol Surg 2009 Dec;35(12):1947-54. PMID: 19889007.

85. Sans V, de la Roque ED, Berge J, et al. Propranolol for severe infantile hemangiomas: follow-up report. Pediatrics 2009 Sep;124(3):e423-31. PMID: 19706583.

86. Wu JK, Rohde CH. Purse-string closure of hemangiomas: early results of a follow-up study. Ann Plast Surg 2009 May;62(5):581-5. PMID: 19387166.

87. Chantharatanapiboon W. Intralesional corticosteroid therapy in hemangiomas: clinical outcome in 160 cases. J Med Assoc Thai 2008 Oct;91 Suppl 3:S90-6. PMID: 19253502.

88. Chen W, Li J, Yang Z, et al. SMAS fold flap and ADM repair of the parotid bed following removal of parotid haemangiomas via pre- and retroauricular incisions to improve cosmetic outcome and prevent Frey's syndrome. J Plast Reconstr Aesthet Surg 2008 Aug;61(8):894-9; discussion 9-900. PMID: 18504166.

89. Claude O, Picard A, O'Sullivan N, et al. Use of ultrasonic dissection in the early surgical management of periorbital haemangiomas. J Plast Reconstr Aesthet Surg 2008 Dec;61(12):1479-85. PMID: 18037085.

90. Rossler J, Wehl G, Niemeyer CM. Evaluating systemic prednisone therapy for proliferating haemangioma in infancy. Eur J Pediatr 2008 Jul;167(7):813-5. PMID: 17676341.

91. Baraldini V, Coletti M, Cigognetti F, et al. Haemostatic squeezing and purse-string sutures: optimising surgical techniques for early excision of critical infantile haemangiomas. J Pediatr Surg 2007 Feb;42(2):381-5. PMID: 17270553.

92. McHeik JN, Renauld V, Duport G, et al. Surgical treatment of haemangioma in infants. Br J Plast Surg 2005 Dec;58(8):1067-72. PMID: 16039624.

93. Waldschmidt J, Giest H, Meyer L. Endoscopic laser application in 56 children with hemangiomas of the larynx and trachea. Med Laser Appl 2005 08 Dec;20(4):297-302. PMID: 2005531370.

94. David LR, Malek MM, Argenta LC. Efficacy of pulse dye laser therapy for the treatment of ulcerated haemangiomas: a review of 78 patients. Br J Plast Surg 2003 Jun;56(4):317-27. PMID: 12873458.

95. Vlachakis I, Gardikis S, Michailoudi E, et al. Treatment of hemangiomas in children using a Nd:YAG laser in conjunction with ice cooling of the epidermis: techniques and results. BMC Pediatr 2003 Apr 12;3:2. PMID: 12697072.

96. Demiri EC, Pelissier P, Genin-Etcheberry T, et al. Treatment of facial haemangiomas: the present status of surgery. Br J Plast Surg 2001 Dec;54(8):665-74. PMID: 11728108.

97. Chen MT, Yeong EK, Horng SY. Intralesional corticosteroid therapy in proliferating head and neck hemangiomas: a review of 155 cases. J Pediatr Surg 2000 Mar;35(3):420-3. PMID: 10726680.

98. Poetke M, Philipp C, Berlien HP. Flashlamp-pumped pulsed dye laser for hemangiomas in infancy: treatment of superficial vs mixed hemangiomas. Arch Dermatol 2000 May;136(5):628-32. PMID: 10815856.

99. Boon LM, MacDonald DM, Mulliken JB. Complications of systemic corticosteroid therapy for problematic hemangioma. Plast Reconstr Surg 1999 Nov;104(6):1616-23. PMID: 10541160.

100. Zide BM, Glat PM, Stile FL, et al. Vascular lip enlargement: Part I. Hemangiomas--tenets of therapy. Plast Reconstr Surg 1997 Dec;100(7):1664-73. PMID: 9393462.

101. Gangopadhyay AN, Sharma SP, Gopal SC, et al. Local steroid therapy in cutaneous hemangiomas. Indian Pediatr 1996 Jan;33(1):31-3. PMID: 8772948.

102. Sadan N, Wolach B. Treatment of hemangiomas of infants with high doses of prednisone. J Pediatr 1996 Jan;128(1):141-6. PMID: 8551406.

103. Chang CJ, Achauer BM, Vander Kam VM. Laser treatment of complicated head and neck hemangiomas in infancy. Changgeng Yi Xue Za Zhi 1996 Jun;19(2):135-41. PMID: 8828255.

104. Chowdri NA, Darzi MA, Fazili Z, et al. Intralesional corticosteroid therapy for childhood cutaneous hemangiomas. Ann Plast Surg 1994 Jul;33(1):46-51. PMID: 7944196.

105. Morelli JG, Tan OT, Yohn JJ, et al. Treatment of ulcerated hemangiomas infancy. Arch Pediatr Adolesc Med 1994 Oct;148(10):1104-5. PMID: 7921107.

106. Preeyanont P, Nimsakul N. The Nd:YAG laser treatment of hemangioma. J Clin Laser Med Surg 1994 Aug;12(4):225-9. PMID: 10147482.

107. Morrell AJ, Willshaw HE. Normalisation of refractive error after steroid injection for adnexal haemangiomas. Br J Ophthalmol 1991 May;75(5):301-5. PMID: 2036349.

108. Sloan GM, Reinisch JF, Nichter LS, et al. Intralesional corticosteroid therapy for infantile hemangiomas. Plast Reconstr Surg 1989 Mar;83(3):459-67. PMID: 2919200.

109. Kushner BJ. The treatment of periorbital infantile hemangioma with intralesional corticosteroid. Plast Reconstr Surg 1985 Oct;76(4):517-26. PMID: 4034770.

110. Healy G, McGill T, Friedman EM. Carbon dioxide laser in subglottic hemangioma. An update. Ann Otol Rhinol Laryngol 1984 Jul-Aug;93(4 Pt 1):370-3. PMID: 6431866.

111. Sharma LK, Dalal SS. Corticosteroid therapy in the treatment of cutaneous hemangioma of infancy and childhood. Indian J Pediatr 1983 Mar-Apr;50(403):153-6. PMID: 6618575.

Appendix G. Applicability

Table G-1. Applicability of studies assessing imaging modalities

Domain	Description of applicability of evidence
Population	Infants with hemangiomas (with mean ages of 30 days and 34 weeks). Fair distribution of male and female patients.
Intervention	Radiologic evaluation of hepatic hemangioma to determine which lesions required intervention and radiologic evaluation of lumbosacral cutaneous hemangiomas to evaluate which were associated with occult spinal dysraphism
Comparators	Comparators included ultrasound, magnetic resonance imaging, computed tomography and angiography. If different modalities were utilized on the same patient, it was sometimes not at the same time point making comparison between methods difficult.
Outcomes	Studies assessed imaging and clinical findings and with need for intervention for hepatic hemangiomas and the second study reviewed incidence of occult spinal dysraphism found in patients with lumbosacral hemangioma
Setting	Studies were conducted in the US, Canada and Spain at tertiary care centers with referral programs for hemangiomas / vascular malformations

Table G-2. Applicability of studies assessing steroids

Domain	Description of applicability of evidence
Population	Infants and children with hemangiomas (ages ranging from less than one to 72 months). Typically more females.
Intervention	Corticosteroids including topical, intralesional, intravenous, and oral forms.
Comparators	Comparators included another steroid or observation.
Outcomes	Studies generally assessed change in lesion size and/or appearance and rebound growth. One study assessed vision outcomes. Comparative studies and case series also reported harms.
Setting	One comparative study was conducted in Canada and the others in Turkey, Pakistan, and India. Applicability may be limited given differences in the systems of care in these lower resource countries. Comparative studies were also published between 2001 and 2010 and may not reflect current standards of care.

Table G-3. Applicability of studies assessing beta-blockers

Domain	Description of applicability of evidence
Population	Studies typically included infants of both sexes ages 1 to 12 months of age (range: 1 month to 9 years of age) with infantile hemangiomas which included superficial, deep, and mixed lesions primarily involving the head and neck and occurring as focal or segmental lesions.
Intervention	Patients were treated with a variety of beta-blockers including propranolol at various doses and administrations (oral, intralesional, or topical), timolol (topical), atenolol (oral), or nadolol (oral) for a variety of treatment durations most commonly up to 6 months duration.
Comparators	Comparators included other formulations of the same beta-blocker, other beta-blockers, untreated historical controls, treated historical controls, and non-beta-blocker comparators (topical imiquimod and intralesional bleomycin).
Outcomes	Studies commonly assessed final response based on size, volume, and/or coloration of IH, resolution of ulceration if present at initiation of therapy, and visual acuity or resolution of ptosis for periocular lesions. Assessments were obtained throughout therapy but final outcome assessments were typically performed following 24 weeks of treatment. Additional assessments for serious harms including bronchial hyperreactivity, hypoglycemia, bradycardia, and hypotension and less severe harms including sleep disturbances, cold extremities, and gastrointestinal complaints were monitored in the majority of studies.
Setting	Studies were conducted in Australia, Canada, Chile, China, Egypt, India, the Netherlands, and the United Sates. One RCT was conducted at 16 centers worldwide.

RCT=randomized controlled trial

Table G-4. Applicability of studies assessing surgical interventions

Domain	Description of applicability of evidence
Population	Studies typically included Caucasian and Asian infants of both sexes with a preponderance of females (age range: 1 week to 43 years of age) with superficial and cutaneous infantile hemangiomas in varied locations. One study reported laser use for subglottic IH.
Intervention	Patients were treated with a variety of lasers including short-pulsed and long-pulsed PDL, Nd:YAG, and argon. Duration of treatment varied from 1 to multiple sessions.
Comparators	Comparators included different pulse length PDL, argon, carbon dioxide, different cooling regimens used in conjunction with the laser treatment, and observation (untreated controls).
Outcomes	Studies commonly assessed response to treatment, based on changes in volume, color, and texture. Assessments for infants in all three RCTs were conducted at age 1 year. Additional assessments for harms included scarring, bleeding, ulceration, purpura, and pigmentation changes. Harms were also reported from case series, including dehiscence and post-operative infections following surgical excision and resection.
Setting	Studies were conducted in the United States, the United Kingdom, the Netherlands, Germany, Greece, Japan and Singapore.

Nd:YAG= neodymium yttrium aluminium garnet;PDL=pulsed dye laser; RCT=randomized controlled trial

Appendix H. Harms Reported in Package Insert Data and Other Sources

Infantile Hemangioma Package Insert and FDA Harms Data

By: Genevieve Lynn Ness, PharmD Completed: March 21, 2015

The harms data provided in this section were gathered from analyzing available gray literature (i.e package inserts and FDA review packages). FDA approval packages were limited to those available on the FDA website that contained a "Medical Review" section of the document. Many of the review packages did not contain pediatric data and therefore the adult data was used. Table 1 includes the relevant indications for pediatric medications referenced in the clinical studies included in this review. Medications that have not been approved as safe and effective in pediatric patients and therefore are only FDA approved in adults are referenced in Table 2. Notable contraindications and warnings/precautions that would be relevant to consider in the pediatric population were included in the tables (drug interactions were not included). As a result, the data provided in this chart is not an all-inclusive list of these package insert sections. For complete data please see the corresponding package insert.

Table H-1: FDA Approved Pediatric Medications Included in Literature Review

Drug	Dosage Form	FDA Approved Indication	Contraindications	Warnings/ Precautions
Hemangeol® (propranolol hydrochloride)[1]	Oral solution	Beta-adrenergic blocker indicated for the treatment of proliferating infantile hemangioma requiring systemic therapy	• Premature infants with corrected age <5 weeks • Infants weighing less than 2 kg • Asthma or history of bronchospasm • Bradycardia (<80 beats per minute), greater than first degree heart block, decompensated heart failure • Blood pressure <50/30 mmHg • Pheochromocytoma	• Hypoglycemia: Administer during or after feeding. Do not use in patients who are not able to feed or are vomiting. • Bradycardia and hypotension • Bronchospasm: Avoid use in patients with asthma or lower respiratory infection. • Increased risk of stroke in PHACE syndrome
Flo-pred® (prednisolone acetate)[2]	Oral suspension	• Allergic Conditions: Control of severe or incapacitating allergic conditions intractable to adequate trials of conventional treatment in	---	• Hypothalamic-pituitary-adrenal (HPA) axis suppression, Cushing's syndrome and hyperglycemia: Monitor patients for these conditions with chronic use. Taper doses gradually for

Orapred ODT (prednisolone sodium phosphate) [3] Rayos® (prednisone)[4]	ODT tablet Delayed release tablet	adults and pediatric populations with: o Atopic dermatitis o Drug hypersensitivity reactions o Seasonal or perennial allergic rhinitis o Serum sickness • Dermatologic Diseases o Bullous dermatitis herpetiformis o Contact dermatitis o Exfoliative erythroderma o Mycosis fungoides o Pemphigus o Severe erythema multiforme (Stevens-Johnson syndrome) • Endocrine Conditions o Congenital adrenal hyperplasia o Hypercalcemia of malignancy o Nonsuppurative thyroiditis o Primary or secondary adrenocortical insufficiency: hydrocortisone or cortisone is the first choice: synthetic analogs may be used in conjunction with mineralocorticoids where applicable • Gastrointestinal Diseases: During acute episodes in: o Crohn's Disease o Ulcerative colitis • Hematologic Diseases o Acquired (autoimmune) hemolytic anemia o Diamond-Blackfan anemia o Pure red cell aplasia • Neoplastic Conditions: o Acute leukemia o Aggressive lymphomas • Nervous System Conditions o Acute exacerbations of multiple sclerosis o Cerebral edema associated with		withdrawal after chronic use. • Infections: Increased susceptibility to new infection and increased risk of exacerbation, dissemination, or reactivation of latent infection. Signs and symptoms of infection may be masked • Elevated blood pressure, salt and water retention and hypokalemia: Monitor blood pressure and sodium, potassium serum levels • GI perforation: increased risk in patients with certain GI disorders. Signs and symptoms may be masked • Behavioral and mood disturbances: May Include euphoria, insomnia, mood swings, personality changes, severe depression, and psychosis. Existing conditions may be aggravated. • Decreases in bone density: Monitor bone density in patients receiving long-term corticosteroid therapy. • Ophthalmic effects: May include cataracts, infections and glaucoma. Monitor intraocular pressure if corticosteroid therapy is continued for more than 6 weeks. • Live or live attenuated vaccines: Do not administer to patients receiving immunosuppressive doses of corticosteroids. • Negative effects on growth and development: Monitor pediatric patients on long-term corticosteroid therapy. • Kaposi's sarcoma has been reported to occur in patients receiving corticosteroid therapy, most often for chronic conditions. Discontinuation of corticosteroids may result in clinical improvement. • Although controlled clinical trials have shown corticosteroids to be effective in speeding the resolution of acute exacerbations of multiple sclerosis, they do not show that corticosteroids affect the ultimate outcome or natural history of the disease. The studies do show that relatively high doses of corticosteroids are necessary to demonstrate a significant effect. • An acute myopathy has been observed with the use of high doses of corticosteroids, most often occurring in patients with disorders of neuromuscular transmission (e.g., myasthenia

		primary or metastatic brain tumor, craniotomy or head injury • Ophthalmic Conditions o Sympathetic ophthalmia o Uveitis and ocular inflammatory conditions unresponsive to topical steroids • Conditions Related to Organ Transplantation o Acute or chronic solid organ rejection • Pulmonary Diseases o Allergic bronchopulmonary aspergillosis o Aspiration pneumonitis o Asthma o Fulminating or disseminated pulmonary tuberculosis when used concurrently with appropriate chemotherapy o Hypersensitivity pneumonitis o Idiopathic bronchiolitis obliterans with organizing pneumonia o Idiopathic eosinophilic pneumonias o Idiopathic pulmonary fibrosis o Pneumocystis carinii pneumonia (PCP) associated with hypoxemia occurring in an HIV(+) individual who is also under treatment with appropriate anti-PCP antibiotics. o Symptomatic sarcoidosis • Renal Conditions o To induce a diuresis or remission of proteinuria in nephrotic syndrome, without uremia, of the idiopathic type or that due to lupus erythematosus • Rheumatologic Conditions: As adjunctive therapy for short-term administration (to tide the patient over an acute episode or		gravis), or in patients receiving concomitant therapy with neuromuscular blocking drugs (e.g., pancuronium). This acute myopathy is generalized, may involve ocular and respiratory muscles, and may result in quadriparesis. Elevation of creatinine kinase may occur. Clinical improvement or recovery after stopping corticosteroids may require weeks to years.

		exacerbation) in: o Acute gouty arthritis • During an exacerbation or as maintenance therapy in selected cases of: o Ankylosing spondylitis o Dermatomyositis/polymyositis o Polymyalgia rheumatica o Psoriatic arthritis o Relapsing polychondritis o Rheumatoid arthritis, including juvenile rheumatoid arthritis (selected cases may require low dose maintenance therapy) o Systemic lupus erythematosus o Vasculitis • Specific Infectious Diseases o Trichinosis with neurologic or myocardial involvement. o Tuberculous meningitis with subarachnoid block or impending block used concurrently with appropriate antituberculous chemotherapy.		
Medrol® (methylprednisolone)[5] Depo-Medrol® (methylprednisolone acetate)[6] Solu-Medrol® (methylprednisolone sodium succinate)[7]	Oral tablet Intramuscular injection Intravenous or intramuscular injection	• Similar Indications as listed in the prednisolone row with the following additional: o Acute and subacute bursitis o Synovitis of osteoarthritis o Acute nonspecific tenosynovitis o Post-traumatic osteoarthritis o Epicondylitis o Severe seborrheic dermatitis o Severe psoriasis o Allergic corneal marginal ulcers o Herpes zoster ophthalmicus o Loeffler's syndrome not manageable by other means o Erythroblastopenia • Not indicated for: o Crohn's Disease o Transfusion reactions	• Systemic fungal infections • Injectable formulation: NOT FOR USE IN NEWBORNS	Similar Warnings/Precautions the prednisolone with the following additional: • In patients on corticosteroid therapy subjected to unusual stress, increased dosage of rapidly acting corticosteroids before, during, and after the stressful situation is indicated. • The use of methylprednisolone tablets in active tuberculosis should be restricted to those cases of fulminating or disseminated tuberculosis in which the corticosteroid is used for the management of the disease in conjunction with an appropriate antituberculous regimen. • If corticosteroids are indicated in patients with latent tuberculosis or tuberculin reactivity, close observation is necessary as reactivation of the disease may occur. During prolonged corticosteroid therapy, these patients should receive chemoprophylaxis.

		o Pure red cell aplasia o Vasculitis o Allergic bronchopulmonary aspergillosis o Aspiration pneumonitis o Hypersensitivity pneumonitis o Idiopathic bronchiolitis obliterans with organizing pneumonia o Idiopathic pulmonary fibrosis o Pneumocystis carinii pneumonia (PCP) associated with hypoxemia occurring in an HIV(+) individual who is also under treatment with appropriate anti-PCP antibiotics. o Polymyalgia rheumatica o Relapsing polychondritis		• Persons who are on drugs which suppress the immune system are more susceptible to infections than healthy individuals. Drug-induced secondary adrenocortical insufficiency may be minimized by gradual reduction of dosage. This type of relative insufficiency may persist for months after discontinuation of therapy; therefore, in any situation of stress occurring during that period, hormone therapy should be reinstituted. Since mineralocorticoid secretion may be impaired, salt and/or a mineralocorticoid should be administered concurrently. • There is an enhanced effect of corticosteroids on patients with hypothyroidism and in those with cirrhosis. • Corticosteroids should be used cautiously in patients with ocular herpes simplex because of possible corneal perforation. • The lowest possible dose of corticosteroid should be used to control the condition under treatment, and when reduction in dosage is possiathyble, the reduction should be gradual. • Steroids should be used with caution in nonspecific ulcerative colitis, if there is a probability of impending perforation, abscess or other pyogenic infection; diverticulitis; fresh intestinal anastomoses; active or latent peptic ulcer; renal insufficiency; hypertension; osteoporosis; and myasthenia gravis. • Since complications of treatment with glucocorticoids are dependent on the size of the dose and the duration of treatment, a risk/benefit decision must be made in each individual case as to dose and duration of treatment and as to whether daily or intermittent therapy should be used. **Injection Specific**: • This product contains benzyl alcohol. Benzyl alcohol has been associated with a fatal “Gasping Syndrome” in premature infants and infants of low birth weight. Exposure to excessive amounts of benzyl alcohol has been associated with toxicity (hypotension, metabolic acidosis), particularly in neonates, and an increased incidence of

				kernicterus, particularly in small preterm infants. There have been rare reports of deaths, primarily in preterm infants, associated with exposure to excessive amounts of benzyl alcohol. • Rare instances of anaphylactoid reactions have occurred in patients receiving corticosteroid therapy • Increased dosage of rapidly acting corticosteroids is indicated in patients on corticosteroid therapy subjected to any unusual stress before, during, and after the stressful situation. • Literature reports suggest an apparent association between use of corticosteroids and left ventricular free wall rupture after a recent myocardial infarction; therefore, therapy with corticosteroids should be used with great caution in these patients. • Metabolic clearance of corticosteroids is decreased in hypothyroid patients and increased in hyperthyroid patients. Changes in thyroid status of the patient may necessitate adjustment in dosage. • Fungal Infections: Corticosteroids may exacerbate systemic fungal infections and therefore should not be used in the presence of such infections unless they are needed to control drug reactions. Corticosteroids should not be used in cerebral malaria. • Latent disease may be activated or there may be an exacerbation of intercurrent infections due to pathogens, including those caused by Amoeba, Candida, Cryptococcus, Mycobacterium, Nocardia, Pneumocystis, and Toxoplasma. • Tuberculosis: If corticosteroids are indicated in patients with latent tuberculosis or tuberculin reactivity, close observation is necessary as reactivation of the disease may occur. During prolonged corticosteroid therapy, these patients should receive chemoprophylaxis. • Viral Infections: Chicken pox and measles can have a more serious or even fatal course in pediatric and adult patients on corticosteroids • This product, like many other steroid formulations, is sensitive to heat. Therefore, it should not be autoclaved when it is desirable to sterilize the exterior of the vial.

				• The lowest possible dose of corticosteroid should be used to control the condition under treatment. When reduction in dosage is possible, the reduction must be gradual. • Cardio-renal: As sodium retention with resultant edema and potassium loss may occur in patients receiving corticosteroids, these agents should be used with caution in patients with congestive heart failure, hypertension, or renal insufficiency. • Endocrine: Drug-induced secondary adrenocortical insufficiency may be minimized by gradual reduction of dosage. • Although controlled clinical trials have shown corticosteroids to be effective in speeding the resolution of acute exacerbations of multiple sclerosis, they do not show that they affect the ultimate outcome or natural history of the disease. • An acute myopathy has been observed with the use of high doses of corticosteroids, most often occurring in patients with disorders of neuromuscular transmission (e.g., myasthenia gravis), or in patients receiving concomitant therapy with neuromuscular blocking drugs (e.g., pancuronium). • Corticosteroids may suppress reactions to skin tests. • Vaccines: Patients on prolonged corticosteroid therapy may exhibit a diminished response to toxoids and live or inactivated vaccines due to inhibition of antibody response. Corticosteroids may also potentiate the replication of some organisms contained in live attenuated vaccines. Routine administration of vaccines or toxoids should be deferred until corticosteroid therapy is discontinued if possible
Aristospan® (triamcinolone hexacetonide)[8] Kenalog-10® (triamcinolone acetonide)[9]	Intralesional injection	The intralesional administration of triamcinolone hexacetonide injectable suspension is indicated for: • alopecia areata • discoid lupus erythematosus • keloids • localized hypertrophic	NOT FOR USE IN NEWBORNS	Similar Warnings/Precautions the prednisolone with injection specific warnings in the methylprednisolone row.

		• infiltrated • inflammatory lesions of granuloma annulare • lichen planus • lichen simplex chronicus (neurodermatitis) • psoriatic plaques • necrobiosis lipoidica diabeticorum • cystic tumors of an aponeurosis or tendon (ganglia)		
Celestone Soluspan® (betamethasone)[10]	Intralesional injection	Intralesional injection has similar indications as listed in the triamcinolone row.	NOT FOR USE IN NEWBORNS	Similar Warnings/Precautions the prednisolone with injection specific warnings in the methylprednisolone row.
Elocon® (mometasone furoate)[11]	Topical cream	Corticosteroid indicated for the relief of the inflammatory and pruritic manifestations of corticosteroid-responsive dermatoses in patients 2 years of age or older	---	• Reversible HPA axis suppression with the potential for glucocorticosteroid insufficiency after withdrawal of treatment, Cushing's syndrome, and hyperglycemia may occur due to systemic absorption. Patients applying a topical steroid to a large surface area or to areas under occlusion should be evaluated periodically for evidence of HPA axis suppression. Modify use should HPA axis suppression develop. • Pediatric patients may be more susceptible to systemic toxicity. • Allergic Contact Dermatitis: If irritation develops, mometasone furoate should be discontinued and appropriate therapy instituted. • Concomitant Skin Infections: If concomitant skin infections are present or develop, an appropriate antifungal or antibacterial agent should be used. If a favorable response does not occur promptly, mometasone furoate use of should be discontinued until the infection has been adequately controlled.
Zyclara® (imiquimod)[12] Aldara® (imiquimod)[13]	2.5% to 3.75% Topical cream	Indicated for the treatment of external genital and perianal warts (EGW)/condyloma acuminata in patients 12 years or older.	---	• Local Skin Reactions: Intense local skin reactions including skin weeping or erosion can occur after a few applications and may require an interruption of dosing. Imiquimod has the potential to exacerbate inflammatory conditions of the skin, including chronic graft versus host disease.

	5% Topical cream			Severe local inflammatory reactions of the female external genitalia can lead to severe vulvar swelling. Severe vulvar swelling can lead to urinary retention. Dosing should be interrupted or discontinued for severe vulvar swelling. Administration of imiquimod is not recommended until the skin is healed from any previous drug or surgical treatment. • Systemic Reactions Flu-like signs and symptoms may accompany, or even precede, local skin reactions and may include fatigue, nausea, fever, myalgias, arthralgias, malaise and chills. • Ultraviolet Light Exposure Risks: Exposure to sunlight (including sunlamps) should be avoided or minimized during use of imiquimod. • Increased Risk of Adverse Reactions with Concomitant Imiquimod Use • Immune Cell Activation in Autoimmune Disease: Imiquimod should be used with caution in patients with pre-existing autoimmune conditions because imiquimod activates immune cells

Table H-2: FDA Approved Adult Medications (Prescribed Off-Label in Pediatric Patients) Included in Literature Review

Drug	Dosage Form	FDA Approved Indication	Contraindications	Warnings/ Precautions
Tenormin® (atenolol)[14]	Oral tablet	• Treatment of hypertension, to lower blood pressure • Long-term management of patients with angina pectoris. • Management of hemodynamically stable patients with definite or suspected acute myocardial infarction to reduce cardiovascular mortality	• Sinus bradycardia • Heart block greater than first degree • Cardiogenic shock • Overt cardiac failure	• Cardiac Failure: Sympathetic stimulation is necessary in supporting circulatory function in congestive heart failure, and beta blockade carries the potential hazard of further depressing myocardial contractility and precipitating more severe failure. • In Patients Without a History of Cardiac Failure: Continued depression of the myocardium with beta-blocking agents over a period of time can, in some cases, lead to cardiac failure • Cessation of Therapy with Atenolol: Patients with coronary artery disease, who are being treated with atenolol, should be advised against abrupt discontinuation of therapy. • Concomitant Use of Calcium Channel Blockers: Bradycardia and heart block can occur and the left ventricular end diastolic pressure can rise when beta-blockers are administered with verapamil or diltiazem. Patients with pre-existing conduction abnormalities or left ventricular dysfunction are particularly susceptible. • Bronchospastic Diseases: Patients with bronchospastic disease should, in general, not receive beta blockers. Because of its relative beta1 selectivity, however, atenolol may be used with caution in patients with bronchospastic disease who do not respond to, or cannot tolerate, other antihypertensive treatment. • Major Surgery: Chronically administered beta-blocking therapy should not be routinely withdrawn prior to major surgery, however the impaired ability of the heart to respond to reflex adrenergic stimuli may augment the risks of general anesthesia and surgical procedures. • Diabetes and Hypoglycemia: atenolol should be used with caution in diabetic patients if a beta-blocking agent is required. Beta blockers may mask tachycardia occurring with hypoglycemia, but other manifestations such as dizziness and sweating may not be significantly affected. • Thyrotoxicosis: Beta-adrenergic blockade may mask certain clinical signs (eg, tachycardia) of hyperthyroidism. Abrupt withdrawal of beta blockade might precipitate a thyroid storm; therefore, patients suspected of developing thyrotoxicosis from whom atenolol therapy is to be withdrawn should be monitored closely. • Untreated Pheochromocytoma: atenolol should not be given to patients with untreated pheochromocytoma.
Timoptic®	Ophthalmic	Treatment of elevated	• Bronchial asthma	• Cardiac Failure: sympathetic stimulation may be essential for

(timolol maleate)[15] Timoptic-XE® (timolol maleate)[16] Betimol® (timolol)[17]	Solution	intraocular pressure in patients with ocular hypertension or open-angle glaucoma.	• A history of bronchial asthma • Severe chronic obstructive pulmonary disease • Sinus bradycardia • Second or third degree atrioventricular block • Overt cardiac failure • Cardiogenic shock .	support of the circulation in individuals with diminished myocardial contractility, and its inhibition of beta-adrenergic receptor blockade may precipitate more severe failure. • In Patients Without a History of Cardiac Failure: continued depression of the myocardium with beta-blocking agents over a period of time can, in some cases, lead to cardiac failure. At the first sign or symptom of cardiac failure, timolol should be discontinued. • Major Surgery: Beta-adrenergic receptor blockade impairs the ability of the heart to respond to beta-adrenergically mediated reflex stimuli. This may augment the risk of general anesthesia in surgical procedures. In patients undergoing elective surgery, some authorities recommend gradual withdrawal of beta-adrenergic receptor blocking agents. • Diabetes Mellitus: Beta-adrenergic blocking agents should be administered with caution in patients subject to spontaneous hypoglycemia or to diabetic patients (especially those with labile diabetes) who are receiving insulin or oral hypoglycemic agents. Beta-adrenergic receptor blocking agents may mask the signs and symptoms of acute hypoglycemia. • Thyrotoxicosis: Beta-adrenergic blocking agents may mask certain clinical signs (e.g., tachycardia) of hyperthyroidism.: • Because of potential effects of beta-adrenergic blocking agents on blood pressure and pulse, these agents should be used with caution in patients with cerebrovascular insufficiency • There have been reports of bacterial keratitis associated with the use of multiple-dose containers of topical ophthalmic products. • Choroidal detachment after filtration procedures has been reported with the administration of aqueous suppressant therapy (e.g. timolol). • Angle-closure glaucoma: In patients with angle-closure glaucoma, the immediate objective of treatment is to reopen the angle. This requires constricting the pupil. Timolol maleate has little or no effect on the pupil. Timolol should not be used alone in the treatment of angle-closure glaucoma. • Anaphylaxis: While taking beta-blockers, patients with a history of atopy or a history of severe anaphylactic reactions to a variety of allergens may be more reactive to repeated accidental, diagnostic, or therapeutic challenge with such allergens. • Muscle Weakness: Beta-adrenergic blockade has been reported to potentiate muscle weakness consistent with certain myasthenic symptoms (e.g., diplopia, ptosis, and generalized weakness). Timolol has been reported rarely to increase muscle weakness in some patients with myasthenia gravis or myasthenic symptoms.

Harms Data for Medications Included in the Analysis

The following sections provide an overview of the common and notable adverse events of each medication. When possible, adverse event data specific for pediatric patients have been included. It is important to note that the information provided in this section is not an all-inclusive list of adverse events. Consult the corresponding package insert for complete information. Many of the adverse events reported are from various clinical trials used in support of the medication's FDA approval. As a result, these trials many have been conducted under varying conditions and the adverse event rates may not reflect what is observed in clinical practice. In addition, these rates may not necessarily be able to be compared to the rates observed in the clinical trials of different drugs. Post-marketing adverse events are reported on a voluntary basis and therefore do not represent complete patient data.

Hemangeol® (propranolol hydrochloride)

Hemangeol® is the only medication included in this review that has an FDA approved indication for infantile hemangioma. The safety of Hemageol® in pediatric patients has been reported in the medication package insert.[1] FDA medical review packages were not available for this medication.

The most common adverse events, occurring in greater than 10% of infants, were sleep disorders, aggravated respiratory tract infections such as bronchitis and bronchiolitis associated with cough and fever, diarrhea, and vomiting.[1] In a study of pooled safety data (n=424), infants (63% aged 91-150 days) were treated with Hemangeol® 1.2 mg/kg/day or 3.4 mg/kg/day for 3 or 6 months. Treatment emergent adverse events occurring in 3% or greater in infants receiving the Hemangeol® 1.2 mg/kg/day (n=200) or Hemangeol® 3.4 mg/kg/day (n=224) compared to placebo were provided. Adverse events and frequencies for patients receiving Hemangeol® 1.2 mg/kg/day included: sleep disorders (17.5%), bronchitis (8%), peripheral coldness (8%), agitation (8.5%), diarrhea (4.5%), somnolence (5.0%), nightmare (2.0%), irritability (5.5%), decreased appetite (2.5%), and abdominal pain (3.5%). Adverse events and frequencies for patients receiving Hemangeol® 3.4 mg/kg/day (n=224) included: sleep disorders (16.1%), bronchitis (13.4%), peripheral coldness (6.7%), agitation (4.5%), diarrhea (6.3%), somnolence (0.9%), nightmare (6.3%), irritability (1.3%), decreased appetite (3.6%), and abdominal pain (0.4%). Additional adverse events reported in less than 1% of patients participating in clinical trials included: second degree atrioventricular heart block (occurring in a patient with underlying conduction disorder), urticaria, alopecia, decreased blood glucose, and decreased heart rate.

Additional Formulations

The safety and efficacy of the oral tablet, oral capsule, and injectable formulations of propranolol have not been investigated in pediatric patients.[18-20] The package inserts for these formulations state that reports of bronchospasm and congestive heart failure have been reported in pediatric patients receiving propranolol.

Post-marketing Adverse Events

Additional adverse events revealed during post-marketing surveillance include: agranulocytosis, hallucination and purpura.[1]

Corticosteroids

The safety and efficacy of pediatric use of corticosteroids has been studied in the literature for the treatment of nephrotic syndrome (>2 years of age), and aggressive lymphomas and leukemias (>1 month of age).[2-4,6,7,10] It has been reported that the adverse events identified in pediatric patients were similar to the events experienced in adults. Monitoring pediatric patients for blood pressure, weight, height, intraocular pressure, and clinical evaluation for the presence of infection, psychosocial disturbances, thromboembolism, peptic ulcers, cataracts, and osteoporosis is recommended. Specifically, pediatric patients may have a decrease in growth velocity after taking corticosteroids by any route of administration. Therefore, children should be titrated to the lowest effective dose.

Common adverse events of corticosteroids include: fluid retention, alteration in glucose tolerance, elevation in blood pressure, behavioral and mood changes, increased appetite and weight gain.[2-10] Additional adverse events include: anaphylactoid reaction, anaphylaxis, angioedema, bradycardia, cardiac arrest, cardiac arrhythmias, cardiac enlargement, circulatory collapse, congestive heart failure, fat embolism, hypertension, hypertrophic cardiomyopathy in premature infants, myocardial rupture following recent myocardial infarction, pulmonary edema, syncope, tachycardia, thromboembolism, thrombophlebitis, vasculitis, acne, allergic dermatitis, cutaneous and subcutaneous atrophy, dry scalp, edema, facial erythema, hyper or hypopigmentation, impaired wound healing, increased sweating, petechiae and ecchymoses, rash, sterile abscess, striae, suppressed reactions to skin tests, thin fragile skin, thinning scalp hair, urticaria, abnormal fat deposits, decreased carbohydrate tolerance, development of Cushingoid state, hirsutism, manifestations of latent diabetes mellitus and increased requirements for insulin or oral hypoglycemic agents in diabetics, menstrual irregularities, moon faces, secondary adrenocortical and pituitary unresponsiveness (particularly in times of stress, as in trauma, surgery or illness), suppression of growth in children, potassium loss, hypokalemic alkalosis, sodium retention, abdominal distention, elevation in serum liver enzymes levels (usually reversible upon discontinuation), hepatomegaly, hiccups, malaise, nausea, pancreatitis, peptic ulcer with possible perforation and hemorrhage, ulcerative esophagitis, osteonecrosis of femoral and humeral heads, charcot-like arthropathy, loss of muscle mass, muscle weakness, osteoporosis, pathologic fracture of long bones, steroid myopathy, tendon rupture, vertebral compression fractures, arachnoiditis, convulsions, depression, emotional instability, euphoria, headache, increased intracranial pressure with papilledema (pseudo-tumor cerebri) usually following discontinuation of treatment, insomnia, meningitis, mood swings, neuritis, neuropathy, paraparesis/paraplegia, paresthesia, personality changes, sensory disturbances, vertigo, exophthalmos, glaucoma, increased intraocular pressure, posterior subcapsular cataracts, alteration in motility and number of spermatozoa.

Flo-pred® (prednisolone acetate), Orapred ODT (prednisolone sodium phosphate)

The adverse events reported for Flo-pred® and Orapred ODT® in adult patients has been compiled from the package insert and the original FDA approval package assessing the safety of adult patients with rheumatoid arthritis.[2,3,21] Common adverse events for Flo-pred and Orapred ODT have been reported in the common adverse events for corticosteroids in general (see above).[2,3] Bioequivalence studies conducted in healthy volunteers assessing prednisolone oral suspension, prednisolone syrup, and prednisolone tablet were reported in the Flo-pred® original FDA approval document.[21] The following adverse events were reported across 3 of these studies (see table 3).

Table H-3: Adverse Events from Flo-pred® Bioequivalence Studies[21]

	Study 1			Study 2			Study 3		
	Suspension (n=24)	Syrup (n=24)	Tablet (n=24)	Suspension (n=24)	Syrup (n=23)	Tablet (n=24)	Suspension (n=24)	Syrup (n=23)	Tablet (n=23)
Arthralgia	0	0	1 (4%)	0	0	1 (4%)	0	0	1 (4%)
Headache	1 (4%)	0	0	3 (13%)	1 (4%)	6 (25%)	1 (4%)	1 (4%)	1 (4%)
Somnolence	0	1 (4%)	0	1 (4%)	0	0	0	0	1 (4%)
Dyspepsia	1 (4%)	1 (4%)	1 (4%)	1 (4%)	1 (4%)	0	---	---	---
Fatigue	1 (4%)	0	0	1 (4%)	0	1 (4%)	---	---	---
Hot Flash	0	1 (4%)	0	1 (4%)	1 (4%)	0	---	---	--
Venipuncture site pain	1 (4%)	0	1 (4%)	0	1 (4%)	0	---	---	---
Lymphocyte count increased	2 (8%)	2 (8%)	2 (8%)	1 (4%)	1 (4%)	1 (4%)	---	---	---
Neutrophil count decreased	1 (4%)	1 (4%)	1 (4%)	---	---	---	2 (8%)	2 (9%)	2 (9%)
Ocular hyperaemia	---	---	---	1 (4%)	0	1 (4%)	0	0	1 (4%)
Lip dry	---	---	---	1 (4%)	1 (4%)	0	0	0	1 (4%)
Nausea	---	---	---	2 (8%)	1 (4%)	1 (4%)	1 (4%)	0	0
Dizziness	---	---	---	1 (4%)	1 (4%)	0	0	1 (4%)	0
Venipuncture site swelling	1 (4%)	0	0	---	---	---	---	---	---
Blood Bilirubin increase	1 (4%)	1 (4%)	1 (4%)	---	---	---	---	---	---
Increased appetite	0	0	1 (4%)	---	---	---	---	---	---
Pharyngolaryngeal Pain	0	0	1 (4%)	---	---	---	---	---	---
Blister	1 (4%)	0	0						
Abdominal distension	---	---	---	0	0	1 (4%)	---	---	---
Abdominal pain	---	---	---	0	0	1 (4%)	---	---	---
Upper abdominal pain	---	---	---	0	0	1 (4%)	---	---	---
Diarrhea	---	---	---	0	0	1 (4%)	---	---	--
Dry mouth	---	---	---	1 (4%)	0	0	---	---	---
Flatulence	---	---	---	1 (4%)	0	0	---	---	---
Vomiting	---	---	---	1 (4%)	0	1 (4%)	---	---	---
Vessel puncture site bruise	---	---	---	1 (4%)	0	0	---	---	---
Tremor	---	---	---	1 (4%)	0	0	---	---	---
Metrorrhagia	---	---	---	1 (4%)	0	0	---	---	---
Nasal congestion	---	---	---	0	0	1 (4%)	---	---	---
Rhinorrhea	---	---	---	0	0	1 (4%)	---	---	---

Fixed eruption	---	---	---	1 (4%)	0	0	---	---	---
Catheter site pain	---	---	---	---	---	---	1 (4%)	0	0
Catheter site reaction	---	---	---	---	---	---	1 (4%)	0	0
Shivering	---	---	---	---	---	---	1 (4%)	0	0
Blood potassium	---	---	---	---	---	---	1 (4%)	1 (4%)	1 (4%)
Hypoaesthesia	---	---	---	---	---	---	0	1 (4%)	0

Bioavailability studies were also conducted for Orapred ODT® in 24 health patients each receiving Orapred ODT® 30mg tablet, Pediapred® oral solution 30mg and Orapred® oral solution 30mg. Adverse events reported in patients taking Oprapred ODT® included: face edema/swelling face, pharyngolaryngeal pain, blood in stool, eye irritation, and eyelid edema.

A search of the literature for adverse events associated with prednisolone was conducted by Taro Pharmaceuticals and reported in the FDA review package.[21] The most common adverse events reported in 4 pediatric studies (mean age <2 years) using prednisolone 1-2 mg/kg/day (n=187) for less than 1 week included: vomiting-nausea (5%), diarrhea (3%), restlessness (2%), rash-exanthema (1%), and jittery (1%). The most common adverse events reported in 6 adult studies (mean age 40-60 years) using prednisolone 5-60 mg/day (n=189) for 2 weeks to 2 years included: vomiting-nausea (5%), rash-exanthema (5%), headache (9%), gastric distress (8%), insomnia (6%), weight gain (6%), abdominal pain (5%), mood swings (4%), aggravated RA (3%), and hypertension (3%).

Post-marketing Adverse Events

Data specifically from pediatric patients reported in the Orapred ODT® original FDA approval documents included: urticaria (6), dyspea (1), wheezing (2), coughing (1), congestion (1), lethargy (1), confusion (1), could not stand or hold up head (1), back pain (1), double vision (1), slurred words (1), dizziness (1), difficulty breathing (1), tremor (1), dysphemia (1), head banging (1), and leukocytosis(1).[22] Serious adverse events included: depression, headache, abdominal pain and malaise which occurred in 1 patient. Four patients experienced hypersensitivity reactions: rash, swelling, itching, redness in the mouth, pain, and difficulty swallowing. Other events reported included: hyperchlesterolemia and lack of response, audea, emesis, diarrhea and bluding fontanelle, increased heart rate, psychiatric events, erythema, pruritis and rash.

Rayos® (prednisone)

The adverse events reported for Rayos® in adult patients has been compiled from the package insert and the original FDA approval package assessing the safety of adult patients with rheumatoid arthritis.[4,23]

Adverse events reported for Rayos® were similar to the common adverse events for corticosteroids in general (see above)[4] An additional common adverse event specifically listed in the Rayos® package insert was central serous chorioretinopathy.

The medical review document for Rayos® reported adverse events occurring in >2% of patients participating in phase 3 clinical studies.[23] These patients were treated with prednisone extended release (XL) (n=375) and prednisone immediate release tablets (IR) (n=144). Adverse events included: abdominal pain upper: XL=6 (<2%), IR=8 (6%); diarrhea: XL=4 (1%), IR=4 (3%); nausea: XL=8 (2%), IR=4 (3%); dyspepsia: XL=0, IR=3 (2%); nasopharyngitis: XL=16 (4%), IR=8 (6%); bronchitis: XL=5 (1%), IR=5 (4%); upper respiratory tract infection: XL=2

(<1%), IR=3 (2%); rheumatoid arthritis: XL=48 (13%), IR=14 (10%); vertigo: XL=4 (1%), IR=5 (4%); Headache: XL=15 (4%), IR=5 (4%); and chest pain: XL=2 (<1%), IR=0. In addition, hematology reference range changes have been reported in phase 3 clinical studies (see table 4).

Table H-4: Hematology Changes[23]

	Prednisone XL (n=375)	Prednisone IR (n=144)
Hemoglobin (g/L)		
Shift from Normal to Low	10 (3%)	11 (8%)
Shift from Normal to High	1 (1%)	0
Shift from High to Low	1 (0%)	0
WBC ($x10^3$/mcl)		
Shift from Normal to Low	3 (1%)	0
Shift from Normal to High	18 (5%)	16 (11%)
Basophils (%)		
Shift from Normal to High	11 (3%)	---
Eosinophils (%)		
Shift from Normal to High	2 (1%)	---
Lymphocytes (%)		
Shift from Normal to Low	32 (9%)	---
Shift from Normal to High	1 (0%)	---
Monocytes (%)		
Shift from Normal to Low	23 (6%)	---
Shift from Normal to High	3 (1%)	---
Shift from High to Low	1 (0%)	---
Neutrophils (%)		
Shift from Normal to Low	1 (0%)	---
Shift from Normal to High	41 (11%)	---
Platelets ($x10^3$/mcl)		
Shift from Normal to Low	1 (0%)	1 (1%)
Shift from Normal to High	24 (6%)	3 (2%)

Chemistry reference range shifts from normal at baseline to high after treatment with prednisone extended release (XL) (n=375) and prednisone immediate release (IR) (n=144) in phase 3 studies included: alk phos (U/L): XL=6 (2%), IR=2 (1%); ALT/SGPT (U/L): XL=13 (4%), IR=5 (4%); AST/SGOT (U/L): XL=13 (4%), IR=7 (5%); GGT (U/L): XL=15 (4%), IR=8 (5%); bilirubin (umg/dL): XL=2 (<1%), IR=0; albumin (g/L): XL=2 (<1%), IR=0 (0%); protein (g/L): XL=3 (1%), IR=1 (<1%); cholesterol (mmol/L): XL=54 (14%), IR=15 (10%); triglycerides (mmol/L): XL=17 (5%), IR=15 (10%); BUN (mmol/L): XL=7 (2%), IR=0; creatinine (umol/L): XL=9 (2%), IR=3 (2%); glucose (mmol/L): XL=28 (8%), IR=18 (13%); calcium (mmol/L): XL=1 (<1%), IR=0; chloride (mmol/L): XL=3 (1%), IR=2 (1%); potassium (mmol/L): XL=6 (2%), IR=1 (<1%); and sodium (mmol/L): XL=8 (2%), IR=1 (<1%).[23]

Serious Adverse Events

Serious adverse events from controlled phase 3 studies reported in the FDA review document for extended release prednisone (XL) (n=375) and immediate release prednisone (IR) (n=144) include: myocardial infarction: XL=1 (<1%), IR=0; abdominal pain: XL=0, IR=1 (<1%); chest pain: XL=1 (<1%), IR=1 (<1%); sudden death: XL=0, IR=1 (<1%); tendon rupture: XL=0, IR=1 (<1%); osteoarthritis: XL=1 (<1%), IR=0; synovial cyst: XL=1 (<1%), IR = 0; squamous cell carcinoma: XL=1 (<1%), IR= 0; depressed level of consciousness: XL=0, IR=1 (<1%); pulmonary embolism: XL=0, IR=1 (<1%); hospitalization: XL=1 (<1%), IR=0; and limb operation: XL=1 (<1%), IR=0.[23]

An additional clinical trial assessing the safety of prednisone extended release was conducted in Germany and included 2676 patients in the safety analysis.[23] Serious adverse events reported included: gastrointestinal disorders (5 events, <1%), general disorders and administration site conditions (4 events; <1%), injury, poisoning and procedural complications (3 events; <1%) and skin and subcutaneous disorders (3 events; <1%), GI bleeding (1 event), hemorrhagic proctitis (1 event), stomach pain/ache (1 event), and red skin (1 event).

Discontinuations

The following adverse events led to discontinuation in patients taking extended release prednisone (XL) (n=375) and immediate release prednisone (IR) (n=144) in phase 3 clinical trials: palpitations: XL=1 (<1%), IR=0; vertigo: XL=0, IR=1 (1%); glaucoma: XL=1 (<1%), IR=0; abdominal pain: XL=1 (<1%), IR=0; upper abdominal pain: XL=0, IR=2 (1%); constipation: XL=1 (<1%), IR=0; dyspepsia: XL=1 (<1%), IR=0; gastroesophageal reflux disease: XL=0, IR=1 (1%); intestinal functional disorder: XL=0, IR=1 (1%); nausea: XL=0, IR=2 (1%); vomiting: XL=1 (<1%), IR=0; sudden death: XL=0, IR=1 (1%); rheumatoid arthritis: XL=5 (1%), IR=2 (1%); aphasia: XL=0, IR=1 (1%); depressed level of consciousness: XL=0, IR=1 (1%); dizziness: XL=0, IR=1 (1%); headache: XL=2 (1%), IR=1 (1%); anxiety: XL=1 (<1%), IR=0; insomnia: XL=2 (1%), IR = 0; sleep disorder: XL=1 (<1%), IR=0; renal pain: XL=0, IR=1 (1%); and secondary hypertension: XL=1 (<1%), IR=0.[23]

Reasons for discontinuation in the German clinical trial (n=2676) assessing prednisone extended release included: nausea (22; 1%), upper abdominal pain (18; 1%), sleep disorders (16; 1%), RA (11; <1%), headache (9; <1%), dizziness (6; <1%) and glucose metabolism (3 patients with diabetes; <1%, and 3 patients with blood glucose increased; <1%).[23]

Post-marketing Adverse Events

Horizon Pharma completed a search of the FDA's Spontanous Reporting system and the Adverse Event Reporting System for prednisone (date range: January 1, 1969 through March 31, 2010) and identified a total of 965,454 adverse events.[23] Adverse events reported at a frequency of >0.5% included: diarrhea: 5293 (0.5%), nausea: 8419 (0.9%), vomiting: 4889 (0.5%), asthenia: 5541 (0.6%), condition aggravated: 5774 (0.6%), drug ineffective: 6078 (0.6%), fatigue: 5877 (0.6%), pyrexia: 11692 (1.2%), pneumonia: 6305 (0.7%), arthralgia: 5240 (0.5%), and dyspnea: 7570 (0.8%).

Medrol® (methylprednisolone), Depo-Medrol® (methylprednisolone acetate), Solu-Medrol® (methylprednisolone sodium succinate)

Adverse event data for Medrol®, Depo-Medrol®, and Solu-Medrol® was gathered from the corresponding package inserts.[5-7] FDA approval packages were not available for any of the methylprednisolone products.

The use of Medrol® for pediatric patients was not included in the package inert.[5] The adverse events for Medrol® included all of the adverse events listed in general for corticosteroids (see above) with the addition of: negative nitrogen balance due to protein catabolism.[5] The following adverse events have been reported for general corticosteroids but were **NOT** included as adverse events for Medrol®: alteration in glucose tolerance, not behavioral and mood changes, mood swings, increased appetite and weight gain, bradycardia, cardiac arrest, cardiac arrhythmias, cardiac enlargement, circulatory collapse, fat embolism, abnormal fat deposits, hypertrophic cardiomyopathy in premature infants, myocardial rupture following recent myocardial infarction, pulmonary edema, syncope, tachycardia,

thromboembolism, thrombophlebitis, vasculitis, acne, cutaneous and subcutaneous atrophy, dry scalp, edema, hyper or hypopigmentation, sterile abscess, striae, thinning scalp hair, hirsutism, moon faces, hepatomegaly, hiccups, malaise, nausea, charcot-like arthropathy, arachnoiditis, depression, emotional instability, euphoria, insomnia, meningitis, neuritis, neuropathy, paraparesis/paraplegia, paresthesia, personality changes, sensory disturbances, and alteration in motility/number of spermatozoa.

Warnings for the use of Depo-Medrol® and Solu-Medrol® in pediatric patients due to the presence of benzyl alcohol have been described above (see Table H-1).[6,7]

Adverse events for Depo-Medrol® and Solu-Medrol® were similar to those listed in general for corticosteroids (see above) with the addition of: dry scaly skin, glycosuria, hypertrichosis, negative nitrogen balance due to protein catabolism, injection site infections following non-sterile administration, postinjection flare (following intra-articular use), temporary/permanent visual impairment including blindness associated with periocular injections and decreased resistance to infection.[6,7]

Depo-Medrol® has unique adverse events reported in addition to those listed above: calcinosis (following intra-articular or intra-lesional use), seizures, ocular and periocular inflammation including allergic reactions, and residue or slough at injection site.[6]

Additional adverse events reported for Solu-Medrol® included: rhinitis and burning or tingling (especially in the perineal area after intravenous injection).[7]

Aristospan® (triamcinolone hexacetonide), Kenalog-10® (triamcinolone acetonide)

Aristospan® (triamcinolone hexacetonide), Kenalog-10® (triamcinolone acetonide) includes pediatric dosing in the FDA approved labeling.[8,9] FDA review packages were not available for this medication. Warnings for the use of Aristospan® and Kenalog-10® in pediatric patients due to the presence of benzyl alcohol have been described above (see Table H-1).

Adverse events for Aristospan® and Kenalog-10® were similar to those listed in general for corticosteroids (see above) with the addition of: dry scaly skin, glucosuria, hypertrichosis, negative nitrogen balance due to protein catabolism, calcinosis (following intra-articular or intralesional use), postinjection flare (following intra-articular use), rare instances of blindness associated with periocular injections, and decreased resistance to infection.[8,9] FDA medical review packages were not available for these medications.

Celestone Soluspan® (betamethasone)

Adverse event data for Celestone Soluspan® was gathered from the package insert.[10] FDA approval packages were not available for review.

Adverse events for Celestone Soluspan® were similar to those listed in general for corticosteroids (see above) with the addition of: dry scaly skin, glucosuria, hypertrichosis, negative nitrogen balance due to protein catabolism, calcinosis (following intra-articular or intralesional use), postinjection flare (following intra-articular use), rare instances of blindness associated with periocular injections, and decreased resistance to infection.[10] The following adverse events have been reported for general corticosteroids but were **NOT** included as adverse events for Celestone Soluspan®: manifestations of latent diabetes mellitus and menstrual irregularities.

Elocon® (mometasone furoate)

The use of this medication in pediatric patients (≥2 years) is recommended for less than 3 weeks.[11] This medication is administered topically and pediatric patients will have an increase in the skin surface area to body mass ratio. As a result, adverse events such as HPA axis suppression, Cushing's syndrome, adrenal insufficiency upon withdraw, skin atrophy, striae, linear growth retardation, delayed weight gain, and intracranial hypertension are more likely to occur in pediatric patients.

The adverse event data for Elocon® was obtained from the package insert.[11] FDA approval packages were not available for this medication. The package insert notes that rates of adverse events may differ in clinical practice because clinical trials for Elocon® were conducted under variable conditions. In pediatric studies (n=74), 7% of patients experienced adverse events including: stinging, pruritus, and furunculosis. In a pediatric trial, 24 patients (age 6 to 23 months) used Elcon® cream for 3 weeks covering a mean body surface area of 41%. Sixteen percent of patients reported HPA axis suppression after treatment. Additional adverse events reported in pediatric (age 6 months to 2 years) trials (n=182) included: decreased glucocorticoid levels (2), paresthesia (2), folliculitis (1) moniliasis (1), bacterial infection (1), skin depigmentation (1). Ninety seven patients, participating in a clinical trial, experienced skin atrophy including: shininess (4), telangiectasia (1), loss of elasticity (4), loss of normal skin markings (4), thinness (1), and bruising (1). Adverse events that have been reported for topical corticosteroids in general include: irritation, dryness, folliculitis, hypertrichosis, acneiform eruptions, hypopigmentation, perioral dermatitis, allergic contact dermatitis, secondary infection, striae, and miliaria.

Aldara® (imiquimod), Zyclara® (imiquimod)

Package inserts and original FDA approval packages were utilized to gather safety information for these medications.[12,13,24]

It has been reported that the pediatric patients applying Aldara® for molluscum contagiosum experienced application site reactions most often.[12,13,25] Additional adverse events reported in these trials were similar to those reported in adult patient with the addition of: otitis media (5%) and conjunctivitis (3%). Local skin reactions reported in pediatric patients and considered severe include: erythema (28%), edema (8%), scabbing/crusting (5%), flaking/scaling (5%), erosion (2%) and weeping/exudate (2%).

The Aldara® package insert notes that rates of adverse events may differ in clinical practice because clinical trials were conducted under variable conditions.[13] The following adverse events were reported in >1% of adult patients applying Aldara® to the face or scalp 2 times a week for 16 weeks for actinic keratosis (n=215): application site reaction: 71 (33%), upper respiratory tract infection: 33 (15%), sinusitis: 16 (7%), headache: 11 (5%), carcinoma squamous: 8 (4%), diarrhea: 6 (3%), eczema: 4 (2%), back pain: 3 (1%), fatigue: 3 (1%), atrial fibrillation: 3 (1%), viral infection: 3 (1%), dizziness: 3 (1%), vomiting: 3 (1%), UTI: 3 (1%), fever: 3 (1%), rigors: 3 (1%), and alopecia: 3 (1%). Specific application site reactions that were reported in >1% of adult patients taking Aldara® for actinic keratosis (n=215) included: itching: 44 (20%), burning: 13 (6%), bleeding: 7 (3%), stinging: 6 (3%), pain: 6 (3%), induration: 5 (2%), tenderness: 4 (2%), and irritation: 4 (2%). The following local skin reactions have been reported in adult patients applying Aldara® for actinic keratosis (n=215): erythema (all grades): 209 (97%), erythema (severe): 38 (18%), flaking/scaling/dryness (all grades): 199 (93%), flaking/scaling/dryness (severe): 16 (7%), scabbing/crusting (all grades): 169 (79%), scabbing/crusting (severe): 18 (8%), edema (all grades): 106 (49%), erosion/ulceration (all

grades): 103 (48%), erosion/ulceration (severe): 5 (2%), weeping/exudate (all grades): 45 (22%), and vesicles (all grades): 19 (9%). Increased scarring scores were reported in 2.9% (6/206) patients with a baseline and 8-week post treatment scarring assessment.

In patients applying Aldara® for genital warts, female patients reported severe skin reactions including: erythema (3%), ulceration (2%), and edema (1%); and for males, erosion (2%), and erythema (1%), edema (1%), induration (1%), and excoriation/flaking (1%).[13] The following adverse reactions were reported by >1% of patients: burning, hypopigmentation, irritation, itching, pain, rash, sensitivity, soreness, stinging, tenderness, bleeding, burning, itching, pain, tenderness, tinea cruris, fatigue, fever, influenza-like symptoms, headache, diarrhea and myalgia. Aldara® was studied in male and female patients (n=784) aged 15-77 (mean age 31.5) with genital warts. Patients applied Aldara® three times a week for 16 weeks.[25] Some patients were treated for up to 32 weeks if their warts were not cleared after the initial 16 week treatment. Common adverse events reported in >2% of patients included: application site reactions 26.7%, infection 3.8%, upper respiratory infection 3.3%, headache 2.5%, fatigue 2.1%, nausea 2.1%, herpes simplex 2.1%, and myalgia 2.0%. In a similar study of male and female patients (n=943) age 16-78 (mean 31.2) with genital warts, adverse events reported in >2% of patients included: application site reactions 27.7%, infection 4.5%, headache 2.9%, respiratory infection 2.1%, and myalgia 2%.

Similar to the Aldara® package insert, Zyclara® adverse events may differ in clinical practice because clinical trials were conducted under variable conditions.[12] Adult patients with actinic keratosis completing clinical trials applied Zyclara® daily for 2 weeks to their entire face or blading scalp. Treatment cycles were separated by 2 weeks of no treatment. Adverse reactions reported in clinical trials are listed below (see table 5). In addition to the adverse events included in the chart, the following events have been reported: application site bleeding, application site swelling, chills, dermatitis, herpes zoster, insomnia, lethargy, myalgia, pancytopenia, pruritus, squamous cell carcinoma, and vomiting.

Table H-5: Zyclara® Adverse Event Data

	Zyclara® 2.5% (n=160)	**Zyclara® 3.75% (n=160)**
Adverse Events reported in ≥2% of Patients		
Headache	3(2%)	10(6%)
Application site pruritus	6(4%)	7(4%)
Fatigue	2(1%)	7(4%)
Nausea	1(1%)	6(4%)
Influenza like illness	6(4%)	1(<1%)
Application site irritation	4(3%)	5(3%)
Pyrexia	0	5(3%)
Anorexia	0	4(3%)
Dizziness	1(<1%)	4(3%)
Herpes simplex	0	4(3%)
Application site pain	2(1%)	5(3%)
Lymphadenopathy	4(3%)	3(2%)
Oral herpes	4(3%)	0
Arthralgia	4(3%)	2(1%)
Cheilitis	3(2%)	0
Diarrhea	2(1%)	3(2%)
Local Skin Reactions		
Erythema (Mild, moderate or severe)	96%	96%
Severe erythema	14%	25%
Scabbing/Crusting	84%	93%

(mild, moderate or severe)		
Severe scabbing/crusting	9%	14%
Edema (mild, moderate or severe)	63%	75%
Severe edema	4%	6%
Erosion/Ulceration (mild, moderate or severe)	52%	62%
Severe erosion/ulceration	9%	11%
Exudate (mild, moderate or severe)	39%	51%
Severe Exudate	1%	6%
Flaking/Scaling/Dryness (mild, moderate or severe):	88%	91%
Severe Flaking/Scaling/Dryness	4%	8%

An additional database review of Zyclara® (n=779) across two clinical trials, revealed the following adverse events reported in >1% of patients (see table 6).[25]

Tablet H-6: Common Adverse Events Reported in >1% of Patients

	Zyclara® 3.75% (n=400)	**Zyclara® 2.5% (n=379)**
Application site pain	28 (7.0%)	20 (5.3%)
Application site irritation	24 (6.0%)	13 (3.4%)
Nasopharyngitis	16 (4.0%)	21 (5.5%)
Upper respiratory tract infection	12 (3.0%)	7 (1.8%)
Application site pruritus	11 (2.8%)	17 (4.5%)
Headache	9 (2.3%)	8 (2.1%)
Vaginitis bacterial	8 (2.0%)	6 (1.6%)
Nausea	7 (1.8%)	4 (1.1%)
Back pain	7 (1.8%)	4 (1.1%)
Urinary tract infection	6 (1.5%)	6 (1.6%)
Sinusitis	6 (1.5%)	4 (1.1%)
Sinus congestion	6 (1.5%)	1 (0.3%)
Cough	5 (1.3%)	5 (1.3%)
Rash	5 (1.3%)	2 (0.5%)
Vomiting	5 (1.3%)	1 (0.3%)
Skin laceration	5 (1.3%)	1 (0.3%)

In patients applying Zyclara® 3.75% for genital warts (n=400) for up to 8 weeks, adverse events occurring in greater than ≥2% included: application site pain: 28 (7%), application site irritation: 24 (6%), application site pruritus: 11 (3%), vaginitis bacterial: 6/216 (3%), and headache: 6(2%). Additional local skin reactions that required medical attention, caused patients to discontinue the study or extended beyond the treatment area included: erythema (mild, moderate or severe): 70%, severe erythema: 9%, edema (mild, moderate or severe): 41%, severe edema: 2%, erosion/ulceration (mild, moderate or severe): 36%, severe erosion/ulceration: 11%, exudate (mild, moderate or severe): 34%, and severe exudate: 2%. In addition to the adverse events included above, these events have been reported: rash, back pain, application site rash, application site cellulitis, application site excoriation, application site bleeding, scrotal pain, scrotal erythema, scrotal ulcer, scrotal edema, sinusitis, nausea, pyrexia, and influenza-like symptoms.

Adverse events reported for Zyclara® from the sponsor's clinical trial safety database include: anginal pain (angia pectoris, prinzmetal angina): 3 (Rate=0.035%), arrhythmia: 15 (Rate=0.177%), ventricular arrthythmia: 2 (Rate=0.024%), cardiac arrest: 1 (Rate=0.012%), cardiac failure: 7 (Rate=0.083%), chest pain: 12 (Rate=0.142%), dizziness: 66 (Rate=0.780%), dyspnea: 2 (Rate=0.024%), fibrillation atrial: 12 (Rate=0.142%), hypotension: 2 (Rate=0.024%),

acute myocardial infarction: 3 (Rate=0.035%), palpitation: 9 (Rate=0.106%), pulmonary edema: 1 (Rate=0.012%), syncope: 7 (Rate=0.083%), tachycardia: 8 (Rate=0.095%), presyncope: 1 (Rate=0.012%), and tachycardia ventricular: 2 (Rate=0.024%).[24] It is important to note that the original FDA approval document only contains data for adult patients. Across five clinical trials, patients applying the medication for 2 to 3 week cycles (n=665) experienced the following adverse events most often: headache, local site reactions, fatigue and nausea. Patients using the higher dose (3.75%) of Zyclara experienced local cite reactions more often.

Two clinical trials assessing the use of Zyclara® 2.5% and 3.75% in adult patients with actinic keratosis were submitted in the original FDA approval document.[24] Patients age 36 to 90 applied the medication using one of two treatment cycles: 1) 3 weeks of treatment followed by 3 weeks of rest, 2) 3 weeks of treatment followed by 8 weeks of rest. Adverse events reported most often in patients applying Zyclara® included: application site adverse events, fatigue, headache, lymphadenopathy and influenza like illness.

Serious Adverse Events

Aldara® was studied in male and female patients (n=784) aged 15-77 (mean age 31.5) with genital warts. Patients applied Aldara® three times a week for 16 weeks.[25] Some patients were treated for up to 32 weeks if their warts were not cleared after the initial 16 weeks. Serious adverse events reported in this study included: acute appendicititis (1), skull fracture (1), increased depression/suicide attempt (1), suicide attempt/drug overdose (1), inferior mypcardial infarction (1), pyelonephritis (1), pacemaker generator exchange (1), pancreatitis (1), cervical cancer (1), exacerbation of depression (1), incomplete abortion (1), possible infection of GI tract (1), and heroin addiction (1). In a similar study of male and female patients (n=943) age 16-78 (mean 31.2) with genital warts, 14 patients experienced serious adverse events including: alteration in speech and sensation of spaciness (1), fracture of left clavicle (1); exacerbation of eczema at non-wart site (1), rectal pain due to internal warts-remote site (1), nephrotic syndrome (1), carcinoma of vulva (1), vulval pain (with anorexia and fatigue) (1), depression (1), lymphangitis due to dog bite (1), axillary abscess (1), laryngeal cancer (1), vomiting and abdominal pain (1), cholecystectomy (1), flu (1), tonsil abscess (1), metrorrhagia (1), and act fetal distress (1).

The first clinical trial reviewed in the original FDA approval document for Zyclara® (GW01-0702) had 227 patients complete the study.[24] Severe adverse events reported in patients applying the 3.75% cream included: cerebrovascular accident, gout, and atrial fibrillation. Severe adverse events reported in patients applying the 2.5% cream included: oral herpes, sinusitis, pneumonia, application site infection, bacterial pneumonia, application site irritation, pruritic rash, procedural pain, and cartilage injury. The second clinical trial (GW01-704) reported the following severe adverse events in patients applying the 3.75% cream: influenza-like illness, chest pain, diarrhea, vascular graft, and anxiety. Severe adverse events reported in patients applying the 2.75% cream included: bronchiectasis, influenza-like illness twice, cheilitis, lymphadenopathy twice, angina pectoris, atrial fibrillation, and arteriosclerosis.

Serious Adverse events reported across trials (n=160) of adult patients (mean age 64.4) applying Zyclara® 2.5% cream for 2 weeks included: atrial fibrillation (1), chest pain (1), pneumonia (2), acute myocardial infarction (1), non-cardiac chest pain (1), and ventricular tachycardia (1).[24] Events reported in adult patients (n=160) applying Zyclara® 3.75% cream for 2 weeks included: cerebrovascular accident (1), atrial fibrillation (1), small intestine obstruction (1), chest pain (1), anxiety (1), and diarrhea (1).

Serious Adverse events reported across trials (n=160) of adult patients (mean age 64.7) applying Zyclara® 2.5% cream for 3 weeks included: chest pain (1), pneumonia (1), aortic valve stenosis (1), syncope (1), and bronchitis (1).[24] Events reported in adult patients (n=160) applying Zyclara® 3.75% cream for 3 weeks included: pneumonia (1), breast cancer (1), surgery (1), dyspnea (1), hip fracture (1), arthralgia (1), wound infection (1), coronary artery disease (1), Non Hodgkin lymphoma (1), and pancytopenia (1).
An additional database review of Zyclara® (n=779) across two clinical trials revealed the following severe adverse events (see table 7).[25]

Table H-7: Severe Adverse Events Reported in Patients Applying Zyclara®

	Zyclara® 3.75% (n=400)	Zyclara® 2.5% (n=379)
Application site pain	6 (1.5%)	5 (1.3%)
Application site irritation	2 (0.5%)	3 (0.8%)
Application site reaction	1 (0.3%)	3 (0.8%)
Application site pruritus	1 (0.3%)	2 (0.5%)
Application site rash	2 (0.5%)	0
Application site dermatitis	0	1 (0.3%)
Application site erythema	0	1 (0.3%)
Application site ulcer	0	1 (0.3%)
Application site vesicles	1 (0.3%)	0
Chest pain	1 (0.3%)	0
Influenza like illness	1 (0.3%)	0
Pelvic mass	1 (0.3%)	0
Infections and infestation	3 (0.8%)	3 (1.1%)
Nasopharyngitis	1 (0.3%)	1 (0.3%)
Application site infection	0	1 (0.3%)
Bronchitis	0	1 (0.3%)
Influenza	1 (0.3%)	0
Pharyngitis streptococcal	0	1 (0.3%)
Vaginal infection	1 (0.3%)	0
Gastrointestinal disorders	3 (0.8%)	2 (0.5%)
Acute abdomen	1 (0.3%)	0
Diarrhea	0	1 (0.3%)
Haemorrhoidal haemorrhage	1 (0.3%)	0
Haemorrhoids	0	1 (0.3%)
Proctalgia	1 (0.3%)	0
Reproductive system and breast disorders	4 (1.0%)	2 (0.5%)
Scrotal erythema	2 (0.5%)	1 (0.3%)
Dysmenorrhea	2 (0.5%)	0
Vulval ulceration	0	1 (0.3%)
Injury, poisoning and procedural complications	1 (0.3%)	1 (0.3%)
Gunshot wound	1 (0.3%)	0
Upper limb fracture	0	1 (0.3%)
Musculoskeletal and connective tissue disorders	0	1 (0.3%)
Groin pain	0	1 (0.3%)
Nervous system disorders	1 (0.3%)	1 (0.3%)
Headache	1 (0.3%)	0
Migraine	0	1 (0.3%)
Respiratory, thoracic and mediastinal disorders	1 (0.3%)	0
Dyspnea	1 (0.3%)	0
Iron deficiency anemia	0	1 (0.3%)
Tooth extraction	1 (0.3)	0

Discontinuations

Patients utilizing Aldara® for actinic keratosis withdrew from studies or initialed rest periods most often due to application site reactions and local skin reactions.[13] Specifically, 2% (5/215) of patients discontinued from clinical trials due to local skin/application site reactions. Rest periods occurred in 16% (35/215), 11% (17/160), and 7% (11/160) of patients using Aldara®, Zyclara® 3.75% and Zyclara® 2.5% cream respectively.[12,13] Four out of 327 (1.2%) patients applying Aldara® and 3 out of 400 (1%) patients applying Zyclara® for genital warts reported discontinuing due to local skin/application reactions.[12,13] Thirty-two percent (126/400) of patients taking Zyclara® temporarily discontinued treatment due to local skin reactions.[12]

Aldara® was studied in male and female patients (n=784) aged 15-77 (mean age 31.5) with genital warts. Patients applied Aldara® three times a week for 16 weeks.[25] Some patients were treated for up to 32 weeks if their warts were not cleared after the initial 16 weeks. Patients discontinued due to the following adverse events: intolerable local skin reactions: burning, tenderness, itching, pain (31); flu-like symptoms (2); fatigue (1); bacterial infection at the wart site (1); urethral irritation (1); and intraepithelial vulvar neoplasia (1). In a similar study of male and female patients (n=943) age 16-78 (mean 31.2) with genital warts, 105 patients discontinued due to an adverse event including: local site reaction: burning, tenderness, itching, and pain (89); flu-like symptoms (8); headache, chills and fever (3); worsening of psoriasis (1); generalized itching (1); diarrhea (1); vaginal candidiasis (1); and fatigue (1).

Out of the 227 patients applying Zyclara® and completed the GW01-0702 trial, two withdrew from the treatment due to safety reasons: tachycardia, chest pain, hypertension, and increased tremors.[24]

Postmarking Adverse Events

Additional adverse events identified after Aldara® and Zyclara® were brought to the market include: tingling at the application site, angioedema, capillary leak syndrome, cardiac failure, cardiomyopathy, pulmonary edema, arrhythmias (tachycardia, atrial fibrillation, palpitations), chest pain, ischemia, myocardial infarction, syncope, thyroiditis, abdominal pain, decreases in red cell, white cell and platelet counts (including idiopathic thrombocytopenic purpura), lymphoma, abnormal liver function, herpes simplex, arthralgia, agitation, cerebrovascular accident, convulsions (including febrile convulsions), depression, insomnia, multiple sclerosis aggravation, paresis, suicide, dyspnea, proteinuria, dysuria, urinary retention, exfoliative dermatitis, erythema multiforme, hyper/hypo pigmentation, hypertrophic scar, and Henoch-Schönlein purpura syndrome.[12,13] Post-marketing data was gathered by the sponsor in 2004 and was included in the Zyclara® original FDA approval document.[24] Adverse reported include: chest pain (2), angina (1), myocardial infarction (1), tachycardia (2), syncope (2), palpitation (1), sudden death (1) (potentially due to arrhythmia), atrial fibrillation (1).

Tenormin® (atenolol)

Tenormin® is not FDA approved for use in pediatric patients and therefore safety data in this population is not available.[14] The adverse event data provided below was gathered from the Tenormin® package insert and is specific for adult hypertensive patients. Adverse events specific for patients using this medication for acute myocardial infarction was not included in this analysis.

Controlled studies in conducted in the United States and in unspecified foreign countries revealed the following adverse events associated with atenolol (n=399): bradycardia (3%), cold extremities (12%), postural hypotension (4%), leg pain (3%), dizziness (13%), vertigo (2%),

light-headedness (3%), tiredness (26%); fatigue (6%), lethargy (3%), drowsiness (2%), depression (12%); dreaming (3%), diarrhea (3%), nausea (3%), wheeziness (3%), and dyspnea (6%).[14]

Adverse events reported for beta-adrengeric blocking agents in general include: agranulocytosis; fever, combined with aching and sore throat, laryngospasm, and respiratory distress; reversible mental depression progressing to catatonia; acute reversible syndrome characterized by disorientation of time and place; short-term memory loss; emotional lability with slightly clouded sensorium; decreased performance on neuropsychometrics; mesenteric arterial thrombosis, ischemic colitis, erythematous rash; skin rashes and/or dry eyes.[14]

Post-marketing Adverse Events

Additional adverse events revealed during post-marketing surveillance include: dry mouth, headache, elevated liver enzymes and/or bilirubin, hallucinations, impotence, purpura, reversible alopecia, Peyronie's disease, postural hypotension which may be associated with syncope, psoriasiform rash or exacerbation of psoriasis, psychoses, thrombocytopenia, visual disturbance, sick sinus syndrome, development of antinuclear antibodies (ANA), lupus syndrome, and Raynaud's phenomenon.[14]

Timoptic® (timolol maleate), Timoptic-XE® (timolol maleate), Betimol® (timolol)

Timoptic®, Timoptic-XE®, and Betimol® are not FDA approved for use in pediatric patients and therefore safety data in this population is not available.[15-17] The adverse event data provided below is gathered from the package inserts for these medications and is specific for adult patients. These medications are ophthalmic preparations and therefore many of the common adverse events are associated with the ophthalmic route of administration. One in eight patients reported stinging and burning after administration of all three of these medications.[15-17]

In patients taking Timoptic-XE®, one in three patients, in clinical trials, experienced blurred vision upon drop administration lasting 30 seconds to 5 minutes.[16] One in eight patients reported stinging and burning after use. Additional adverse events reported in 1-5% of patients included: pain, conjunctivitis, discharge (e.g., crusting), foreign body sensation, itching and tearing, headache, dizziness, and upper respiratory infections.

In patients taking Betimol® 0.25% or 0.5%, adverse events that occurred more than 5% in two controlled clinical studies (n=184 patients) included: dry eyes, itching, foreign body sensation, discomfort in the eye, eyelid erythema, conjunctival injection, and headache.[17] Adverse events occurring at a frequency of 1-5% included: eye pain, epiphora, photophobia, blurred or abnormal vision, corneal fluorescein staining, keratitis, blepharitis and cataract, allergic reaction, asthenia, common cold and pain in extremities, hypertension, nausea, peripheral edema, dizziness, dry mouth, respiratory infection and sinusitis. Additional adverse events reported in ophthalmic use of beta-blockers include: blepharoptosis, retinal vascular disorder, bronchospasm.

The following adverse events were reported in the package inserts of both Timpotic® and Timoptic-XE®: headache; asthenia/fatigue; arrhythmia; hypertension; worsening of angina pectoris; pulmonary edema; edema; claudication; Raynaud's phenomenon; cold hands and feet; nausea; dyspepsia; anorexia; dry mouth; systemic lupus erythematosus; dizziness; somnolence; insomnia; nightmares; behavioral changes and psychic disturbances including confusion, hallucinations, anxiety, disorientation, nervousness, and memory loss; alopecia and psoriasiform rash or exacerbation of psoriasis; signs and symptoms of systemic allergic reactions, including anaphylaxis, and angioedema; cough and upper respiratory infections; signs and symptoms of

ocular irritation including blepharitis, keratitis, ocular pain, discharge (e.g., crusting), foreign body sensation, itching and tearing, and dry eyes; ptosis; cystoid macular edema; visual disturbances including refractive changes and diplopia; pseudopemphigoid; choroidal detachment following filtration surgery; tinnitus; retroperitoneal fibrosis; decreased libido; and Peyronie's disease.[15,16]

Adverse events reported for Betimol®, Timpotic®, Timoptic-XE® included: conjunctivitis, decreased corneal sensitivity, visual disturbances including refractive changes and diplopia, chest pain, arrhythmia, palpitation, bradycardia, hypotension, syncope, heart block, cerebral vascular accident, cerebral ischemia, cardiac failure, cardiac arrest, masked symptoms of hypoglycemia in diabetic patients, diarrhea, depression, impotence, increase in signs and symptoms of myasthenia gravis and paresthesia, dyspnea, bronchospasm (predominantly in patients with preexisting bronchospastic disease), respiratory failure, nasal congestion; alopecia, urticaria, and localized/generalized rash.[15-17]

Adverse events reported for oral timolol and oral beta-blocking agents that could be considered potential adverse events for ophthalmic timolol include: erythematous rash; fever combined with aching and sore throat; laryngospasm with respiratory distress; extremity pain; decreased exercise tolerance; weight loss; worsening of arterial insufficiency; vasodilatation; gastrointestinal pain; hepatomegaly; vomiting; mesenteric arterial thrombosis; ischemic colitis; nonthrombocytopenic purpura; thrombocytopenic purpura; agranulocytosis; hyperglycemia; hypoglycemia; pruritus; skin irritation; increased pigmentation; sweating; arthralgia; vertigo; local weakness; diminished concentration; reversible mental depression progressing to catatonia; an acute reversible syndrome characterized by disorientation for time and place; emotional lability; slightly clouded sensorium; and decreased performance on neuropsychometrics; rales; bronchial obstruction; urination difficulties.[15,16]

References:

1. Hemangeol [package insert]. Parsippany, NJ: Pierre Fabre Pharmaceuticals, Inc.; March 2014.
2. Flo-Pred [package insert]. Hawthorne, NY: Taro Pharmaceuticals U.S.A., Inc.; June 2011.
3. Orapred ODT [package insert]. Bridgetown, Barbados: Concordia Pharmaceuticals Inc.; July 2013.
4. Rayos [package insert]. Deerfield, IL: Horizon Pharma Inc.; February 2014.
5. Medrol [package insert]. New York, NY: Pharmacia and Upjohn Company; June 2013.
6. Depo-Medrol [package insert]. New York, NY: Pharmacia and Upjohn Co.; July 2014.
7. Solu-Medrol [package insert]. New York, NY: Pharmacia & Upjohn Co.; July 2014.
8. Aristospan [package insert]. Princeton, NJ: Sandoz Inc; April 2014.
9. Kenalog-10 [package insert]. Princeton, NJ: Bristol-Myers Squibb Company; July 2014.
10. Celestone Soluspan [package insert]. Whitehouse Station, NJ: Merck Sharp Dohme; February 2015.
11. Elocon [package insert]. Whitehouse Station, NJ: Merck Sharp & Dohme Corp; 2012.
12. Zyclara [package insert]. Bridgewater, NJ: Valeant Pharmaceuticals North America LLC; August 2014.
13. Aldara [package insert]. Bridgewater, NJ: Valeant Pharmaceuticals North America LLC; August 2014.
14. Tenormin [package insert]. Wilmington, DE: AstraZeneca Pharmaceuticals LP; October 2012.
15. Timoptic [package insert]. Lawrenceville, NJ: Aton Pharma; May 2009.
16. Timoptic-XE [package insert]. Lawrenceville, NJ: Aton Pharma; May 2009.
17. Betimol [package insert]. Lake Forest, IL: Oak Pharmaceutical; February 2014.
18. Propranolol Hydrochloride Solution [package insert]. Columbus, OH: Roxane Laboratories, Inc; January 2012.
19. Inderal LA [package insert]. Cranford, NJ: Akrimax Pharmaceuticals, LLC; June 2012.
20. Propranolol Hydrochloride Tablet [package insert]. Eatontown, NJ: Heritage Pharmaceuticals Inc.; September 2013.
21. Flo-Pred Medical Review - Original Approval. Silver Spring, MD: Food and Drug Administration Center for Drug Evaluation and Research; 2008.
22. Orapred ODT Medical Review - Original Approval. Silver Spring, MD: Food and Drug Administration Center for Drug Evaluation and Research; 2006.
23. Rayos Medical Review - Original Approval. Silver Spring, MD: Food and Drug Administration Center for Drug Evaluation and Research; 2012.
24. Zyclara Medical Review - Original Approval. Silver Spring, MD: Food and Drug Administration Center for Drug Evaluation and Research; 2010.
25. Zyclara Medical Review - Original Approval. Silver Spring, MD: Food and Drug Administration Center for Drug Evaluation and Research; 2011