Appendix A. Search Strategy

1. exp Magnetic Resonance Imaging/
2. ("Magnetic Resonance Imaging" or "MRI").tw.
3. 1 or 2
4. ("dynamic" or "vertical" or "upright" or "stand*" or "seat*" or "open" or "position*" or "weight bearing").tw. or (("axial$" and "load$") or ("extremity specific" or "dedicated")).tw.
5. 3 and 4
6. limit 5 to yr="1975 -Current"
7. limit 6 to (english language and humans)
8. exp "sensitivity and specificity"/
9. exp Predictive Value of Tests/
10. exp ROC CURVE/
11. exp Mass Screening/
12. exp diagnosis/
13. exp REPRODUCIBILITY OF RESULTS/
14. exp false negative reactions/ or false positive reactions/
15. predictive value.tw.
16. (sensitivity or specificity).tw.
17. accuracy.tw.
18. screen$.tw.
19. diagno$.tw.
20. roc.tw.
21. reproducib$.tw.
22. (false positive or false negative).tw.
23. likelihood ratio.tw.
24. di.fs.
25. or/8-24
26. (cf or bl or ra or ri or us or en).fs.
27. 25 or 26
28. 7 and 27
29. limit 28 to (addresses or bibliography or biography or case reports or comment or dictionary or directory or duplicate publication or editorial or guideline or in vitro or interview or lectures or legal cases or letter or news or newspaper article or "review")
30. 28 not 29
31. exp Cervical Vertebrae/
32. ("cervical myelopathy" or "cervical spine" or "cervical spondylotic myelopathy" or "Dural sac" or "Facet" or "Herniation" or "instability" or "intervertebral disc").tw.
33. exp Intervertebral Disk Displacement/
34. exp Intervertebral Disk/
35. ("kyphosis" or "lordosis" or "low* back").tw.
36. exp Low Back Pain/
37. ("lumbar" or "lumbar stenosis").tw.
38. exp Lumbar Vertebrae/
39. exp Neck Pain/
40. exp Neck/
41. ("neck" or "radicul*").tw.
42. exp Radiculopathy/
43. exp Sciatica/
44. sciatica.tw.
45. (scoliosis or spinal).tw.
46. exp Spinal Curvatures/
47. spinal osteophytosis/ or spinal stenosis/ or spondylolisthesis/ or thoracic vertebrae/ or whiplash injuries/
48. ("spinal stenosis" or "spine" or "spondylolisthesis" or "spondylosis").tw.
49. exp Joints/
50. ("foot" or "feet" or "knee*" or "hip$" or "TMJ" or "temporomandibular" or "shoulder*" or "elbow" or "wrist*" or "hand$").tw.
51. or/31-50
54. 30 and 51

Appendix B. Data Extraction Form

Data Extraction Form -- Positional MRI Technical Brief

Note: enter "-9 or -99" if no numeric data available; enter "nd" if no text data available

<IDNUM>
Extractor. ____
Author. (last name of the first author)
_____
Year. ####
UI. ######### [Can be found in excel tracking sheet]

Reject. <Y> [Please make sure article fit our inclusion criteria BEFORE extraction]
rejectreason. _____
[Rejection reason]

Comments1.
_____
Comments2.
_____
Comments3.
_____
Comments4.
_____

Where was this study conducted?
US. US <Y>
NonUS. non-US <Y>

funding. Was funding source of the study reported? <Y> If no, skip the following question.

industryfund. Was any part of study funded by device industry? <Y>

Study Population?
StudyPop1. Suspected degenerative spondylolisthesis <Y>
StudyPop2. Suspected spinal stenosis: moderate or severe central stenosis <Y>
and lateral recess stenosis (displacing or compressing nerve root, disc extrusion)
StudyPop3. Radicular pain: moderate or severe central stenosis, lateral recess stenosis, <Y>
nerve root compression, and disc extrusion
StudyPop4. Non-specific spine pain: moderate or severe central stenosis, <Y>
lateral recess stenosis, nerve root compression, and disc extrusion
StudyPop5. Extra-spinal joint pain or function loss: e.g. narrowing <Y>
or musculoskeletal only
StudyPop6. Healthy volunteer <Y>
if other, described:
StudyPopOther.
_____

Study population that may introduce bias (e.g. subject excluded based on: incomplete test results,
incomplete data, test unclear) describe reasons,
Populationbias1.
_____
Populationbias2.
_____

Populationbias3.
_____
Populationbias4.
_____

Study Design (Based on Dx test study purpose. Note that it may dffer from original study design.)
RCT. parallel <Y>
NRCS. [Non Randomized Comparative Study] <Y>
Crossover. <Y>
CaseControl. <Y>
Longitudinal. <Y>
Crosssectional. <Y>
NoData. <Y>

FollowUPNA. Study design applicable for follow-up? <Y> [Note: cross-sectional and case-control design are not applicable for follow-up in Dx Test setting]
If yes, please enter the follow-up duration:
FollowUP. ### weeks - [calculation: (number of months * 30) / 7]

ProsandRetros. ##
1) Prospective
2) Retrospective
3) Not Applicable (eg. cross-sectional or case-control)
-9) No data

Multicenter?. ##
1) Multicenter
2) Single center
-9) No data

Classification. [select one of these criteria] ##
1)Feasibility (no comparator - a group of patients get just one test)
2)Screening (use of the test to identify disease in the absence of clinical symptoms)
3) Diagnosis (use of the test to determine the presence and type of structural or functional abnormalities in the presence of clinical symptoms)
4) Prognosis/prediction (use of the test to predict response to treatment or natural course of the disease)
5) Patient management / treatment plan (use of the test to determine the management plan, including selection of treatment)
6) Monitoring (assessing response to treatment or relapse after therapy)
7) if unclear or multi-classifications were selected (please separate the selections with comma), describe:
ClassificationOther.
_____

ExamLocation. reported (Joint or body part)? <Y>
Cervical. <Y>
Thoracic. <Y>
Lumbar. <Y>
Pelvic. (Coccyx or Sacral) <Y>
Knee. <Y>
Lowerextremities. (other than knees) <Y>
Upperextremities. <Y>
ExamLocOther. [other exam location] <Y> ExamLocSpec. [specify other exam location] _____

Adverse Events
AEreported.-- Are Adverse Events related to the test reported? <Y>
if YES specify:
AE1.
_____
AE2.
_____
AE3.
_____
AE4.
_____

Outcomes
Outcomes. ##
1) Diagnostic test performance (e.g., sensitivity and specificity, or accuracy), if selected please describe what was the "reference standard" used below:
RefStd.
_____
[Note: a "reference standard" is what investigator considered to be the reference for a diagnosis
2) Impact on diagnostic thinking
3) Impact on treatment decisions
4) Impact on patients' clinical and functional outcomes
5) Patient's preference
6) If unclear or multi-outcomes were selected (please separate the selections with comma), describe:
OutcomeUnclear.
_____

Except for feasibility studies, please describe briefly the comparisons (e.g. weight-bearing vs. not weight-bearing position in Upright MRI,
Upright MRI vs. axial loading in conventional MRI, ranges of motion before and after surgery evaluated by Upright MRI in weight-bearing position):
comparison1:
_____
comparison2:
_____
comparison3:
_____
comparison4:
_____

==========The following section is for population characteriteristics==========
!!INSTRUCTION: If case-control study, enter cases' characterisitics here in this section. The controls' characterisitics should be entered
in a duplicate section at the end of this data extraction form. For all other designs, enter the characteristics for TOTAL population here.

Male. (%) ###

Agemean. Mean age (yr) ###.# AgemeanSD. Age Mean SD ##.# [to convert SE to SD use the following formula:
SE=SD divided by sqaure root of N]

Agemedian. Median age (yr) ###

Agerangefrom. ### Agerangeto. ### [age range]

weightinfo. Were weight or BMI data reported? <Y>

if yes, please describe (report the mean BMI or just a description such as "obese" patients"
obese.
_____

RaceReported. Was race/ethnicity of study population reported? <Y>
Hispanic. (%) ###
Caucasian. (%) ###
AfricanAmerican. (%) ###
Asian. (%) ###
NativeAmerican. (%) ###
Other. (%) ###
NKRefused. (%) ### [Don't know or refused]

PatientSymptoms. ## [Patient Symptoms Asymptomatic and Symptomatic as reported by the study author]
1) Asymptomatic.
2) Symptomatic.
3) BothSymp. [Note: if 'both symptoms' was selected, please report propration of symptomatic subjects (%) below)
SymptomProportion. ##
-9) Nodata.

NEnrolled. ###### [Number of subjects enrolled]

AnalyzedSubjects. ###### AnalyzedLesion. ###### [Note: please report the number of subject/lesion at the last time point]

EnrollStartDate. (mm/yyyy) _____ EnrollEndDate. (mm/yyyy) _____ [Note: enter "nd" if no data]

==========The following section is for test characteriteristics==========
!!IMPORTANT: Tests includes non-imaging tests, such as clinical examination or other chemical testing. Studies MUST have positional MRI test to be included.

CompareTests. Was the study comparing two Dx tests? <Y> [Definition: A study where diagnostic classification is
obtained using at least two different tests (one of which fulfils the definition of "weight bearing positional MRI") in the same physiological condition]
[Note: In this data extraction form, we are only collecting brief characteristis of positional MRI.
If a true comparative study, detailed technical specifications of the tests will be collected in a separate form.]

Following questions are positional MRI (i.e., weight bearing or simulating weight bearing MRI)

pMRIName. _____ [Note: name verbatim as reported by the researchers]

pMRIManufacture. _____ [Note: enter "nd" if no data]

pMRIdevicemodel. _____ [Note: enter "nd" if no data]

pMRIMagneticStrength. [Magnetic Field Strength] ##.# (T)

pMRIT1coil. [Coil used]
_____
[Note: verbatim as reported by the researchers]

pMRI Position
pMRIstanding. <Y> (if YES specify: e=extension, f=flexion, n=neutral, r=rotation)
pMRIstandingSpec. _____ (Note: please separate the selections with a comma)
pMRISitting. <Y> (if YES specify: e=extension, f=flexion, n=neutral, r=rotation)
pMRISittingSpec. _____ (Note: please separate the selections with a comma)

pMRIAxialLoad. [Axial load] <Y> If yes, please describe the axial loading device below:
ALname.
_____
[Note: name and manufactor. If custom made device,
please verbatim as reported by the researchers]
ALforce. [Force of axial load]
_____
[Note: usually reported as % body weight]

pMRIlength. [length of exam] #### Minutes

pMRIcomment1.
_____
[Comments on positional MRI test]
pMRIcomment2.
_____
[Comments on positional MRI test]

==========The following section is for controls' characteriteristics in case-control study ==========
!!INSTRUCTION: Only use this section to enter controls' characterisitics For all other designs, do not use this section.

ctrl. What was the control population?
_____

ctrlselect. How was the controls selected?
_____ [Note: enter "nd" if no data]

ctrlMale. (%) ### [for total population]

ctrlAgemean. Mean age (yr) ###.# ctrlAgemeanSD. Age Mean SD ##.# [to convert SE to SD use the following formula:
SD=SE divided by sqaure root of N]

ctrlAgemedian. Median age (yr) ###

ctrlAgerangefrom. ### ctrlAgerangeto. ### [controls' age range]

ctrlweightinfo. Were weight or BMI data reported? <Y>
if yes, please describe (report the mean BMI or just a description such as "obese" patients"
ctrlobese.
_____

ctrlRaceReported. Was race/ethnicity of study population reported? <Y>
ctrlHispanic. (%) ### [Hispanic]
ctrlCaucasian. (%) ### [Caucasian]

ctrlAfricanAmerican. (%) ### [AfricanAmerican]
ctrlAsian. (%) ### [Asian]
ctrlNativeAmerican. (%) ### [NativeAmerican]
ctrlOther. (%) ### [Other race/ethnicity]
ctrlNKRefused. (%) ### [Don't know or refused]

ctrlPatientSymptoms. ## [Symptoms Asymptomatic and Symptomatic as reported by the study author]
1) Asymptomatic.
2) Symptomatic.
3) BothSymp. [Note: if 'both symptoms' was selected, please report propration of symptomatic subjects (%) below)
ctrlSymptomProportion. ##
-9) Nodata.

ctrlNEnrolled. ###### [Number of controls enrolled]

ctrlAnalyzedSubjects. ###### ctrlAnalyzedLesion. ###### [Note: please report the number of subject/lesion at the last time point]

ctrlEnrollStartDate. (mm/yyyy) _____ ctrlEnrollEndDate. (mm/yyyy) _____ [Note: enter "nd" if no data]

Appendix C. Examples of commercially available devices that allow MRI under weight-bearing or stress loading conditions

Please note that we are currently working to obtain permission for use of pictures in the final report

a. Upright® MRI

Legends: The FONAR Upright mutli-positional MRI allows positional (flexion, extension), weight bearing (upright and sitting) imaging and has an open configuration (the patient does not enter a closed bore). The FONAR Upright MRI has a 0.6 T horizontal field generated between two resistive magnets. A tilting table placed at right angles between these coils can be positioned at any angle from -20 to 90 degree (vertical), allowing supine and standing imaging. An MRI compatible seat can be added in the upright position. Extension is achieved by positioning of a small cylindrical cushion just above the lumbrosarcal junction. Flexion is achieved by leaning forward over a wedge-shaped cushion and supporting the hands on a horizontal bar.

b. Signa SP/I

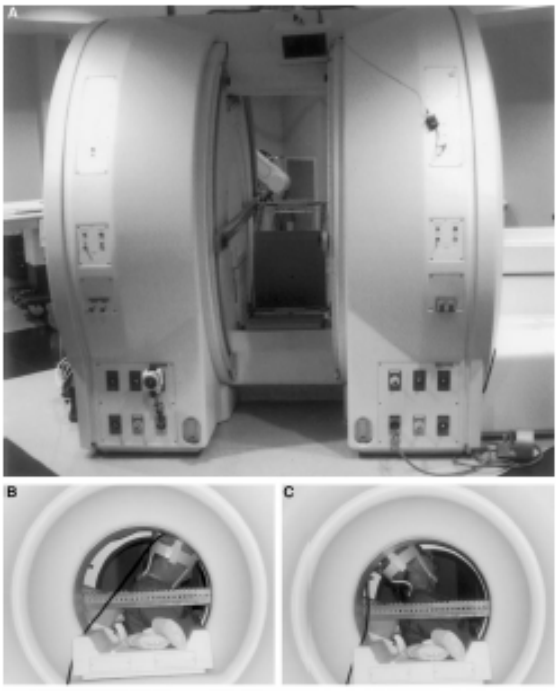

from Vitaz, 2004 (UI: 15180020)

Legends: The Signa SP/i system was originally indented for use in interventional procedures as it allowed physician access to the patient while in the MRI field. The MRI system is characterized by two vertically oriented, doughnut-shaped superconducting magnetic coils. Several investigators have modified the scanner to allow imaging of the patient in different positions (flexion, extension), weight bearing (upright, sitting, or in other weight-bearing positions) and (because of the 56 cm vertical gap between the two magnet poles) can also be considered an open system.

c. G-scan®

Legends: G-Scan (Esaote SpA, Genoa, Italy) has an open and tilting design and can perform scan in the supine position and in the upright weight-bearing position. Another unique feature is “Instant positioning”. Once the patient has been positioned on the table, just press the button of the joint under investigation which automatically moves the patient and coil in the isocenter.

d. DynaWell L-spine

Legends: DynaWell L-spine device consists of a harness attached to a nonmagnetic compression part by nylon straps which are tightened to axially load the lumbar spine. By tightening or loosening the adjustment knobs on the foot plates, the load can be regulated and equally distributed on the legs.

e. MSK Extreme

Legends: The ONI MSK Extreme 1.0T or 1.5T system is semi-open MR system dedicated to imaging cartilage and soft tissue of the extremities (hand, wrist, elbow, foot, ankle and knee).

Appendix D. Shared authorship patterns in studies of weight-bearing or stress-loading MRI

Below figure demonstrates that a total of 55 publications (reporting on 56 studies) were conducted by 32 teams of investigators. One team that has published 6 manuscripts, corresponding to approximately 11% of all studies we considered eligible includes as co-authors Drs. Danielson and Willen, inventors of the DynaWell axial loading device (Drs. Danielson and Willen are identified as inventors of the device on the company's website).[i] We caution that our graph does not necessarily imply overlap of patient populations, and should rather be regarded as a method to identify the most active research groups in the field.

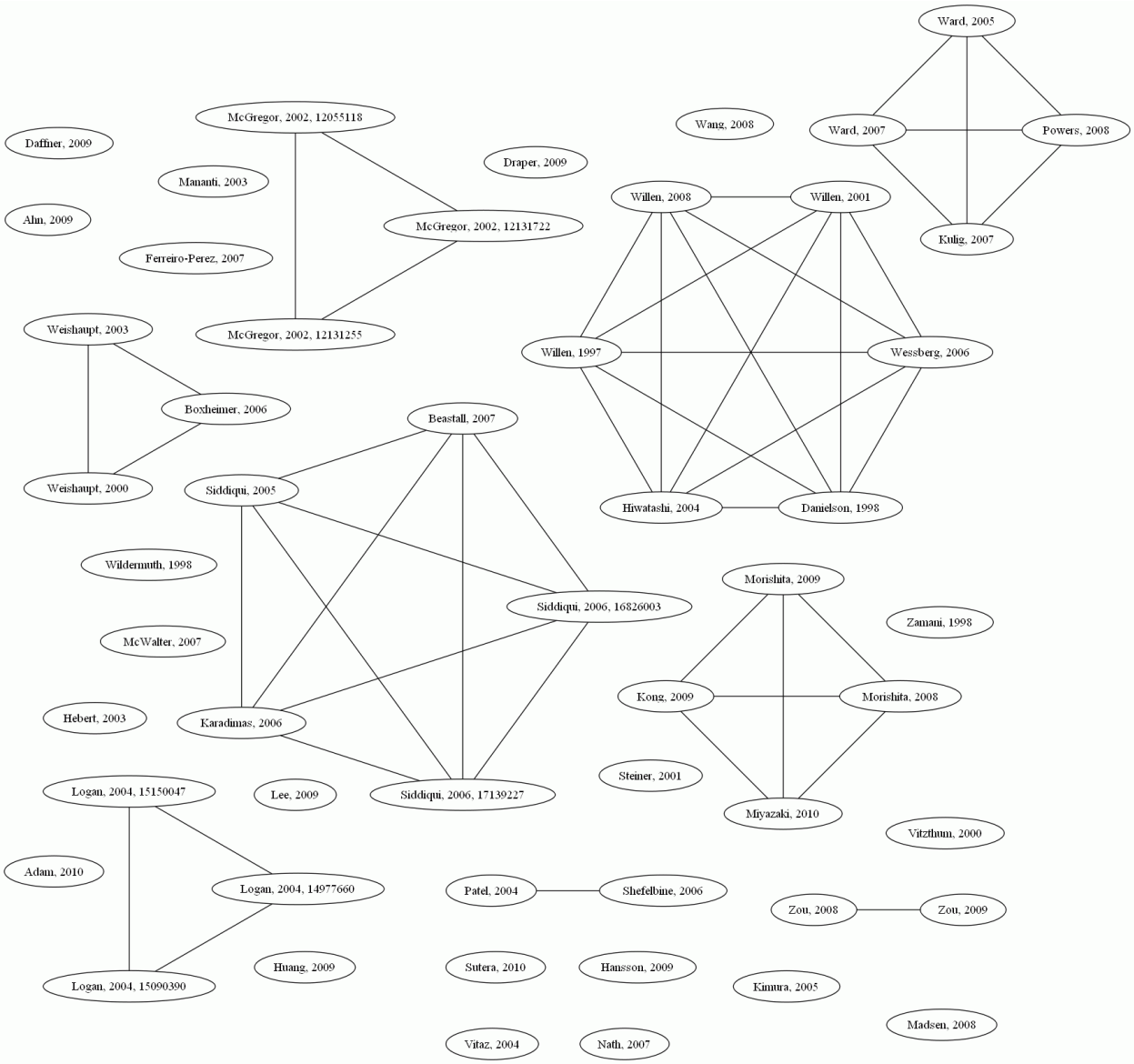

Overlap between author lists in included studies. Each publication is represented by an ellipse. Studies sharing at least one author are depicted as a group of ellipses linked amongst themselves with lines. Refer to the Methods Section for a description of how the graph was generated.

[i] DynaWell Diagnostics. DynaWell(R). http://www.dynawell.biz

Appendix E. Studies used dedicated extremity MRI devices in patients with musculoskeletal disorders

Author, year (Country) [PMID] Study Design	N enrolled	Patient population	Setting	E-MRI [Manufacture] (Field strength)	Comparison	MR Imaging location	Outcome (assessment)
Rheumatoid arthritis							
Xie, 2008[1] (Canada) [19032820] Case-control	39	Cases: RA	Cases: rheumatology clinics	OrthOne [ONI Medical Systems] (1.0T)	Cases vs. controls	MCP joints; wrist	Synovitis, bone edema, bone erosion (OMERACT RAMRIS scoring)
	41	Controls: no joint disease	Controls: community				
Savnik, 2001[2] (Denmark) [11419149] Cross-sectional	103	RA	NR	Artoscan [Esaote Biomedica, Genoa, Italy] (0.2T)	High-field MRI - Gyroscan ACS-NT [Philips, Best, Netherlands] (1.5T)	Wrist; MCP and IP joints	Synovial membrane volume, joint enhancement, joint effusion, bone edema, bone erosions (visual analysis)
Yoshioka, 2006[3] (Japan) [16456819] Case-control	13	Cases: Suspected early RA, RA; soft-tissue swelling	NR	Compact MRI [originally developed by investigators] (0.21T)	Cases vs. controls Among cases only, also comparison to plain radiographs	Hand; wrist	Radiologists' routine reading
	13	Controls: no clinical symptom of arthritis					
Jagodzinski, 2000[4] (Germany) [10663314] Cross-sectional	10[b]	Patients with ACL injuries who are able to hyperextend the uninjured knee.	NR	Artoscan [Esaote Biomedica, Genoa, Italy] (0.18T)	None.	Knee	Only anatomic measurements
Duer-Jensen, 2008[5]	15	Cases: RA	Single academic hospital	2 E-MRI scanners were	Plain radiographs. The Artoscan E-MRI	Hand ; wrist	Synovitis, bone edema, bone erosion

Author, year (Country) [PMID] Study Design	N enrolled	Patient population	Setting	E-MRI [Manufacture] (Field strength)	Comparison	MR Imaging location	Outcome (assessment)
(Denmark) [17984195] Case-control	4	Controls: healthy individuals with no signs or symptoms of joint disease		used: Artoscan [Esaote Biomedica, Genoa, Italy] (0.2T) MagneVu MV1000 [MagneVu, Carlsbad, CA] (0.2T)	results where considered as the gold standard and the MagneVu E-MRI and plain radiographs were treated as index tests to calculate diagnostic accuracy.		(OMERACT RAMRIS scoring)
Cimmino, 2003[6] (Italy) [12746893] Case-control	36	Patients: RA	10 outpatients in remission (per ACR criteria) and 26 patients with clinical involvement of at least one wrist either hospitalized in a university rheumatology clinic or as outpatients.	Artoscan [Esaote Biomedica, Genoa, Italy] (0.2T)	RA patients were classified into 3 three groups based on disease severity. Imaging findings between the 3 disease groups and the controls were compared. Imaging parameters were also correlated with clinical outcomes and laboratory measurements.	Wrist	Association of imaging parameters with disease presence and severity. Correlation of imaging parameters with clinical and laboratory measurements. (clinical and laboratory findings were masked during image processing)
	5	Controls: healthy volunteers					
Cimmino, 2005[7] (Italy) [15987474]	15	Cases: Psoriatic arthritis	Single academic rheumatology clinic, both inpatient wards and outpatient	Artoscan [Esaote Biomedica, Genoa, Italy] (0.2T)	Imaging findings between the 3 disease groups and the controls were compared.	Wrist	Association of imaging parameters with disease presence. Correlation of imaging parameters with clinical and laboratory
	49	Cases: RA, “consecutive”					

Author, year (Country) [PMID] Study Design	N enrolled	Patient population	Setting	E-MRI [Manufacture] (Field strength)	Comparison	MR Imaging location	Outcome (assessment)
Case-control	30	Cases: RA, matched for age, disease duration and number of involved joints with the psoriatic arthritis group (9 patients overlapped with the group of consecutive RA patients)	clinics		Imaging parameters were also correlated with clinical outcomes and laboratory measurements.		measurements. (Image assessment was performed blind to the clinical and laboratory findings)
	8	Controls					
Duer-Jensen, 2009[8] (Denmark) [18718987] Case-control	20 5	Cases: RA Controls: healthy individuals	NR	2 E-MRI scanners were used: Artoscan [Esaote Biomedica, Genoa, Italy] (0.2T) MagneVu MV1000 [MagneVu, Carlsbad, CA] (0.2T)	CT and plain radiographs All 4 tests were performed in cases and controls	Hand; wrist	Bone erosion detection (OMERACT RAMRIS scoring for MRI)
Ejbjerg, 2005[9] (Denmark) [15650012]	37	Cases: RA	Single academic hospital	Artoscan [Esaote Biomedica, Genoa, Italy] (0.2T)	High-field MRI -Impact [Siemens] (1.0T) and plain radiographs All tests were	Hand; wrist	Synovitis, bone edema, bone erosion (OMERACT RAMRIS

Author, year (Country) [PMID] Study Design	N enrolled	Patient population	Setting	E-MRI [Manufacture] (Field strength)	Comparison	MR Imaging location	Outcome (assessment)
Case-control	28	Controls: healthy individuals			performed on cases and controls; in 10 patients and 10 controls a preliminary study to determine the optimal imaging setting for the E-MRI was performed. Plain radiographs were only used for bone erosion detection.		definitions)
Freeston, 2007[10] (UK) [17666445] Cross-sectional	15	RA	NR	MagneVu MV1000 [MagneVu, Carlsbad, CA] (0.2T)	High-field MRI-Gyroscan ACS-NT [Philips, Best, Netherlands] (1.5T) and plain radiographs	Hand; wrist	Bone erosion detection (OMERACT definition of erosion)
Gaylis, 2007[11] (USA) [17694258] Retrospective longitudinal	48	Infliximab-treated RA	Single rheumatology practice	MagneVu 1000 [MagneVu, Carlsbad, CA] (0.2T)	Plain radiographs	Hand; wrist	Baseline bone erosion detection, monitoring of response to treatment (Two radiologists blinded to the patients' clinical status used a system to classify erosions as small, moderate or large. They also ascertained "regression" versus "stability" of the lesions)
Tajiri, 1999[12] (Japan) [10406343]	8	Cases: RA with symptomatic sublaxation of the distal ulna	NR	Artoscan [Esaote Biomedica, Genoa, Italy] (0.18T) using a	Cases vs. controls regarding motion during rotation	Distal radioulnar joint	Images were analyzed with regard to rotation, distance between radius and ulna, and range of

Author, year (Country) [PMID] Study Design	N enrolled	Patient population	Setting	E-MRI [Manufacture] (Field strength)	Comparison	MR Imaging location	Outcome (assessment)
Case-control	5	Controls: asymptomatic volunteers		custom-made positioning device to obtain scans of the upper extremity during rotation			motion.
Roemer, 2005[13] (USA) [15633060]	23	Suspected or proven osteoarthritis of the knee	Participants in the MOST epidemiological study	OrthOne [ONI Medical Systems, Wilmington, MA] (1.0T)	Different imaging sequences.	Knee	Grading of osteoarthritis (two musculoskeletal radiologists blinded to participant data read all MRI scans)
Schiff, 2007[14] (USA) [17519063] Cross-sectional	300[c]	Clinical diagnosis of RA	Single community-based rheumatology practice	MagneVu MV1000 [MagneVu, Carlsbad, CA] (0.2T)	Comparison of clinical and laboratory findings and treatment-related data (change in therapeutic regimen) between "MRI positive" and "negative" patients. Multivariate modeling to identify predictors of a "positive" MRI scan.	Hand; wrist; feet	Marrow edema, subhondral cysts, erosions, joint space narrowing (four radiologists interpreted the exams, each scan was reviewed by a single rater)
Segal, 2009[15] (USA) [19533741] Nested case-control	30	Cases: incident symptomatic knee osteoarthritis	Participants in the MOST epidemiological study	OrthOne [ONI Medical Systems, Wilmington, MA] (1.0T)[d]	Cases vs. controls (baseline MRI data were used to develop contact stress models to predict the development of incident osteoarthritis by 15 months of follow-up)	Knee	Prognosis of osteoarthritis development expressed as prognostic accuracy (computational stress analysis of the baseline MRI scan was used to predict the development of incident osteoarthritis)
	30	Controls: randomly selected individuals from the same cohort					

Author, year (Country) [PMID] Study Design	N enrolled	Patient population	Setting	E-MRI [Manufacture] (Field strength)	Comparison	MR Imaging location	Outcome (assessment)
Taouli, 2004[16] (USA) [15039167] Cross-sectional	18	RA	Single academic rheumatology center	Artoscan [Esaote Biomedica, Genoa, Italy] (0.2T)	High-field MRI-Signa [General Electric medical Systems] (1.5T) and plain radiographs. Scores based on the different imaging methods were compared as continuous measurements.	Hand; wrist	Bone erosions, joint-space narrowing and synovitis. (Two independent reviewers assigned Genant-modified Sharp radiographic scores based on plain radiographs. A modification of the system was used for MRI)
Lindegaard, 2001[17] (Denmark) [11454641] Case-control	25	Cases: RA	Single academic rheumatology clinic	Artoscan [Esaote Biomedica, Genoa, Italy] (0.2T)	Clinical examination and plain radiographs. Correlation of imaging scores with laboratory findings.	Hand; wrist	E-MRI: Detection of bone erosions (visual assessment), grading of synovitis (using a semi-quantitative system). Plain radiographs: presence and number of bony erosions (assessed by an independent investigator blinded to the clinical and E-MRI findings). Clinical exam: joint swelling and tenderness (assessed by a rheumatologist based on EULAR criteria).
	3	Controls: healthy individuals	Hospital staff				

Author, year (Country) [PMID] Study Design	N enrolled	Patient population	Setting	E-MRI [Manufacture] (Field strength)	Comparison	MR Imaging location	Outcome (assessment)
Lindegaard, 2006[18] (Denmark) [16540550] Longitudinal study[e]	24[f]	RA	Single academic clinic	Artoscan [Esaote Biomedica, Genoa, Italy] (0.2T)	Plain radiographs. Radiographs and E-MRI assessments were performed at baseline, 6 and 12 months to assess disease course and response to treatment. Findings were correlated with clinical and laboratory results.	Hand; wrist	Monitoring of response to treatment based on number of erosions, bone edema, tenosynovitis (For E-MRI: OMERACT scoring by a radiologist blinded to clinical and radiographic findings; for radiographs: Larsen scores and presence of bone erosions)
Eshed, 2006[19] (Germany) [16882591] Cross-sectional	38	RA	Single center rheumatology outpatient clinic	C-scan [Esaote Biomedica, Genoa, Italy] (0.2T)	Image quality (contrast-to-noise and signal-to-noise ratios) and the presence of synovitis were compared between E-MRI using a single versus a double dose of contrast-enhancing material.	Hand; wrist	Image quality parameters and synovitis scoring (OMERACT RAMRIS score)
Crues, 2004[20] (USA) [15088291]	132 of whom 125 were successfully imaged	Inflammatory arthritis (95% had RA and 5% had joint symptoms in the setting of psoriasis)	Single academic center	MagneVu MV1000 [MagneVu, Carlsbad, CA] (0.2T)	Plain radiographs	Hand; wrist	Erosions detected by each imaging modality and intra- and inter-rater agreement (two raters reviewed all scans)

Author, year (Country) [PMID] Study Design	N enrolled	Patient population	Setting	E-MRI [Manufacture] (Field strength)	Comparison	MR Imaging location	Outcome (assessment)
Drapé, 1998[21] (France) [9646792] Cross-sectional	43	Knee osteoarthritis	Single center	Artoscan [Esaote Biomedica, Genoa, Italy] (0.2T)	Arthroscopic evaluation	Knee	French Society of Arthroscopy scores and grades (qualitative and quantitative assessment by a single arthroscopist blind to the patient's identity and MRI findings; MRI assessment based on qualitative and quantitative assessment by two radiologists blind to the patient's identity and arthroscopic findings)
Knee, shoulder, elbow, foot, ankle pathology							
Pessis, 2003[22] (France) [12744942] Prospective, longitudinal study	20	Symptomatic tibiofemoral osteoarthritis with indication for arthroscopic joint lavage	Single academic center	Artoscan [Esaote Biomedica, Genoa, Italy] (0.2T)	Plain radiographs (weight-bearing fully extended and flexed knee) Arthroscopy performed immediately after the E-MRI All tests were repeated 1 year after the base-line examination.	Knee	For arthroscopy severity of cartilage breakdown, chondropathy. For E-MRI: articular cartilage lesions, bone marrow edema, subchondral bone abnormalities. (all tests were interpreted by a investigators unaware of the patient identity and the chronology of the investigations)

Author, year (Country) [PMID] Study Design	N enrolled	Patient population	Setting	E-MRI [Manufacture] (Field strength)	Comparison	MR Imaging location	Outcome (assessment)
Zlatkin, 2004[23] (USA) [15112313] Cross-sectional	160	Suspected shoulder pathology	5 MRI facilities located within orthopedic practices	Artoscan [Esaote Biomedica, Genoa, Italy and GE Medical Systems/Lunar Corporation, Madison, WI] (0.2T)	Operative findings, ascertained from operative reports. The operative findings were considered as the reference test.	Shoulder	Diagnostic accuracy for rotator cuff disease or glenoid labrum lesions (two radiologists reviewed MRI images independently; MRI imaging reports were available to the surgeons at the time of surgery)
Pfahler, 1998[24] (Germany) [9932184] Cross-sectional[g]	34	Lateral epicondylitis of the elbow resistant to treatment of at least 3 months	Single academic center	Dedicated system specially constructed for examination of the peripheral joints (0.2T)	Results from plain radiographs are presented (with no statistical comparison). Histopathological analysis of the extensor tendon was performed for 6 patients that underwent surgery.	Elbow	Diagnostic accuracy (number of positive MRI findings among symptomatic patients), comparison of findings in surgery (pathological examination of specimens obtained from 6 patients that underwent surgery)
Riel, 1999[25] (Germany) [10024961] Cross-sectional	244	Patients with internal knee joint lesions	Single academic center	Artoscan [Esaote Biomedica, Genoa, Italy] (0.2T)	Arthroscopy performed within “about” 48 hours of MRI.	Knee	Diagnostic accuracy (MRI scans were read by assessors blind to the orthopedic diagnosis and graded according to Reicher’s classification. Arthroscopy was performed by a single surgeon)
Steinborn, 1999[26] (Germany) [10460377]	23	Lateral epicondylitis of the elbow	Single academic center	Artoscan [Esaote Biomedica, Genoa, Italy] (0.2T)	Comparison of radiologist-assigned grades obtained with different imaging sequences. For 11 of	Elbow	Grading of imaging findings in all patient groups using different imaging sequences.

Author, year (Country) [PMID] Study Design	N enrolled	Patient population	Setting	E-MRI [Manufacture] (Field strength)	Comparison	MR Imaging location	Outcome (assessment)
Case-control	7	Healthy volunteers			the 23 patients findings in the contralateral, unaffected elbow were compared with the affected one. 5 patients underwent surgery within 6 weeks of the MRI examination and biopsy of the common extensor tendon was obtained. Intraoperative and histopathological findings were compared with MRI findings. Grading of MRI images using the same system as for patients w		(two radiologists employed a common grading system)
Verhoek, 1998[27] (Switzerland) [9626891] Cross-sectional	41[h]	Consecutive patients referred for foot or ankle MRI	NR	Artoscan [Esaote Biomedica, Genoa, Italy] (0.2T)	High-field MRI-Impact [Siemens, Erlangen, Germany] (1.0T)	Foot; ankle	Image quality (qualitative and quantitative comparison of images obtained with the two devices in a blind manner) Patient preferences were assessed by questionnaire administered after both scans were completed.
Masciocchi, 1997[28] (Italy) [9481587]	58	"Painful syndrome" at the peritalar region	NR	"dedicated" system consisting of 0.2T and 0.5T equipment	Arthroscopy was performed in 22 cases and 36 patients were assigned to clinical follow-up.[i]	Ankle	Assignment of patients to diagnostic groups based on lesion site (visual assessment for E-MRI, surgical/arthroscopy findings or clinical follow-up findings).

Author, year (Country) [PMID] Study Design	N enrolled	Patient population	Setting	E-MRI [Manufacture] (Field strength)	Comparison	MR Imaging location	Outcome (assessment)
Franklin, 1997[29] (USA) [9167821] Cross-sectional	35	Acute or chronic knee pain that requiring arthroscopic evaluation	Single clinical practice	Artoscan [Lunar Corp., Madison, WI] (0.2T)	Arthroscopic evaluation	Knee	Diagnostic accuracy (EX MRI readings were considered as the index test and arthroscopic findings as the reference standard, assessors of each test were blind to the results of the other)
Kersting-Sommerhoff, 1996[30] (Germany) [8798043] Cross-sectional	230	Acute and chronic lesions of the knee	Radiology department in a single academic center	Artoscan [Esaote Biomedica, Genoa, Italy] (0.18T)	Arthroscopic evaluation (for all patients) and high-field strength MRI (for 20[i] patients)-ACS II [Philips, Eindhoven] (1.5T)	Knee	Diagnostic accuracy of EX-MRI compared to arthroscopic findings; image quality compared to high-field strength MRI; inter-rater agreement (3 raters) assessed in 20 patients (diagnostic accuracy was assessed at the lesion level and image quality was graded as “excellent”, ”good”, “satisfactory”, or “non-diagnostic”)
Fracture or other acute injury							

Author, year (Country) [PMID] Study Design	N enrolled	Patient population	Setting	E-MRI [Manufacture] (Field strength)	Comparison	MR Imaging location	Outcome (assessment)
Bretlau, 1999[31] (Denmark) [10622486] Prospective longitudinal study	52 of whom 47 where successfully imaged	Trauma patients with suspected scaphoid fracture.	NR	Artoscan [Esaote Biomedica, Genoa, Italy] (0.1T)	Plain radiographs (normal at the initial examination) were compared to E-MRI images (obtained within an average of 4 days after trauma). E-MRI scans were also obtained at an average of 11 days post trauma. Late plain radiographs (average 11 weeks after trauma) were used as the reference test. Late E-MRI scans were also performed.	Wrist	Presence of a scaphoid fracture (blind assessment by two radiologists in random order)
Raby, 2001[32] (UK) [11286584] Cross-sectional[k]	53	Patients at least 10 days post-injury with suspected scaphoid fracture	Review and fracture clinics of a single center	Artoscan [Esaote Biomedica, Genoa, Italy] (0.2T)	Management decisions based on radiological findings and clinical examination.	Wrist	Impact on treatment decisions (clinicians were asked to determine their treatment plan on the basis of clinical and radiological findings, before MRI had been obtain and they were also asked to revise the treatment plan after the MRI results were available) A rudimentary cost analysis is presented in the discussion section of the manuscript.
	56	Patients with acute wrist injury and suspected scaphoid fracture attending the Accident and Emergency Department for the first time, usually at the day of injury	Accident and Emergency Department of a single center				

Author, year (Country) [PMID] Study Design	N enrolled	Patient population	Setting	E-MRI [Manufacture] (Field strength)	Comparison	MR Imaging location	Outcome (assessment)
Nikken, 2005[33] (Netherlands) [16118171] RCT	500 [1:1 randomization]	Acute injury of the wrist, knee or ankle	Single university hospital	Plain radiographs followed by E-MRI with Artoscan [Esaote Biomedica, Genoa, Italy] (0.2T)	Plain radiographs only.	Wrist; knee; ankle	Effectiveness (quality of life, time-to-completion of the diagnostic work-up, number of additional diagnostic procedures during follow-up, number of days absent from work, number of days to convalescence) and costs (measures of medical and non-medical costs associated with the initial injury during the 6-month follow-up period, societal perspective).
Niken, 2005[34] (Netherlands) [15618379] Retrospective analysis of RCT data to develop predictive[l] models	90 of whom 87 were randomized	Acute injury of the wrist	Single university hospital	Plain radiographs followed by E-MRI with Artoscan [Esaote Biomedica, Genoa, Italy] (0.2T)	Plain radiographs only.	Wrist	Additional treatment after initial presentation (the outcome was assessed at follow-up visits and clinical or imaging findings were assessed as potential predictors in multivariable models).
Oei, 2005[35] (Netherlands) [15618380] [m]	189	Acute injury of the knee	Single university hospital	Plain radiographs followed by E-MRI with Artoscan [Esaote Biomedica, Genoa, Italy] (0.2T)	Plain radiographs only.	Knee	Additional treatment after initial presentation (the outcome was assessed at follow-up visits and clinical or imaging findings were assessed as potential predictors in multivariable models).

Author, year (Country) [PMID] Study Design	N enrolled	Patient population	Setting	E-MRI [Manufacture] (Field strength)	Comparison	MR Imaging location	Outcome (assessment)
Kühne, 1998[36] (Germany) [9474630] Cross-sectional[n]	28	ACL reconstruction within 3 to 5 years	Academic hospitals	Artoscan [Esaote Biomedica, Italy] (0.2T)	Correlation of imaging (MRI) and clinical (knee stability) outcomes in patients treated with two different methods of ACL reconstruction	Knee	MRI and clinical scores for knee stability (Clinical measurements using the KT-1000 arthrometer; MRI scores based on visual assessment)

ACL, anterior cruciate ligament; CT, computerized tomography; EULAR, European League Against Rheumatism; MCP, metacarpophalangeal; MOST, Multicenter Osteoarthritis Study; MRI, magnetic resonance imaging; NR, not reported; OMERACT, Outcomes of Rheumatoid Arthritis Clinical Trials; P, interphalangeal, RA, rheumatoid arthritis; RAMRIS, Rheumatoid Arthritis MRI Scoring System; RCT, randomized controlled trial.

[b] The study recruited 20 patients of whom 5 where excluded because of "lack of display of the ACL on parts of the image series". Of the 15 patients analyzed, 5 where imaged with a 1.T superconducting magnet and where no included in our analyses.
[c] Three hundred and sixty patients were screened, 302 met the inclusion criteria and the first 300 were selected for the study.
[d] The authors used the protocol described in Roemer, 2005.
[e] It is not clear whether participant recruitment was prospective or retrospective.
[f] Twenty five patients were enrolled but one patient did not complete the required follow-up period of 1 year (withdrew due to "personal reasons").
[g] Baseline data were reported on all 34 patients. During follow-up, six patients underwent surgery because they remained refractory to conservative treatment.
[h] A total of 47 patients were asked to participate and 6 refused or were unable.
[i] Thirty one patients had undergone conventional radiography and 18 had undergone CT. No results from these investigations were reported.
[j] The study reported that comparative EX-MRI and high-field strength MRI examinations were done in "more than 50 patients", 20 of whom were recruited in a "prospectively". Data were reported only regarding the later group.
[k] The main analyses in the study were based on changes in the management plan (comparison of the treatment plan before and after imaging results were reported to the clinician) engendered by MRI. There was an attempt to follow-up patients but the response rate was too low and the effort was abandoned.
[l] This is a secondary analysis of data from the Nikken, 2005 RCT, listed on the above row.
[m] This is a secondary analysis of data from the Nikken, 2005 RCT, listed two rows above.
[n] A single MRI examination was performed at a mean follow-up time of 46 months following surgery. Only data at the follow-up visit are analyzed in the manuscript.

Reference List

(1) Xie X, Webber CE, Adachi JD et al. Quantitative, small bore, 1 Tesla, magnetic resonance imaging of the hands of patients with rheumatoid arthritis. *Clinical & Experimental Rheumatology.* 2008;26:860-865.

(2) Savnik A, Malmskov H, Thomsen HS et al. MRI of the arthritic small joints: comparison of extremity MRI (0.2 T) vs high-field MRI (1.5 T). *European Radiology.* 2001;11:1030-1038.

(3) Yoshioka H, Ito S, Handa S et al. Low-field compact magnetic resonance imaging system for the hand and wrist in rheumatoid arthritis. *Journal of Magnetic Resonance Imaging.* 2006;23:370-376.

(4) Jagodzinski M, Richter GM, Passler HH. Biomechanical analysis of knee hyperextension and of the impingement of the anterior cruciate ligament: a cinematographic MRI study with impact on tibial tunnel positioning in anterior cruciate ligament reconstruction. *Knee Surgery, Sports Traumatology, Arthroscopy.* 2000;8:11-19.

(5) Duer-Jensen A, Vestergaard A, Dohn UM et al. Detection of rheumatoid arthritis bone erosions by two different dedicated extremity MRI units and conventional radiography. *Annals of the Rheumatic Diseases.* 2008;67:998-1003.

(6) Cimmino MA, Innocenti S, Livrone F, Magnaguagno F, Silvestri E, Garlaschi G. Dynamic gadolinium-enhanced magnetic resonance imaging of the wrist in patients with rheumatoid arthritis can discriminate active from inactive disease. *Arthritis & Rheumatism.* 2003;48:1207-1213.

(7) Cimmino MA, Parodi M, Innocenti S et al. Dynamic magnetic resonance of the wrist in psoriatic arthritis reveals imaging patterns similar to those of rheumatoid arthritis. *Arthritis Research & Therapy.* 2005;7:R725-R731.

(8) Duer-Jensen A, Ejbjerg B, brecht-Beste E et al. Does low-field dedicated extremity MRI (E-MRI) reliably detect bone erosions in rheumatoid arthritis? A comparison of two different E-MRI units and conventional radiography with high-resolution CT scanning. *Annals of the Rheumatic Diseases.* 2009;68:1296-1302.

(9) Ejbjerg BJ, Narvestad E, Jacobsen S, Thomsen HS, Ostergaard M. Optimised, low cost, low field dedicated extremity MRI is highly specific and sensitive for synovitis and bone erosions in rheumatoid arthritis wrist and finger joints: comparison with conventional high field MRI and radiography. *Annals of the Rheumatic Diseases.* 2005;64:1280-1287.

(10) Freeston JE, Conaghan PG, Dass S et al. Does extremity-MRI improve erosion detection in severely damaged joints? A study of long-standing rheumatoid arthritis using three imaging modalities. *Annals of the Rheumatic Diseases.* 2007;66:1538-1540.

(11) Gaylis NB, Needell SD, Rudensky D. Comparison of in-office magnetic resonance imaging versus conventional radiography in detecting changes in erosions after one year of infliximab therapy in patients with rheumatoid arthritis. *Modern Rheumatology.* 2007;17:273-278.

(12) Tajiri Y, Nakamura K, Matsushita T, Ohe T, Okazaki H, Nagano A. A positioning device to allow rotation for cine-MRI of the distal radioulnar joint. *Clinical Radiology.* 1999;54:402-405.

(13) Roemer FW, Guermazi A, Lynch JA et al. Short tau inversion recovery and proton density-weighted fat suppressed sequences for the evaluation of osteoarthritis of the knee with a 1.0 T dedicated extremity MRI: development of a time-efficient sequence protocol. *European Radiology.* 2005;15:978-987.

(14) Schiff MH, Hobbs KF, Gensler T, Keenan GF. A retrospective analysis of low-field strength magnetic resonance imaging and the management of patients with rheumatoid arthritis. *Current Medical Research & Opinion.* 2007;23:961-968.

(15) Segal NA, Anderson DD, Iyer KS et al. Baseline articular contact stress levels predict incident symptomatic knee osteoarthritis development in the MOST cohort. *Journal of Orthopaedic Research.* 2009;27:1562-1568.

(16) Taouli B, Zaim S, Peterfy CG et al. Rheumatoid arthritis of the hand and wrist: comparison of three imaging techniques. *AJR.* 2004;American:937-943.

(17) Lindegaard H, Vallo J, Horslev-Petersen K, Junker P, Ostergaard M. Low field dedicated magnetic resonance imaging in untreated rheumatoid arthritis of recent onset. *Annals of the Rheumatic Diseases.* 2001;60:770-776.

(18) Lindegaard HM, Vallo J, Horslev-Petersen K, Junker P, Ostergaard M. Low-cost, low-field dedicated extremity magnetic resonance imaging in early rheumatoid arthritis: a 1-year follow-up study. *Annals of the Rheumatic Diseases.* 2006;65:1208-1212.

(19) Eshed I, Althoff CE, Schink T et al. Low-field MRI for assessing synovitis in patients with rheumatoid arthritis. Impact of Gd-DTPA dose on synovitis scoring. *Scandinavian Journal of Rheumatology.* 2006;35:277-282.

(20) Crues JV, Shellock FG, Dardashti S, James TW, Troum OM. Identification of wrist and metacarpophalangeal joint erosions using a portable magnetic resonance imaging system compared to conventional radiographs. *The Journal of Rheumatology.* 2004;31:676-685.

(21) Drape JL, Pessis E, Auleley GR, Chevrot A, Dougados M, Ayral X. Quantitative MR imaging evaluation of chondropathy in osteoarthritic knees. *Radiology.* 1998;208:49-55.

(22) Pessis E, Drape JL, Ravaud P, Chevrot A, Dougados M, Ayral X. Assessment of progression in knee osteoarthritis: results of a 1 year study comparing arthroscopy and MRI. *Osteoarthritis & Cartilage.* 2003;11:361-369.

(23) Zlatkin MB, Hoffman C, Shellock FG. Assessment of the rotator cuff and glenoid labrum using an extremity MR system: MR results compared to surgical findings from a multi-center study. *Journal of Magnetic Resonance Imaging.* 2004;19:623-631.

(24) Pfahler M, Jessel C, Steinborn M, Refior HJ. Magnetic resonance imaging in lateral epicondylitis of the elbow. *Archives of Orthopaedic & Trauma Surgery.* 1998;118:121-125.

(25) Riel KA, Reinisch M, Kersting-Sommerhoff B, Hof N, Merl T. 0.2-Tesla magnetic resonance imaging of internal lesions of the knee joint: a prospective arthroscopically controlled clinical study. *Knee Surgery, Sports Traumatology, Arthroscopy.* 1999;7:37-41.

(26) Steinborn M, Heuck A, Jessel C, Bonel H, Reiser M. Magnetic resonance imaging of lateral epicondylitis of the elbow with a 0.2-T dedicated system. *European Radiology.* 1999;9:1376-1380.

(27) Verhoek G, Zanetti M, Duewell S, Zollinger H, Hodler J. MRI of the foot and ankle: diagnostic performance and patient acceptance of a dedicated low field MR scanner. *Journal of Magnetic Resonance Imaging.* 1998;8:711-716.

(28) Masciocchi C, Maffey MV, Mastri F. Overload syndromes of the peritalar region. *European Journal of Radiology.* 1997;26:46-53.

(29) Franklin PD, Lemon RA, Barden HS. Accuracy of imaging the menisci on an in-office, dedicated, magnetic resonance imaging extremity system. *American Journal of Sports Medicine.* 1997;25:382-388.

(30) Kersting-Sommerhoff B, Hof N, Lenz M, Gerhardt P. MRI of peripheral joints with a low-field dedicated system: a reliable and cost-effective alternative to high-field units? *European Radiology.* 1996;6:561-565.

(31) Bretlau T, Christensen OM, Edstrom P, Thomsen HS, Lausten GS. Diagnosis of scaphoid fracture and dedicated extremity MRI. *Acta Orthopaedica Scandinavica.* 1999;70:504-508.

(32) Raby N. Magnetic resonance imaging of suspected scaphoid fractures using a low field dedicated extremity MR system. *Clinical Radiology.* 2001;56:316-320.

(33) Nikken JJ, Oei EH, Ginai AZ et al. Acute peripheral joint injury: cost and effectiveness of low-field-strength MR imaging--results of randomized controlled trial. *Radiology.* 2005;236:958-967.

(34) Nikken JJ, Oei EH, Ginai AZ et al. Acute wrist trauma: value of a short dedicated extremity MR imaging examination in prediction of need for treatment. *Radiology.* 2005;234:116-124.

(35) Oei EH, Nikken JJ, Ginai AZ et al. Acute knee trauma: value of a short dedicated extremity MR imaging examination for prediction of subsequent treatment. *Radiology.* 2005;234:125-133.

(36) Kuhne JH, Durr HR, Steinborn M, Jansson V, Refior HJ. Magnetic resonance imaging and knee stability following ACL reconstruction. *Orthopedics.* 1998;21:39-43.

Appendix F. Comparative studies of two diagnostic tests

Author, year [UI] Country Center Enrollment year	N enrolled Inclusion criteria Sampling	Mean age [SD /range], yr (% male)	Weight-bearing MRI • Device description • Model (manufacturers) • Field strength • Coil • Loading • Positioning • Configuration	Comparator test	Outcomes	Main findings	Funding Comments
Lumbar spine imaging with open, positional MRI							
Vitzthum 2000[1] [10879759] Germany nd nd	50 (patients); 50 (healthy controls) Cases: Lumbar disc herniation (82%), lateral osteogenic recess stenosis (10%); degenerative spondylolithesis (8%) Controls: healthy volunteers Sampling not described.	Patients: 53 [34 to 71] (60) Controls: 24.5 [3.4] (56)	Open, interventional MRI • Open MRI • Signa SP (GE) • 0.5 T • nd • Sitting • Neutral, extension, flexion, rotation (dynamic) • Vertically open	Prior MRI finding: decompression of the lumbar nerve roots, which correlated with clinical symptoms	• Impact on diagnostic thinking • Functional patterns based on dynamic exam of flexion-extension, compared to results obtained in healthy controls	• In 32 (64%) patients dynamic exam of flexion-extension contributed important additional information to the preliminary diagnosis. • Patients had characteristics of a Type I functional pattern.	Non-industry How controls were selected were not described
Weishaupt, 2000[2] [10751495] Switzerland Single nd	36 (30 analyzed) Recruited after MRI of lumbar spine. Low back pain or leg pain for >6 weeks, unresponsiveness to a trial of nonsurgical treatment, surgery not indicated or not urgent on the basis of clinical findings. Sampling not described.	38 [20 to 50] (57)	Open, interventional MRI • Positional MRI • Signa Advanced SP (GE) • 0.5 T • Flexible transmit-receive wraparound surface coil • Sitting • Extension, flexion (static) • Vertically open	cMRI • cMRI • Impact Expert (Seimen) • 1.0 T • Dedicated receive-only spinal coil • None • Supine neutral • Closed	• Diagnosis of disk abnormalities • Impact on diagnostic thinking • Pain assessment: a visual analogue scale was used for assessing pain intensity	• Diagnoses in supine position (cMRI) changed in 4 disks (5%) in seated flexion, and in 7 disks (9%) in seated extension. • Positional pain differences are related to position-dependent changes in foraminal size.	nd

Author, year [UI] Country Center Enrollment year	N enrolled Inclusion criteria Sampling	Mean age [SD /range], yr (% male)	Weight-bearing MRI • Device description • Model (manufacturers) • Field strength • Coil • Loading • Positioning • Configuration	Comparator test	Outcomes	Main findings	Funding Comments
Wildermuth, 1998[3] [9577486] Switzerland Single nd	30 Patients referred for lumbar myelography and agreeing to undergo MR imaging with an open system in another institute Consecutive	58 [27 to 84] (43)	Open, interventional MRI • Open MRI • Advantage SP (GE) • 0.5 T • Transmit-receive wraparound surface coil • Sitting • Extension, flexion (static) • Vertically open	Lumbar myelography Radiographs were obtained with fluoroscopic guidance in the lateral decubitus, prone, and left and right posteroanterior oblique projections. Upright anteroposterior and lateral images were then obtained at flexion and extension.	• Patient preferences and anxiety during imaging • Correlation between MRI and myelographic measurements	• More patients reported anxiety during myelography than during MRI, and more patients preferred MRI than myelography. • Myelography and positional MRI are comparable for quantitative assessment of sagittal dural sac diameters.	Non-industry 17% patients could not be contacted for preferences and anxiety outcomes.
Zou, 2008[4] [18317181] US nd 2005 to 2006	533 Patients with symptomatic back pain with/without radiculopathy Selection criteria and sampling were not described.	46.2 [18 to 76] (42)	Kinetic, upright MRI in extension or flexion position • Upright multiposition MRI • Upright (Fonar) • 0.6 T • Quad channel planar coil • Standing • Extension, flexion (static) • Vertically open	Kinetic, upright MRI in neutral position • Upright multiposition MRI • Upright (Fonar) • 0.6 T • Quad channel planar coil • Standing • Neutral • Vertically open	Missed diagnosis of lumbar disc herniations, comparing flexion or extension to neutral postion: the extent of lumbar disc bulges in neutral, flexed, and extended views were graded by 2 spine surgeons independently without knowing the patients' history and clinical findings.	19.4%, 13.3% 10.6%, and 9.1% missed diagnosis of a disc herniation in patients with grade 1 (0-3 mm), grade 2 (3-5 mm), grade 3 (5-7 mm), and grade 4 (7-9 mm) of lumbar disc bulges, respectively.	Non-industry Missed diagnosis rates were calculated based on the number of lumbar discs
Lumbar spine imaging with axial-loading MRI							

Author, year [UI] Country Center Enrollment year	N enrolled Inclusion criteria Sampling	Mean age [SD /range], yr (% male)	Weight-bearing MRI • Device description • Model (manufacturers) • Field strength • Coil • Loading • Positioning • Configuration	Comparator test	Outcomes	Main findings	Funding Comments
Danielson, 1998[5] [9817029] Sweden Single 1994 to 1996	34 Clinically suspected lumbar spinal canal narrowing which resulted in sciatica and/or neurogenic claudication Sampling was not described.	50 [25 to 71] (53)	cMRI with axial loading • cMRI with axial loading • Magnetom Impact (Siemens) • 1.0 T • Surface coil • Custom-made axial loading compression device[a] (300-400 Newtons or ~50% BW) • Axial loading of the lumbar spine in extension • Closed	Preloaded cMRI exam • cMRI (before axial loading) • Magnetom Impact (Siemens) • 1.0 T • Surface coil • None • PRP • Closed	• Diagnosis of recess and foraminal stenosis: a reduction in the space available to the nerve roots (recess <3 mm) in combination with loss of epidural fat • Pain during axial loading	• 7 patients (21%) had low back pain and 10 (29%) had leg pain in axial loading of the lumbar spine in extension (ACE) • 1 recess stenosis was found in 12 patients and a foraminal stenosis was seen in 1 patients. • 5 of the patients with leg pain in ACE had a disc herniation and 6 had a recess stenosis.	Industry Post-hoc exclusion of patients from most of the analyses Based on the enrollment years and data presented in the table, patients were overlapped with Willen, 1997 and Willen, 2001
Hiwatashi, 2004[6] [14970014] Sweden Single nd	20 Patients with signs and symptoms of spinal stenosis; with detected appreciable difference in the caliber of the dural sac on the routine and the axially loaded MRI. Sampling was not described.	54 [32 to 75] (70)	cMRI with axial loading • cMRI with axial loading • nd • 1.0 T • Surface coil • DynaWell L-Spine: 50% BW • Axial loading of the lumbar spine in extension • Closed	Preloaded cMRI exam • cMRI (before axial loading) • nd • 1.0 T • Surface coil • None • PRP • Closed	• Additional information gained from the axially loaded images • Changes in treatment decisions based on preloaded cMRI, axial loading MRI, and patients' clinical history: decisions were made by 3 experienced neurosurgeons (who are also the coauthors of this paper)	Additional information gained from axial loading during MRI of the lumbar portion of the spine changed neurosurgeons' treatment decision from conservative management to decompressive surgery for 5 (25%) patients.	nd Retrospective secondary database analyses. Selection of patients based on the MRI findings. Danielson was the 2nd author.

Author, year [UI] Country Center Enrollment year	N enrolled Inclusion criteria Sampling	Mean age [SD /range], yr (% male)	Weight-bearing MRI • Device description • Model (manufacturers) • Field strength • Coil • Loading • Positioning • Configuration	Comparator test	Outcomes	Main findings	Funding Comments
Huang, 2009[7] [19526378] Taiwan nd nd	32 (29 analyzed) Patients with diagnoses of degenerative L4-L5 spondylolisthesis, grade 1 or 2 slippage. Patients with degenerative scoliosis were excluded. Consecutive	nd (19)	cMRI with axial loading • cMRI with axial loading • Signa Cvi (Siemens) • 1.5 T • Phase array spinal coil • DynaWell: 50% BW • Supine in extension • Closed	Preloaded cMRI exam • Preloaded MRI exam • Signa Cvi (Siemens) • 1.5 T • Phase array spinal coil • None • Supine • Closed	• Disability: Oswestry Diability Index (ODI) • Physical functioning: Physical Function (PF) scale	After adjustment for sex and age, significant associations were found between ODI, PF and the difference of segmental angulation, and the PF and the post-loaded lumbar lordotic angles (p=0.02)	Non-industry Patients were excluded from the study after axial loading due to intolerable back pain, numbness or sciatica
Manenti, 2003[8] [14598603] Italy nd nd	50 (patients); 43 (healthy controls) Patients with a history of chronic lumbar pain and recurrent movement-induced painful blockages. Healthy controls were selected by matching weight, age, sex and job	Patients: 46 [19] (56) Controls: matching age and sex	cMRI with axial loading • Axial loading MRI • Gyroscan Intera (Phillips) • 1.5 T • Flexible surface coil • Axial compressor (MIKAI manufacturing, Genoa, Italy): 65% BW • Supine in extension • Closed	Preloaded cMRI exam • Neutral unloaded routine MRI • Gyroscan Intera (Phillips) • 1.5 T • Flexible surface coil • None • PRP • Closed	Diagnosis of discal degeneration or protrusion: 3 radiologists evaluated the mages through the compilation of an apposite questionnaire on the modifications occurring from the neutral to the loaded acquisitions.	Relative to the control group, 43 patients were studied for a total of 129 discal levels. 31 presented discal degeneration at 56 (43%) of the studied discal levels. Diagnosis of discal protrusion was made at 19 discal levels in 12 patients.	Non-industry

Author, year [UI] Country Center Enrollment year	N enrolled Inclusion criteria Sampling	Mean age [SD /range], yr (% male)	Weight-bearing MRI • Device description • Model (manufacturers) • Field strength • Coil • Loading • Positioning • Configuration	Comparator test	Outcomes	Main findings	Funding Comments
Willen, 1997[9] [9431634] Sweden Single 1994 to 1995	34 (80 sites) Patients selection criteria were not described. Sampling was not described.	53 [25 to 74] (53)	cMRI with axial loading • cMRI with axial loading • Magnetom Impact (Siemens) • 1.0 T • Surface coil • Custom-made axial loading harness[a] (~50% BW) • Axial loading of the lumbar spine in extension • Closed	Preloaded cMRI exam • cMRI (before axial loading) • Magnetom Impact (Siemens) • 1.0 T • Surface coil • None • PRP • Closed	Diagnosis of disc abnormalities (e.g.,disc herniation, lateral recess or formaminal stenosis, or a intraspinal synovial cyst at PRP changing to obvious manifestation at ACE)	• In 11 patients (16 sites), stenosis was found in one or two sites. • Narrowing of the lateral recess was noted in 13 sites.	nd Post-hoc exclusion of patients from most of the analyses Based on the enrollment years and data presented in the table, patients were overlapped with subsequent publications.
Willen, 2001[10] [11725243] Sweden Single 1994 to 1998	122 Patients were selected according to their symptoms (low back pain, sciatica, or neurogenic claudication). Sampling was not described.	50 [14 to 80] (52)	cMRI with axial loading • cMRI with axial loading • Magnetom Impact (Siemens) • 1.0 T • Surface coil • DynaWell L-Spine: 40% BW (never >50% BW) • Axial loading of the lumbar spine in extension • Closed	Preloaded cMRI exam Protocol same as Willen, 1997	Impact on diagnostic thinking: AVI was defined as 1) a sig. reduction of the DCSA (>15 mm^2) to areas <75 mm^2 (borderline value for canal stenosis) from PRP to ACE, or 2) a suspected disc herniation, lateral recess or formaminal stenosis, or a intraspinal synovial cyst at PRP changing to obvious manifestation at ACE	• AVI was found by the axially loaded MRI in 30% patients overall (in patients with sciatica or neurogenic claudication only). • No AVI was found in patients with low back pain.	Industry Post-hoc exclusion of patients from most of the analyses Based on the enrollment years and data presented in the table, patients were overlapped with the prior publication.

Author, year [UI] Country Center Enrollment year	N enrolled Inclusion criteria Sampling	Mean age [SD /range], yr (% male)	Weight-bearing MRI • Device description • Model (manufacturers) • Field strength • Coil • Loading • Positioning • Configuration	Comparator test	Outcomes	Main findings	Funding Comments
Willen, 2008[11] [18277859] Sweden Single 1996 to 2002	250 Patients with clinical signs of neurogenic claudication and/or sciatica. Sampling was not described.	nd	cMRI with axial loading • cMRI with axial loading • nd • 1.0 T • Surface coil • DynaWell L-Spine: 40% BW (never >50% BW) • Axial loading of the lumbar supine in extension • Closed	Preloaded cMRI exam Protocol same as Willen, 1997 and Willen, 2001	• Impact on diagnostic thinking: AVI (same definition as Willen, 2001) • Patient outcomes after surgery	• In 24 patients, a hidden stenosis was disclosed in 1 to 3 disc levels, whereas no stenosis was detected at the unloaded exam. • At 1-6 year after surgery, majority of the 24 patients had much improved or improved leg or back pain, and subjective walking ability.	Industry Probably some overlaps with Willen, 2001 Outcome data were from the Swedish Spine Register 2005. Based on the enrollment years and data presented in the table, patients were overlapped with the prior publications
Knee joints imaging							

Author, year [UI] Country Center Enrollment year	N enrolled Inclusion criteria Sampling	Mean age [SD /range], yr (% male)	Weight-bearing MRI • Device description • Model (manufacturers) • Field strength • Coil • Loading • Positioning • Configuration	Comparator test	Outcomes	Main findings	Funding Comments
Boxheimer 2006[12] [16373770] Switzerland Single 2002 to 2003	42 Patients suspected of having a meniscal tear; diagnosis of meniscal tears based on cMRI and confirmed by arthroscopy. Sampling was not described.	37 [18 to 60] (71)	Open, interventional MRI • kinematic MRI • Signa SP (GE) • 0.5 T • Flexible transmit-receive surface coil • Standing (allowing arms on a support frame) • Upright Vertically open	Supine position in open, interventional MRI • kinematic MRI • Signa SP (GE) • 0.5 T • Flexible transmit-receive surface coil • None • Supine, or supine 90° flexion with rotation Vertically open	• Diagnosis of meniscal displacement: a meniscal movement of 3 mm or more between weight-bearing and supine positions. Assessment of pain intensity: a visual analog scale was used.	• 58% menisci with tears did not reveal any displacement between the different knee positions. • Patients with displaceable meniscal tears reported significantly more pain in all three knee positions than did patients with nondisplaceable meniscal tear (P<0.05)	nd

Author, year [UI] Country Center Enrollment year	N enrolled Inclusion criteria Sampling	Mean age [SD /range], yr (% male)	Weight-bearing MRI • Device description • Model (manufacturers) • Field strength • Coil • Loading • Positioning • Configuration	Comparator test	Outcomes	Main findings	Funding Comments
Shellock, 1993[13] [8327718] US Single nd	17 (patients); 5 (healthy controls) how controls were selected were not described	Patients: 31 [17 to 48] (39) Controls: nd	cMRI with kinetic resistance loading • 64 MHz MR imager • nd • 1.5 T • Transmit-and-receive quadrature body coil • Nonferromagnetic positioning device with a force of 30 ft-lb/sec (resistance) • Prone position with joints movement from ~45º to extension • Closed	cMRI without loading • 64 MHz MR imager • nd • 1.5 T • Transmit-and-receive quadrature body coil • Nonferromagnetic positioning device without load • Prone position with joints movement from ~45º to extension • Closed	Missed diagnosis of patellofemoral joint abnormalities in alignment and tracking (diagnosis was made by two radiologists in blinded fashion)	• In symptomatic patients, the unloaded kinematic MRI showed 41% normal findings, while loaded kinematic MRI showed 5.9% normal findings. • The severity of abnormalities was qualitatively the same with both techniques (9 cases) or greater with the loaded technique (7 cases)	Industry
Sutera, 2010[14] [20177977] Italy Single 2009	20 (patients); 20 (healthy controls) Two groups of individuals underwent MRI with a dedicated system were included. Convenience sample	Patients: 36 [24 to 45] (80) Controls: 33 [20 to 41] (70)	Tilting MRI in upright position • Dedicated upright MRI • G scan (Esaote) • 0.25 T • Dedicated platform-shaped receiver coil • Standing (~82º) • Neutral • Laterally open	Tilting MRI in supine position • Dedicated upright MRI • G scan (Esaote) • 0.25 T • Dedicated platform-shaped receiver coil • Conventional supine • Neutral • Laterally open	Clinical diagnosis of plantar fasciitis: presence of perifascial oedema or both of fascia thickening and abnormal signal intensity (consensus by 3 radiologists blinded to patients' groups, history and clinical findings)	• Both supine and upright positions enabled identification of plantar fasciitis in 15/20 cases (75%) in patient group. • None of controls had a diagnosis of plantar fasciitis or abnormal MRI findings in either upright or supine position.	Non-industry
Foot imaging							

Author, year [UI] Country Center Enrollment year	N enrolled Inclusion criteria Sampling	Mean age [SD /range], yr (% male)	Weight-bearing MRI • Device description • Model (manufacturers) • Field strength • Coil • Loading • Positioning • Configuration	Comparator test	Outcomes	Main findings	Funding Comments
Weishaupt, 2003[15] [12601213] Single 2000 to 2001	18 Patients suspected of having Morton's neuroma and underwent cMRI of their symptomatic forefoot in the prone position. Only those who had presence of >1 Morton's neuroma 5 mm or larger in its transverse diameter were included. Referred by foot surgeons or orthopedic foot surgeons	50 [25 to 72] (6)	Weight-bearing MRI • Weight-bearing MRI • Signa Advanced SP (GE) • 0.5 T • Flexible transmit-receive wraparound surface coil • Sitting • Extension, flexion (static) • Vertically open	cMRI • cMRI • Impact Expert (Seimen) • 1.0 T • Send-receive extremity coil • None • Prone position • Closed Supine MRI in open scanner • Supine MRI • Signa Advanced SP (GE) • 0.5 T • Flexible transmit-receive wraparound surface coil • None • Supine • Vertically open	Change in diagnosis of Morton's neuroma: <5 mm in transverse diameter, measurements were performed by 1 of the authors at a separate workstation using software	• No additional Morton's neuroma was found on any of the MR images. • Visibility of Morton's neuroma was significantly better in cMRI in the prone position compared with that in the supine position.	nd Only included patients with successful imaging in all three Only included patients with a Morton's neuroma in the prone position.

ACE, axial loading of the lumbar spine in extension; AVI, additional valuable information; BW, body weight; cMRI, conventional MRI; CT, computed tomography; DCSA, dural sac cross-sectional area; PRP, psoas-relaxed position; SD, standard deviation

[a] This custom-made axial loading harness later became commercialized under the brand name of DynaWell L-Spine.

Reference List

(1) Vitzthum HE, Konig A, Seifert V. Dynamic examination of the lumbar spine by using vertical, open magnetic resonance imaging. *Journal of Neurosurgery.* 2000;93:Suppl-64.

(2) Weishaupt D, Schmid MR, Zanetti M et al. Positional MR imaging of the lumbar spine: does it demonstrate nerve root compromise not visible at conventional MR imaging? *Radiology.* 2000;215:247-253.

(3) Wildermuth S, Zanetti M, Duewell S et al. Lumbar spine: quantitative and qualitative assessment of positional (upright flexion and extension) MR imaging and myelography.[Erratum appears in Radiology 1998 Sep;208(3):834]. *Radiology.* 1998;207:391-398.

(4) Zou J, Yang H, Miyazaki M et al. Missed lumbar disc herniations diagnosed with kinetic magnetic resonance imaging. *Spine.* 2008;33:E140-E144.

(5) Danielson BI, Willen J, Gaulitz A, Niklason T, Hansson TH. Axial loading of the spine during CT and MR in patients with suspected lumbar spinal stenosis. *Acta Radiologica.* 1998;39:604-611.

(6) Hiwatashi A, Danielson B, Moritani T et al. Axial loading during MR imaging can influence treatment decision for symptomatic spinal stenosis. *AJNR Am J Neuroradiol.* 2004;25:170-174.

(7) Huang KY, Lin RM, Lee YL, Li JD. Factors affecting disability and physical function in degenerative lumbar spondylolisthesis of L4-5: evaluation with axially loaded MRI. *European Spine Journal.* 2009;18:1851-1857.

(8) Manenti G, Liccardo G, Sergiacomi G et al. Axial loading MRI of the lumbar spine. *In Vivo.* 2003;17:413-420.

(9) Willen J, Danielson B, Gaulitz A, Niklason T, Schonstrom N, Hansson T. Dynamic effects on the lumbar spinal canal: axially loaded CT-myelography and MRI in patients with sciatica and/or neurogenic claudication. *Spine (Phila Pa 1976).* 1997;22:2968-2976.

(10) Willen J, Danielson B. The diagnostic effect from axial loading of the lumbar spine during computed tomography and magnetic resonance imaging in patients with degenerative disorders. *Spine.* 2001;26:2607-2614.

(11) Willen J, Wessberg PJ, Danielsson B. Surgical results in hidden lumbar spinal stenosis detected by axial loaded computed tomography and magnetic resonance imaging: an outcome study. *Spine.* 2008;33:E109-E115.

(12) Boxheimer L, Lutz AM, Zanetti M et al. Characteristics of displaceable and nondisplaceable meniscal tears at kinematic MR imaging of the knee. *Radiology.* 2006;238:221-231.

(13) Shellock FG, Mink JH, Deutsch AL, Foo TK, Sullenberger P. Patellofemoral joint: identification of abnormalities with active-movement, "unloaded" versus "loaded" kinematic MR imaging techniques. *Radiology.* 1993;188:575-578.

(14) Sutera R, Iovane A, Sorrentino F et al. Plantar fascia evaluation with a dedicated magnetic resonance scanner in weight-bearing position: our experience in patients with plantar fasciitis and in healthy volunteers. *Radiologia Medica.* 2010;115:246-260.

(15) Weishaupt D, Treiber K, Kundert HP et al. Morton neuroma: MR imaging in prone, supine, and upright weight-bearing body positions. *Radiology.* 2003;226:849-856.